ACTA·COLL·MED·PHILAD·INSTIT·A·D·MDCCLXXXVII

Digitized by the Internet Archive
in 2013

http://archive.org/details/transactionsofco3251coll

TRANSACTIONS

OF THE

COLLEGE OF PHYSICIANS

OF

PHILADELPHIA.

THIRD SERIES.

VOLUME THE TWENTY-FIFTH.



PHILADELPHIA:
PRINTED FOR THE COLLEGE.
1903.

NOTICE.

The present volume of TRANSACTIONS contains the papers read before the College from January, 1903, to December, 1903, inclusive.

The Committee of Publication thinks it proper to say that the College holds itself in no way responsible for the statements, reasonings, or opinions set forth in the various papers published in its TRANSACTIONS.

EDITED BY

WILLIAM ZENTMAYER.

DORNAN, PRINTER.

COLLEGE OF PHYSICIANS OF PHILADELPHIA.

1903.

OFFICERS AND STANDING COMMITTEES.

PRESIDENT.

HORATIO C. WOOD, M.D.

VICE-PRESIDENT.

ARTHUR V. MEIGS, M.D.

CENSORS.

RICHARD A. CLEEMANN, M.D.
HORACE Y. EVANS, M.D.
S. WEIR MITCHELL, M.D.
LOUIS STARR, M.D.

SECRETARY.

THOMAS R. NEILSON, M.D.

TREASURER.

RICHARD H. HARTE, M.D.

HONORARY LIBRARIAN.

FREDERICK P. HENRY, M.D.

COUNCILLORS.

To serve until January, 1904.

FRANCIS R. PACKARD, M.D.
ELLISTON J. MORRIS, M.D.

To serve until January, 1905.

J. CHALMERS DA COSTA, M.D.
J. P. CROZER GRIFFITH, M.D.

To serve until January, 1906.

H. R. WHARTON, M.D.
CHARLES W. BURR, M.D.

COMMITTEE OF PUBLICATION.

GWILYM G. DAVIS, M.D., *Ch'n.*
THOMPSON S. WESTCOTT, M.D.
WILLIAM ZENTMAYER, M.D.

LIBRARY COMMITTEE.

GEORGE C. HARLAN, M.D., *Ch'n.*
WILLIAM J. TAYLOR, M.D.
F. X. DERCUM, M.D.
S. WEIR MITCHELL, M.D.
CHARLES A. OLIVER, M.D.
The HONORARY LIBRARIAN, *ex-officio.*

COMMITTEE ON MÜTTER MUSEUM.

JOHN H. BRINTON, M.D., *Ch'n.*
GEORGE McCLELLAN, M.D.
J. ALISON SCOTT, M.D.

HALL COMMITTEE.

WILLIAM BARTON HOPKINS, M.D., *Ch'n.* CASPAR MORRIS, M.D.
J. K. MITCHELL, M.D. THOMAS H. FENTON, M.D.
B. ALEX. RANDALL, M.D.

COMMITTEE ON THE DIRECTORY FOR NURSES.

WHARTON SINKLER, M.D., *Ch'n.* JAMES C. WILSON, M.D.
JAMES V. INGHAM, M.D.

COMMITTEE ON FINANCE.

JOHN B. ROBERTS, M.D., *Ch'n.* GEORGE FALES BAKER, M.D.
SAMUEL G. DIXON, M.D.
The PRESIDENT and the TREASURER, *ex-officio.*

COMMITTEE ON ENTERTAINMENTS.

G. E. DE SCHWEINITZ, M.D., *Ch'n.* J. ALISON SCOTT, M.D.
CHARLES H. FRAZIER, M.D. GEORGE B. WOOD, M.D.
The PRESIDENT, *ex-officio.*

COMMITTEE ON ALVARENGA PRIZE.

SIMON FLEXNER, M.D., *Ch'n.* WM. CAMPBELL POSEY, M.D.
JOHN H. GIBBON, M.D. HENRY BEATES, JR., M.D.
J. M. BALDY, M.D.

COMMITTEE ON THE NATHAN LEWIS HATFIELD PRIZE (until Feb. 1904).

JAMES C. WILSON, M.D. JOSEPH W. WARREN, M.D.
THOMAS G. ASHTON, M.D.

TRUSTEES OF THE NATHAN LEWIS HATFIELD MEMORIAL FUND.

HERBERT NORRIS, M.D. ROBERT G. LE CONTE, M.D.
NORTON DOWNS, M.D.

SECTIONS.

OPHTHALMOLOGY—*Chairman,* S. D. RISLEY, M.D.
Clerk, WILLIAM M. SWEET, M.D.

OTOLOGY AND LARYNGOLOGY—*Chairman,* B. A. RANDALL, M.D.
Clerk, FRANCIS R. PACKARD, M.D.

GYNECOLOGY—*Chairman,* JOHN H. GIRVIN, M.D.
Clerk, W. R. NICHOLSON, M.D.

GENERAL MEDICINE—*Chairman,* ALFRED STENGEL, M.D.
Clerk, S. McC. HAMILL, M.D.

LIST

OF THE

PRESIDENTS OF THE COLLEGE FROM THE TIME OF ITS INSTITUTION.

ELECTED	
1787	JOHN REDMAN
1805	WILLIAM SHIPPEN
1809	ADAM KUHN
1818	THOMAS PARKE
1835	THOMAS C. JAMES *
1835	THOMAS T. HEWSON
1848	GEORGE B. WOOD
1879	W. S. W. RUSCHENBERGER
1883	ALFRED STILLÉ
1884	SAMUEL LEWIS †
1884	J. M. DA COSTA
1886	S. WEIR MITCHELL
1889	D. HAYES AGNEW
1892	S. WEIR MITCHELL
1895	J. M. DA COSTA
1898	JOHN ASHHURST, JR.
1900	W. W. KEEN
1902	HORATIO C. WOOD

* Died four months after his election.
† Resigned on account of ill-health.

FELLOWS

OF THE

COLLEGE OF PHYSICIANS OF PHILADELPHIA.

DECEMBER, 1903.

* Non-resident Fellows.
† Fellows who have commuted dues.

ELECTED

*1883. Abbot, Griffith E., Ph.D., M.D., Washington, D.C.

1892. Abbott, Alex. C., M.D., Professor of Hygiene and Bacteriology, and Director of the Laboratory of Hygiene in the University of Pennsylvania.

1876. Alison, Robert H., M.D., Attending Physician to the Bryn Mawr Hospital.

1903. Allen, Alfred Reginald, M.D.

1873. Allis, Oscar H., M.D., Surgeon to the Presbyterian Hospital.

1896. Allyn, Herman B., M.D., Instructor in Physical Diagnosis in the University of Pennsylvania; Physician to the Philadelphia Hospital; Clinical Professor of Medicine in the Woman's Medical College of Pennsylvania.

1888. Anders, James M., M.D., LL.D., Professor of the Theory and Practice of Medicine and Clinical Medicine in the Medico-Chirurgical College; Physician to the Medico-Chirurgical and Samaritan Hospitals.

1869. Andrews, T. Hollingsworth, M.D.

1896. Angney, William M., M.D., Physician to the House of Mercy (Home for Male Consumptives); Consulting Physician to the Hospital for Diseases of the Lungs, at Chestnut Hill.

*1882. Ashbridge, Richard, M.D., West Whiteland, Pa.

1893. Ashton, Thomas G., M.D., Physician to the Philadelphia Hospital; Assistant Physician to the Jefferson Medical College Hospital; Clinical Professor of Medicine in the Woman's Medical College of Pennsylvania.

ELECTED

1857. Atlee, Walter Franklin, A.M., M.D., Corresponding Member of La Société des Sciences Médicales de Lyons; Consulting Surgeon to St. Luke's Hospital, Bethlehem; Visiting Physician to the Preston Retreat.

1852. Bache, Thomas Hewson, M.D.

1903. Bacon, John, M.D.

1883. Baer, Benjamin F., M.D., Professor of Gynecology in the Philadelphia Polyclinic.

†1892. Baker, George Fales, B.S., M.D.

1879. Baker, Washington H., M.D., Obstetrician to the Maternity Hospital.

1889. Baldy, John Montgomery, M.D., Professor of Gynecology in the Philadelphia Polyclinic; Surgeon to the Gynecean Hospital and to the Gynecological Out-patient Department of the Pennsylvania Hospital; Consulting Surgeon to the Frederick Douglass Memorial Hospital.

1898. Balliet, Tilghman M., A.M., M.D., Professor of Therapeutics at Dartmouth College, Hanover, N. H.; Physician to the Old Man's Home.

1880. Bartholow, Roberts, M.D., Professor (Emeritus) of Materia Medica, General Therapeutics and Hygiene in the Jefferson Medical College.

1894. Barton, James M., M.D., Surgeon to the Jefferson Medical College Hospital and to the Philadelphia Hospital.

1883. Baum, Charles, A.M., M.D., Ph.D.

1883. Beates, Henry, M.D.

1860. Benner, Henry D., M.D.

1874. Bennett, W. H., M.D., Physician-in-Charge to the Seashore Home for Invalid Children, and to the Seaside House for Invalid Women, Atlantic City; formerly Physician to the Episcopal Hospital, and Physician-in-Charge to St. Christopher's Hospital for Children.

1896. Beyea, Henry D., M.D., Associate in Gynecology and Assistant Demonstrator of Obstetrics in the University of Pennsylvania; Assistant Surgeon to the Gynecean Hospital.

†1884. Biddle, Alexander W., M.D.

ELECTED

1884. Biddle, Thomas, M.D.

1903. Biggs, Montgomery H., M.D., Chief Resident Physician of the Philadelphia Hospital.

*1866. Black, J. J., M.D., New Castle, Del.

1894. Bliss, Arthur Ames, M.D., Laryngologist and Aurist to the German Hospital; Consulting Laryngologist to the Pennsylvania Institution for the Deaf and Dumb.

*1867. Boardman, Charles H., M.D.

1894. Bochroch, Max H., M.D., Demonstrator of Neurology, and Chief Clinical Assistant in the Nervous Department of the Jefferson Medical College Hospital; Neurologist to the Outpatient Department of St. Joseph's Hospital.

1896. Boger, John A., M.D., Surgeon to St. Mary's and the Samaritan Hospitals; Surgeon to the Dispensary of the Episcopal Hospital.

1891. Boyd, George M., M.D., Clinical Professor of Obstetrics in the Medico-Chirurgical College; Physician to the Philadelphia Lying-in Charity Hospital and Nurse School.

†1884. Bradford, T. Hewson, M.D.

1903. Branson, Thomas F., M.D., Attending Physician to the Bryn Mawr Hospital.

1856. Brinton, John H., M.D., LL.D., Professor of the Practice of Surgery and of Clinical Surgery in the Jefferson Medical College; Consulting Surgeon to St. Joseph's Hospital and to the Southwestern Hospital of Philadelphia.

1891. Brinton, Lewis, M.D., Visiting Physician to the Nervous Department of the Howard Hospital.

1900. Brinton, Ward, M.D., Demonstrator of Physical Diagnosis in the Jefferson Medical College; Physician to the Dispensary of St. Christopher's Hospital for Children; Assistant in the Medical Dispensary of the Jefferson Medical College Hospital.

1887. Brubaker, Albert P., M.D., Professor of Physiology in the Pennsylvania College of Dental Surgery; Adjunct Professor of Physiology and Hygiene in the Jefferson Medical College; Lecturer on Anatomy and Physiology in the Drexel Institute.

*1890. Brush, Edward N., M.D., Medical Superintendent of the Shepherd and Enoch Pratt Hospital, Towson, Md.

ELECTED

*1851. Bullock, William R., M.D., Wilmington, Del.

1892. Burr, Charles W., M.D., Professor of Mental Diseases in the University of Pennsylvania; Neurologist to the Philadelphia Hospital.

1886. Cadwalader, Charles E., M.D.

1895. Carpenter, John T., M.D., Instructor in Ophthalmology in the University of Pennsylvania.

*1897. Carter, William S., M.D., Professor of Physiology in the University of Texas.

1892. Cattell, Henry W., A.M., M.D., Editor of Lippincott's *Medical Dictionary;* Author of *Post-mortem Pathology;* Translator of Ziegler's *Special Pathology.*

*1892. Cerna, David, M.D., Ph.D., Monclova, Coah, Mexico; Corresponding Fellow of the Sociedad Española de Higiene of Madrid.

1900. Chance, Burton Kollock, M.D., Assistant Surgeon to the Wills Eye Hospital.

1885. Chapin, John B., M.D., Physician-in-Chief to the Pennsylvania Hospital for the Insane.

1880. Chapman, Henry C., M.D., Professor of the Institutes of Medicine and of Medical Jurisprudence in the Jefferson Medical College.

1900. Chase, Robert Howland, A.M., M.D., Superintendent of the Friends' Asylum for the Insane.

1868. Cheston, D. Murray, M.D.

1897. Cheston, Radcliffe, M.D.

1903. Chrystie, Walter, M.D.

1899. Clark, John G., M.D., Professor of Gynecology in the University of Pennsylvania; Gynecologist-in-Chief to the University Hospital.

1897. Claxton, Charles, A.M., M.D.

1872. Cleemann, Richard A., M.D.

1896. Cleveland, Arthur H., M.D., Clinical Professor of Laryngology in the Medico-Chirurgical College; Laryngologist to the Medico-Chirurgical Hospital; Laryngologist and Aurist to the Presbyterian Hospital, and to the Pennsylvania Institution for the Deaf and Dumb.

ELECTED

1903. Coates, George M., M.D., Surgeon to the Dispensary of the Children's Hospital; Instructor in Otology in the Philadelphia Polyclinic; Visiting Physician to the Philadelphia Orphanage; Major and Surgeon, 2d Regiment, National Guard of Pennsylvania.

1871. Cohen, J. Solis, M.D., Professor (Honorary) of Laryngology in the Jefferson Medical College; Professor (Emeritus) of Diseases of the Throat in the Philadelphia Polyclinic; Consulting Physician to the Protestant Episcopal Mission; Physician to the Hospital for Diseases of the Lungs, Chestnut Hill.

1888. Cohen, Solomon Solis, M.D., Senior Assistant Professor of Clinical Medicine in the Jefferson Medical College; Physician to the Jefferson Medical College Hospital, to the Philadelphia Hospital, to the Jewish Hospital, and to the Rush Hospital.

1898. Coles, Stricker, M.D., Demonstrator and Clinical Lecturer on Obstetrics in the Jefferson Medical College; Assistant Obstetrician to the Jefferson Maternity.

1901. Coley, Thomas Luther, M.D., Assistant Physician to the Methodist Episcopal Hospital; Associate Editor of the *Therapeutic Monthly*.

1903. Cooper, J. Cardeen, M.D., Consulting Physician to the Methodist Home for the Aged.

1903. Coplin, W. M. L., M.D., Professor of Pathology in the Jefferson Medical College; Pathologist to and Director of the Laboratories of the Jefferson Medical College Hospital; Pathologist to the Philadelphia Hospital and to the Friends' Asylum for the Insane, Frankford; Bacteriologist to the Pennsylvania State Board of Health.

1895. Cross, William A., M.D., Consulting Physician to the Jewish Hospital.

1902. Currie, Charles A., M.D., Physician to the Germantown Hospital.

1884. Curtin, Roland Gideon, A.M., M.D., Ph.D., Physician to the Philadelphia and the Presbyterian Hospitals; Consulting Physician to St. Timothy's Hospital and the Rush Hospital for Consumptives.

ELECTED

1884. Da Costa, John C., M.D., Gynecologist to the Jefferson Medical College Hospital; Consulting Gynecologist to St. Agnes's Hospital; President of the Philadelphia Obstetrical Society.

1903. Da Costa, John C., Jr., M.D., Demonstrator of Clinical Medicine in the Jefferson Medical College; Chief of the Medical Clinic in the Jefferson Medical College Hospital; Assistant Physician to the Philadelphia Hospital; Hæmatologist to the German Hospital.

1896. Da Costa, John Chalmers, M.D., Professor of the Principles of Surgery and of Clinical Surgery in the Jefferson Medical College; Surgeon to Philadelphia and St. Joseph's Hospitals.

1887. Daland, Judson, M.D., Professor of Clinical Medicine in the Medico-Chirurgical College; Physician to the Medico-Chirurgical Hospital.

1859. Darrach, James, M.D., Consulting Surgeon to the Germantown Hospital.

1896. Davis Charles N., M.D., Assistant Physician to the Dispensary for Diseases of the Skin in the Hospital of the University of Pennsylvania; Consulting Dermatologist to St. Mary's Hospital; Associate Physician in the Dispensary for Skin Diseases in the Howard Hospital; Associate Physician for Skin Diseases in the Northern Dispensary.

1888. Davis, Edward P., A.M., M.D., Professor of Obstetrics in the Jefferson Medical College and in the Philadelphia Polyclinic; Visiting Obstetrician to the Jefferson and Polyclinic Hospitals; Obstetrician and Gynecologist to the Philadelphia Hospital; Member of the American Gynecological Society, the American Pediatric Society, and of the International Congress of Obstetrics and Gynecology.

1889. Davis, Gwilym G., M.D. (Univ. of Penna. and Goettingen), M.R.C.S. Eng., Associate Professor of Applied Anatomy in the University of Pennsylvania; Surgeon to the Episcopal, St. Joseph's, and Orthopædic Hospitals.

1900. Davisson, Alex. Heron, M.D.

1894. Deaver, Harry C., M.D., Surgeon to the Episcopal, St. Mary's, and Samaritan Hospitals, and to St. Christopher's Hospital for Children.

1887. Deaver, John B., M.D., Surgeon-in-Chief to the German Hospital; Consulting Surgeon to the Germantown Hospital.

ELECTED

1892. Deaver, Richard Wilmot, M.D., Surgeon to the Germantown Hospital.

1902. Dehoney, Howard, M.D.

1885. Dercum, Francis X., M.D., Clinical Professor of Neurology in the Jefferson Medical College; Neurologist to the Philadelphia Hospital; Consulting Neurologist to St. Agnes's and the Jewish Hospitals, and to the State Asylum for the Chronic Insane of Pennsylvania.

1891. Dixon, Samuel G., M.D., President and Executive Curator of the Academy of Natural Sciences of Philadelphia; Member of the Council of the American Philosophical Society; Member of the Board of Trustees of the Wistar Institute of Anatomy; Member of the Board of Managers of the Philadelphia Zoölogical Society.

1896. Donnellan, P. S., M.D., L.R.C.S. and P., Ireland; Laryngologist to St. Agnes's Hospital; Medical Examiner of the Mutual Life Insurance Company of New York.

1897. Dorland, W. A. Newman, M.D., Associate in Gynecology in the Philadelphia Polyclinic and College for Graduates in Medicine; Assistant Instructor in Obstetrics in the University of Pennsylvania.

1902. Dougherty, Sherborne W., M.D., Instructor in Physical Diagnosis in the University of Pennsylvania; Physician to the Dispensary of the German Hospital; Assistant Physician to the Methodist Hospital.

1893. Downs, Norton, M.D.

1864. Downs, R. N., M.D.

1902. Downs, Robert N., Jr., M.D., Surgeon to the Dispensary of the Germantown Hospital.

1884. Drysdale, T. M., M.D.

1864. Duer, Edward L., A.M., M.D., Gynecologist to the Presbyterian Hospital; Consulting Obstetrician to the Maternity Hospital and to the Preston Retreat.

1897. Duer, S. Naudain, M.D., Physician to the Dispensary of the Presbyterian Hospital.

1871. Duhring, L. A., M.D., Professor of Dermatology in the University of Pennsylvania.

ELECTED

1881. Dulles, Charles Winslow, M.D., Lecturer on the History of Medicine in the University of Pennsylvania; Surgeon to the Rush Hospital.

*1871. Dunglison, Thomas R., M.D., Rosny sous Bois (Seine), France.

1860. Dunton, William R., M.D., Consulting Physician to the Germantown Hospital.

1899. Edsall, David L., M.D., Associate in Medicine in the University of Pennsylvania; Associate of the Pepper Laboratory of Clinical Medicine; Physician to the Episcopal Hospital and to St. Christopher's Hospital for Children.

*1887. Edwards, William A., M.D., Physician to the Coronado Hospital, Coronado, California.

1896. Ely, Thomas C., A.M., M.D.

1901. Erck, Theodore A., M.D., Assistant Surgeon to the Gynecean Hospital; Associate in Gynecology in the Philadelphia Polyclinic and College for Graduates in Medicine; Gynecologist to the Frederick Douglass Memorial Hospital.

1893. Eshner, Augustus A., M.D., Professor of Clinical Medicine in the Philadelphia Polyclinic and College for Graduates in Medicine; Physician to the Philadelphia Hospital; Assistant Physician to the Orthopædic Hospital and Infirmary for Nervous Diseases; Physician to the Hospital for Diseases of the Lungs, at Chestnut Hill.

1868. Evans, Horace Y., A.M., M.D.

1894. Faries, Randolph, M.D., Director of Physical Education in the Protestant Episcopal Academy.

1903. Farr, Clifford B., M.D., Pathologist and Assistant Physician to the Methodist Hospital; Instructor in Diseases of the Stomach at the Philadelphia Polyclinic; Assistant Physician in the Medical Dispensary of the Hospital of the University of Pennsylvania; Visiting Physician to the House of St. Michael, etc., for Colored Cripples.

1893. Farr, William W., M.D.

1884. Fenton, Thomas H., M.D., Medical Director and Senior Ophthalmologist to the Union Mission Hospital; Ophthalmologist to St. Vincent's Home, to the Home for Aged Couples, to the Baptist Home, and to the House of the Good Shepherd.

ELECTED

1884. Fisher, Henry M., M.D., Physician to the Episcopal Hospital; Physician to the Out-patient Department of the Pennsylvania Hospital.

*1900. Flexner, Simon, M.D., Director of the Rockefeller Institute, New York City; Member of the Association of American Physicians; Corresponding Member of La Societa Medico-Chirurgica di Bologna.

1888. Flick, Lawrence F., M.D.

1862. Forbes, William S., M.D., Professor of Anatomy in the Jefferson Medical College; Clinical Surgeon to the Jefferson Medical College Hospital.

*†1885. Fox, Joseph M., M.D., Leesburg, Va.

1903. Francine, Albert P., M.D., Instructor in Medicine in the University of Pennsylvania; Medical Registrar to the Philadelphia Hospital.

1897. Frazier, Charles H., M.D., Professor of Clinical Surgery in the University of Pennsylvania; Surgeon to the University, Philadelphia, and Howard Hospitals; Surgeon to the Home for Crippled Children.

†1890. Freeman, Walter J., M.D., Professor of Laryngology in the Philadelphia Polyclinic; Laryngologist to the Children's and Orthopædic Hospitals; Consulting Laryngologist to the Pennsylvania Institution for the Deaf and Dumb.

1900. French, Morris S., M.D.

1893. Friebis, George, M.D., Ophthalmic Surgeon to the Lutheran Home and Orphanage, Mt. Airy.

1899. Furness, William H., 3d, M.D.

1889. Fussell, M. Howard, M.D., Assistant Professor of Medicine in the University of Pennsylvania; Chief Physician to the Medical Dispensary of the Hospital of the University of Pennsylvania.

1899. Gamble, Robert G., M.D., one of the Attending Physicians to the Bryn Mawr Hospital.

1873. Gerhard, George S., M.D., Physician-in-Chief to the Bryn Mawr Hospital; Consulting Physician to Bryn Mawr College; Consulting Physician to Villa Nova College.

1864. Getchell, F. H., M.D.

ELECTED

1902. Ghriskey, Albert A., M.D., Clinical Pathologist to the Episcopal Hospital.

1892. Gibb, Joseph S., M.D., Professor of Diseases of the Throat and Nose in the Philadelphia Polyclinic; Surgeon to the Ear, Nose, and Throat Department of the Episcopal Hospital.

1899. Gibbon, John H., M.D., Surgeon to the Pennsylvania Hospital; Surgeon to the Bryn Mawr Hospital; Consulting Surgeon to the Woman's Hospital.

1897. Girvin, John H., M.D., Physician for Diseases of Women at the Presbyterian Hospital; Instructor in Obstetrics in the University of Pennsylvania.

1889. Githens, William H. H., M.D., Visiting Physician to the Sheltering Arms.

1894. Gleason, E. B., M.D., Clinical Professor of Otology in the Medico-Chirurgical College; Surgeon-in-Charge of the Nose, Throat, and Ear Department of the Northern Dispensary.

1884. Godey, Harry, M.D.

1893. Goodell, W. Constantine, M.D.

†1897. Gould, George M., A.M., M.D.

1894. Graham, Edwin E., M.D., Clinical Professor of Diseases of Children in the Jefferson Medical College; Physician to the Franklin Reformatory Home.

1885. Graham, John, M.D.

1883. Griffith, J. P. Crozer, M.D., Clinical Professor of the Diseases of Children in the University of Pennsylvania; Physician to St. Agnes's, the Children's and the Methodist Hospitals.

*1889. Guitéras, John, M.D.

1902. Gwyn, Norman B., M.D., Instructor in Medicine in the University of Pennsylvania.

*1893. Hamill, Robert H., M.D., Summit, N. J.

1894. Hamill, Samuel McC., M.D., Professor of Diseases of Children in the Philadelphia Polyclinic and College for Graduates in Medicine; Instructor in Clinical Medicine in the University of Pennsylvania; Physician to the Medical Dispensary of the Hospital of the University of Pennsylvania; Pediatrist to the Howard Hospital.

1897. Hand, Alfred, Jr., M.D., Physician to the Children's Hospital; Physician to the Harrison Day Nursery.

ELECTED

1886. HANSELL, HOWARD F., M.D., Clinical Professor of Ophthalmology in the Jefferson Medical College; Professor of Diseases of the Eye in the Philadelphia Polyclinic; Consulting Ophthalmologist to the Chester County Hospital and to the Frederick Douglass Memorial Hospital.

1889. HARE, HOBART A., M.D., Professor of Therapeutics in the Jefferson Medical College; Physician to the Jefferson Medical College Hospital.

1865. HARLAN, GEORGE C., M.D., Consulting Surgeon to the Wills Eye Hospital; Ophthalmic Surgeon to Pennsylvania Hospital, and to the Pennsylvania Institution for the Blind; Emeritus Professor of Diseases of the Eye in the Philadelphia Polyclinic.

1902. HARLAND, WILLIAM G. B., M.D., Instructor in Laryngology in the University of Pennsylvania; Aurist and Laryngologist to the Dispensary of the Presbyterian Hospital; Laryngologist to the Phipps Institute for Tuberculosis; Visiting Physician to the Philadelphia Home for Incurables.

1903. HART, CHARLES D., M.A., M.D., Physician to the Out-patient Department of the Pennsylvania Hospital; Inspector of the Eastern Penitentiary.

1885. HARTE, RICHARD H., M.D., Surgeon to the Pennsylvania and Episcopal Hospitals; Consulting Surgeon to St. Mary's and St. Timothy's Hospitals.

1888. HARTZELL, MILTON B., M.D., Associate in Dermatology in the University of Pennsylvania; Dermatologist to the Methodist Episcopal Hospital.

1872. HAYS, I. MINIS, M.D.

1882. HEARN, W. JOSEPH, M.D., Clinical Professor of Surgery in the Jefferson Medical College; Surgeon to Philadelphia Hospital.

1901. HEISLER, JOHN C., M.D., Professor of Anatomy in the Medico-Chirurgical College.

1884. HENRY, FREDERICK P., M.D., Physician to the Philadelphia Hospital; Professor of the Principles and Practice of Medicine in the Woman's Medical College of Pennsylvania.

1903. HENRY, J. NORMAN, M.D., Physician to the Out-patient Department of the Pennsylvania Hospital; Assistant Physician to the Philadelphia Hospital; Clinical Instructor in Medicine in the Woman's Medical College of Pennsylvania; Physician-in-Charge of the De Lancey School.

ELECTED

1891. Hewson, Addinell, A.M., M.D., Demonstrator of Anatomy in the Jefferson Medical College; Professor of Anatomy in the Philadelphia Polyclinic and College for Graduates in Medicine; Surgeon to St Timothy's Hospital, Roxborough; Senior Surgeon to the Dispensary of the Episcopal Hospital.

1872. Hinckle, A. G. B., M.D.

1897. Hinckle, William M., M.D., Lecturer on the Anatomy and Physiology of the Vocal Organs in the National School of Elocution and Oratory.

1892. Hinsdale, Guy, M.D., Consulting Physician to the Presbyterian Orphanage; Assistant Physician to the Orthopædic Hospital and Infirmary for Nervous Diseases and to the Presbyterian Hospital.

1888. Hirsh, A. Bern., M.D., Physician to the Home for Aged Couples.

1888. Hirst, Barton Cooke, M.D., Professor of Obstetrics in the University of Pennsylvania; Gynecologist to the Philadelphia and Howard Hospitals.

1903. Hirst, John Cooke, M.D., Assistant Obstetrician to the University and the Philadelphia Hospitals; Attending Physician to the Maternity Hospital, and to the Gynecological Dispensary of the Howard Hospital; Consulting Obstetrician to the Southeastern Dispensary.

*1894. Hoch, William R., M.D., Pueblo, Col.

1885. Holland, James W., M.D., Professor of Medical Chemistry and Toxicology in the Jefferson Medical College.

†1879. Hopkins, William Barton, M.D., Surgeon to the Pennsylvania Hospital.

1888. Horwitz, Orville, M.D., Professor of Genito-urinary Diseases in the Jefferson Medical College; Surgeon to the Philadelphia Hospital and to the State Hospital for the Insane; Consulting Surgeon to the Hayes Mechanics' Home.

1892. Hughes, William E., M.D., Visiting Physician to the Philadelphia Hospital; Pathologist to the Presbyterian Hospital.

1898. Hutchinson, James P., M.D., Surgeon to the Dispensaries of the Episcopal, Methodist, and Children's Hospitals.

1871. Ingham, James V., M.D.

ELECTED

*1885. Jackson, Edward, M.D., Denver, Col., Emeritus Professor of Diseases of the Eye in the Philadelphia Polyclinic; Ophthalmologist to the County Hospital, St. Anthony's Hospital, and the Mercy Sanitarium, Denver.

1887. Jayne, Horace, M.D., Ph.D., Professor of Zoölogy in the University of Pennsylvania; Director of the Wistar Institute of Anatomy and Biology.

1898. Johnson, Russell H., A.B. (Princeton), M.D., Physician to the Pennsylvania Institution for the Deaf and Dumb.

1900. Jones, Charles James, A.M., M.D., Ophthalmic Surgeon to the House of the Good Shepherd, Germantown; Assistant Surgeon to the Wills Eye Hospital.

1900. Jopson, John H., M.D., Surgeon to the Children's Hospital, the Bryn Mawr Hospital, and the Philadelphia Home for Incurables; Surgeon to the Dispensary of the Presbyterian Hospital.

1885. Judd, Leonardo da Vinci, M.D.

1900. Judson, Charles F., A.B., M.D., Physician to the Episcopal Hospital, St. Christopher's Hospital for Children, the Southern Home for Destitute Children, and the Sheltering Arms.

1902. Jump, Henry D., M.D., Instructor in Medicine in the University of Pennsylvania; Assistant Physician to the Medical Dispensary of the University Hospital.

1886. Jurist, Louis, M.D.

1903. Kalteyer, Frederick J., M.D., Demonstrator of Clinical Medicine in the Jefferson Medical College; Chief of the Out-patient Department, Assistant Attending Physician and Hæmatologist to the Jefferson Medical College Hospital; Pathologist to the Philadelphia Lying-in Charity.

†1867. Keen, William W., M.D., LL.D., F.R.C.S. (Hon.), Professor of the Principles of Surgery and of Clinical Surgery in the Jefferson Medical College; Membre Correspondant Étranger de la Société de Chirurgie de Paris; Honorary Member of the Société Belge de Chirurgie and of the Clinical Society of London; Ehrenmitglied der Deutschen Gesellschaft für Chirurgie.

ELECTED

1897. Kelly, Aloysius O. J., M.D., Associate in Medicine in the University of Pennsylvania; Assistant Physician to the University Hospital; Clinical Professor of Pathology in the Woman's Medical College of Pennsylvania; Visiting Physician to St. Mary's and St. Agnes's Hospitals; Pathologist to the German Hospital.

*1887. Kelly, Howard A., M.D., Professor of Gynecology in Johns Hopkins University and Gynecologist to the Johns Hopkins Hospital, Baltimore, Md.

1898. Kempton, Augustus F., M.D.

1902. King, William Howard, M.D.

1895. Kneass, Samuel S., M.D., Associate in William Pepper Laboratory of Clinical Medicine in University of Pennsylvania.

1900. Krusen, Wilmer, M.D., Instructor in Gynecology in Jefferson Medical College; Assistant Gynecologist and Chief of the Gynecological Dispensary of St. Joseph's Hospital; Consulting Gynecologist to the Children's Hospital in Germantown.

1897. Kyle, D. Braden, M.D., Clinical Professor of Laryngology, Rhinology, and Otology in the Jefferson Medical College; Consulting Laryngologist, Rhinologist, and Otologist to St. Agnes's Hospital and to the Philadelphia Home for Incurables; Laryngologist to the New Jersey Training School for Feeble-minded Children; Bacteriologist to the Orthopædic Hospital and Infirmary for Nervous Diseases.

1865. La Roche, C. Percy, M.D.

*1892. Lainé, Damaso T., M.D., Havana, Cuba.

1887. Leaman, Henry, M.D.

1893. Le Conte, Robert G., A.B., M.D., Surgeon-General, National Guard of Pennsylvania; Adjunct Professor of Surgery in the University of Pennsylvania; Surgeon to the Pennsylvania, the Children's, and the Bryn Mawr Hospitals; Consulting Surgeon to the Germantown Hospital.

1903. Leffmann, Henry, A.M., M.D., D.D.S., Ph.D., Professor of Chemistry and Toxicology in the Woman's Medical College of Pennsylvania; Professor of Chemistry in the Wagner Free Institute of Science; Pathological Chemist to the Jefferson Medical College Hospital; Chemist to the State Board of Health of Pennsylvania.

ELECTED

1892. LEIDY, JOSEPH, M.D., Physician to the Out-patient Department of the Pennsylvania Hospital; Consulting Physician to the Pennsylvania Training School for Feeble-minded Children.

1903. LEONARD, CHARLES LESTER, M.D.

1877. LEWIS, MORRIS J., M.D., Physician to the Children's Hospital, to the Orthopædic Hospital and Infirmary for Nervous Diseases and to the Pennsylvania Hospital.

1886. LLOYD, J. HENDRIE, M.D., Physician to the Methodist Episcopal Hospital and to the Home for Crippled Children; Consulting Neurologist to the State Asylum for the Chronic Insane of Pennsylvania and to the Pennsylvania Training School for Feeble-minded Children.

1900. LODGE, JOHN W., M.D., Consulting Physician to the Bryn Mawr Hospital.

1893. LONGAKER, DANIEL, M.D., Surgeon to the Jewish Maternity Hospital.

1877. LONGSTRETH, MORRIS, M.D.

1900. MCCARTHY, DANIEL J., M.D., Instructor in Neurology in the Philadelphia Polyclinic; Associate of the William Pepper Laboratory of Clinical Medicine.

1875. MCCLELLAN, GEORGE, M.D., Consulting Surgeon to the Howard Hospital.

1903. MCCONNELL, GUTHRIE, M.D., Demonstrator of Pathology in the Medico-Chirurgical College; Assistant Pathologist to the Philadelphia Hospital; Pathologist to the Howard Hospital; Assistant Pathologist to the Polyclinic Hospital.

1895. MCFARLAND, JOSEPH, M.D., Professor of Pathology and Bacteriology in the Medico-Chirurgical College; Pathologist to the Medico-Chirurgical and the Philadelphia Hospitals.

1900. MCREYNOLDS, ROBERT PHILLIPS, M.D., one of the Resident Chiefs and one of the Chiefs of the Gynecological Dispensary of the Presbyterian Hospital.

1886. MACCOY, ALEXANDER W., M.D., Surgeon for Diseases of the Nose and Throat in the Out-patient Department of the Pennsylvania Hospital; Member of the American Laryngological Society.

ELECTED

1901. MacLeod, George I., Jr., M.D., Assistant Physician to the Bryn Mawr Hospital.

1896. Makuen, G. Hudson, M.D., Professor of Defects of Speech in the Philadelphia Polyclinic; Laryngologist to St. Mary's Hospital and to the Frederick Douglass Memorial Hospital; Visiting Consultant on Defects of Speech to the New Jersey Training School for Feeble-minded Children.

*1885. Mallet, John William, M.D., Ph.D. (Goett.), LL.D. (Princeton), F.R.S., Professor of Chemistry in the University of Virginia.

1898. Marshall, George Morley, M.D., Laryngologist to the Philadelphia Hospital; Physician and Laryngologist to St. Joseph's Hospital.

1893. Marshall, John, M.D., Nat. Sc. D., LL.D., Professor of Chemistry and Toxicology in the University of Pennsylvania.

1889. Martin, Edward, M.D., Professor of Clinical Surgery in the University of Pennsylvania; Surgeon to University, Howard, St. Agnes's, Philadelphia and Bryn Mawr Hospitals.

1885. Mays, Thomas J., M.D., Visiting Physician to the Rush Hospital.

*1868. Mears, J. Ewing, M.D.

1875. Meigs, Arthur V., M.D., Physician to the Pennsylvania Hospital; Consulting Physician to the Pennsylvania Institution for the Instruction of the Blind.

*1884. Mifflin, Houston, M.D., Columbia, Pa.

1894. Miller, D. J. Milton, M.D., Physician to the Episcopal Hospital; Assistant Physician to the Children's Hospital.

1881. Mills, Charles K., M.D., Professor of Neurology in the University of Pennsylvania; Neurologist to the Philadelphia Hospital.

†1888. Mitchell, John K., M.D., Assistant Physician to the Orthopædic Hospital and Infirmary for Nervous Diseases; Assistant Neurologist to the Presbyterian Hospital; Attending Physician to the Pennsylvania Training School for Feeble-minded Children.

1856. Mitchell, S. Weir, M.D., M. Nat. Ac. Sci., LL.D. (Harvard, Edinburgh and Princeton); M.D. *Honoris Causa* (Bologna, Italy); Physician to the Orthopædic Hospital and Infirmary for Nervous Diseases; Physician to the Presbyterian Hospital.

ELECTED

1882. MONTGOMERY, EDWARD E., M.D., Professor of Gynecology in the Jefferson Medical College; Gynecologist to the Jefferson Medical College Hospital and to St. Joseph's Hospital.

1863. MOREHOUSE, GEORGE READ, M.D., Ph.D. (Princeton), Consulting Physician to the Orthopædic Hospital and Infirmary for Nervous Diseases.

1886. MORRIS, CASPAR, M.D.

1893. MORRIS, ELLISTON J., M.D., Physician to the Episcopal Hospital, the Sheltering Arms and the Midnight Mission.

1883. MORRIS, HENRY, M.D., Visiting Physician to St. Joseph's Hospital.

1856. MORRIS, J. CHESTON, M.D.

1897. MORTON, SAMUEL W., M.D.

1891. MORTON, THOMAS S. K., M.D.

1864. MOSS, WILLIAM, M.D.

1890. MÜLLER, AUGUSTE F., M.D., Surgeon to and Chief of Staff of the Germantown Hospital.

1882. MUSSER, JOHN H., M.D., Professor of Clinical Medicine in the University of Pennsylvania; Physician to the University, the Philadelphia and the Presbyterian Hospitals.

1896. MYERS, T. D., M.D., Lecturer on Ophthalmology in the U. S. Navy Medical School.

1902. NASSAU, CHARLES F., M.D., Surgeon to St. Joseph's Hospital; Physician to Dispensary for Women of the German Hospital.

1886. NEFF, JOSEPH S., M.D.

1887. NEILSON, THOMAS RUNDLE, M.D., Surgeon to the Episcopal Hospital and to St. Christopher's Hospital for Children; Clinical Professor of Genito-urinary Diseases in the University of Pennsylvania.

1899. NICHOLSON, WILLIAM R., JR., M.D., Assistant Instructor in Obstetrics in the University of Pennsylvania; Obstetrician to Maternity Hospital; Assistant Surgeon to Gynecean Hospital.

1889. NOBLE, CHARLES P., M.D., Surgeon-in-Chief to the Kensington Hospital for Women; Surgeon-in-Charge of the Department for Women of the Northern Dispensary and of the Union Mission Hospital; Clinical Professor of Gynecology in the Woman's Medical College of Pennsylvania; Lecturer on Gynecology in the Philadelphia Polyclinic.

ELECTED

1893. Noble, William H., M.D.

1898. Nolan, Edward J., M.D., Recording Secretary and Librarian of the Academy of Natural Sciences of Philadelphia.

1901. Norris, Henry, M.D., Chief of the Surgical Dispensary of the Hospital of the University of Pennsylvania; Clinical Assistant in the Clinic for Genito-urinary Surgery in the Polyclinic Hospital.

1869. Norris, Herbert, M.D.

1865. Norris, Isaac, M.D.

1892. Norris, Richard C., M.D., Lecturer on Clinical and Operative Obstetrics in the University of Pennsylvania; Obstetrician in Charge to the Preston Retreat; Visiting Obstetrician to the Philadelphia Hospital; Gynecologist to the Methodist Hospital and Consulting Obstetrician and Attending Gynecologist to the Southeastern Dispensary and Hospital.

1884. Oliver, Charles A., A.M., M.D., Surgeon to the Wills Eye Hospital; Ophthalmic Surgeon to the Philadelphia and the Presbyterian Hospitals; Associate Clinical Professor of Ophthalmology in the Woman's Medical College of Pennsylvania.

1884. O'Neill, J. Wilks, M.D.

*1885. Osler, William, M.D., Professor of Medicine in the Johns Hopkins University and Physician to the Johns Hopkins Hospital, Baltimore, Md.

1903. Ostheimer, Maurice, M.D., Instructor in Pediatrics in the University of Pennsylvania; Physician to the Medical Dispensary of St. Christopher's Hospital for Children; Registrar in the Medical Dispensary of the Children's Hospital.

1897. Packard, Francis R., M.D., Aurist to the Out-patient Department of the Pennsylvania Hospital; Professor of Diseases of the Ear in the Philadelphia Polyclinic and College for Graduates in Medicine; Consulting Aurist to the Bryn Mawr Hospital; Editor of the *American Journal of the Medical Sciences.*

1858. Packard, John H., M.D., Late Surgeon to the Pennsylvania Hospital; Surgeon Emeritus to St. Joseph's Hospital.

ELECTED

1898. Page, Henry F., M.D., Assistant Physician to the German Hospital and Physician to the Medical Dispensary of the same; Instructor in Clinical Medicine in the Woman's Medical College of Pennsylvania; Physician to the Baptist Home.

1899. Parke, William E., M.D., Assistant Surgeon in the Department for Diseases of Women in the Northern Dispensary; Clinical Assistant and Surgeon to the Dispensary of the Kensington Hospital for Women.

†1898. Pearce, F. Savary, M.D., Clinical Professor of Nervous and Mental Diseases in the Medico-Chirurgical College of Philadelphia; Neurologist to the Philadelphia and Howard Hospitals; Secretary of the Section on Nervous and Mental Diseases of the American Medical Association.

*1903. Pearce, Richard M., M.D., Director of the Bender Laboratory, Albany, N. Y.; Professor of Pathology in the Albany Medical School; Director of the Bureau of Pathology and Bacteriology of the New York State Board of Health.

†1889. Penrose, Charles Bingham, M.D., Ph.D. (Harvard). Formerly Professor of Gynecology in the University of Pennsylvania.

1854. Penrose, R. A. F., M.D., LL.D., Professor (Emeritus) of Obstetrics and Diseases of Women and Children in the University of Pennsylvania.

†1902. Pepper, William, M.D., Pathologist to St. Christopher's Hospital for Children; Instructor in Medicine in the University of Pennsylvania.

1884. Perkins, Francis M., M.D., Ophthalmic Surgeon to St. Agnes's Hospital.

1899. Phillips, John L., M.D.

1883. Piersol, George A., M.D., Professor of Anatomy in the University of Pennsylvania.

1872. Porter, William G., M.D., Surgeon to the Presbyterian Hospital; Consulting Physician to the Philadelphia Dispensary and to the Educational Home for Boys.

1896. Posey, William Campbell, M.D., Surgeon to the Wills Eye Hospital; Professor of Ophthalmology in the Philadelphia Polyclinic and College for Graduates in Medicine; Ophthalmic Surgeon to the Howard Hospital; Ophthalmologist to the Pennsylvania Hospital for Epileptics.

ELECTED

1885. POTTER, THOMAS C., M.D.

1902. POTTS, BARTON H., M.D., Associate in Diseases of the Ear in the Philadelphia Polyclinic and College for Graduates in Medicine; Aurist and Laryngologist to St. Mary's Hospital; Aurist and Laryngologist to the Out-patient Department of the German Hospital; Assistant Aurist and Ophthalmologist to the Children's Hospital.

1899. POTTS, CHARLES S., M.D., Associate in Neurology in the University of Pennsylvania; Assistant Neurologist to the University Hospital; Neurologist to the Philadelphia Hospital; Consulting Physician to the Hospital for the Insane, Atlantic County, New Jersey.

†1899. PRICE, JOSEPH, M.D., Obstetric Physician to the Philadelphia Dispensary.

1903. PURVES, GEORGE MOREHOUSE, M.D., Registrar of the Surgical Dispensary of the Hospital of the University of Pennsylvania.

1903. PYLE, WALTER, M.D., Assistant Surgeon to the Wills Eye Hospital.

1887. RANDALL, B. ALEXANDER, M.A., M.D., Clinical Professor of Diseases of the Ear in the University of Pennsylvania; Eye and Ear Surgeon to the Children's Hospital; Consulting Aurist to the Pennsylvania Institution for the Deaf and Dumb and to St. Timothy's Hospital.

1887. REED, CHARLES H., M.D.

1885. REICHERT, EDWARD T., M.D., Professor of Physiology in the University of Pennsylvania.

1897. RHEIN, JOHN H. W., M.D., Neurologist to St. Agnes's Hospital; Assistant Physician to the Orthopædic Hospital and Infirmary for Nervous Diseases; Physician to the Philadelphia Home for Incurables; Bacteriologist to the Pennsylvania Training School for Feeble-minded Children.

1891. RHOADS, EDWARD G., M.D.

1898. RIESMAN, DAVID, M.D., Professor of Clinical Medicine in the Philadelphia Polyclinic; Associate in Medicine in the University of Pennsylvania; Physician to the Philadelphia and the Jewish Hospitals.

ELECTED

1895. Ring, G. Oram, M.D., Ophthalmic Surgeon to the Episcopal Hospital; Ophthalmic and Aural Surgeon to the Samaritan Hospital.

1891. Risley, S. D., M.D., Attending Surgeon to the Wills Eye Hospital; Professor (Emeritus) of Ophthalmology in the Philadelphia Polyclinic and College for Graduates in Medicine; Member of the Board of Managers of the Pennsylvania Training School for Feeble-minded Children; Alumnus Manager of the University Hospital.

†1878. Roberts, John B., M.D., Professor of Anatomy and Surgery in the Philadelphia Polyclinic; Surgeon to the Methodist Hospital.

1899. Roberts, Walter, M.D., Instructor in Otology in the Philadelphia Polyclinic; Clinical Assistant for Diseases of the Nose and Throat in the Out-patient Department of the Pennsylvania Hospital.

1903. Robertson, William Egbert, M.D., Assistant Visiting Physician and Chief of Dr. Daland's Clinic in the Medico-Chirurgical Hospital; Lecturer to Nurses in the Medico-Chirurgical Hospital; Pathologist to the Episcopal Hospital.

*1888. Robins, Robert P., M.D.

1902. Robinson, James Weir, M.D., Assistant Surgeon to the Presbyterian Hospital.

1903. Robinson, William Duffield, M.D.

1900. Rodman, William L., M.D., Professor of the Principles of Surgery and Clinical Surgery in the Medico-Chirurgical College; Professor of the Principles and Practice of Surgery in the Woman's Medical College of Pennsylvania.

1898. Ross, George G., M.D., Assistant Surgeon to the German Hospital and Surgeon to the Out-patient Department of the same; Surgeon to the Germantown Hospital.

1897. Sailer, Joseph, M.D., Associate in Medicine in the University of Pennsylvania; Associate of the Pepper Clinical Laboratory of the University of Pennsylvania; Pathologist to the Pennsylvania Training School for Feeble-minded Children.

1900. Sajous, Charles E. de M., M.D.

ELECTED

1899. SCHAMBERG, JAY F., M.D., Professor of Dermatology and Infectious Eruptive Diseases in the Philadelphia Polyclinic and College for Graduates in Medicine; Assistant Physician to the Municipal Hospital for Infectious Diseases.

1887. DE SCHWEINITZ, GEORGE E., M.D., Professor of Ophthalmology in the University of Pennsylvania; Ophthalmologist to the Orthopædic Hospital and Infirmary for Nervous Diseases; Ophthalmic Surgeon to the Philadelphia Hospital; Consulting Ophthalmologist to the Philadelphia Polyclinic and College for Graduates in Medicine.

1895. SCOTT, J. ALISON, M.D., Adjunct Professor of Medicine in the University of Pennsylvania; Visiting Physician to the Pennsylvania Hospital; Physician to the Church Home for Children.

1892. SEISS, RALPH W., M.D., Professor of Otology in the Philadelphia Polyclinic; Consulting Laryngologist to the Pennsylvania Institution for the Deaf and Dumb.

1884. SHAFFNER, CHARLES, A.M., M.D.

1897. SHARPLESS, W. T., M.D., Physician to the Chester County Hospital, West Chester, Pa.

1876. SHIPPEN, EDWARD, A.M. (Princeton), M.D., Medical Director U. S. Navy (retired).

1891. SHOBER, JOHN B., A.M., M.D., Associate Gynecologist to the Gynecean Hospital; Gynecologist to the Howard Hospital; Obstetrician to the Philadelphia Hospital.

1890. SHOEMAKER, GEORGE ERETY, A.M., M.D., Gynecologist to the Presbyterian Hospital and to the Pennsylvania Epileptic Hospital and Colony Farm.

†1893. SHOEMAKER, HARVEY, M.D., Visiting Physician to the Sheltering Arms and to the Southern Home for Destitute Children; Assistant Physician to the German Hospital; Physician to the Out-patient Departments of the German and Pennsylvania Hospitals.

†1896. SHOEMAKER, WILLIAM T., M.D., Assistant Ophthalmologist to the German Hospital and Ophthalmic Surgeon to the Out-patient Department of the same; Ophthalmic Surgeon to Out-patient Department of the Presbyterian Hospital; Ophthalmologist to the Southern Home for Destitute Children; Oculist to Pennsylvania Institution for the Deaf and Dumb.

ELECTED

1900. Shumway, Edward Adams, B.S., M.D., Instructor in Ophthalmology in the University of Pennsylvania; Assistant Ophthalmic Surgeon to the University and to the Philadelphia Hospitals; Ophthalmologist to the Henry Phipps Institute for the Study, Treatment, and Prevention of Tuberculosis, to the Presbyterian Home for Widows and Single Women, and to the Magdalene Home.

1880. Simes, J. Henry C., M.D., Emeritus Professor of Genito-urinary and Venereal Diseases in the Philadelphia Polyclinic.

1903. Sinclair, John Falconer, M.D., Physician to the Medical Dispensary of the Presbyterian Hospital; Physician to the Philadelphia Orphan Asylum and to the Presbyterian Orphanage.

1872. Sinkler, Wharton, M.D., Physician to the Orthopædic Hospital and Infirmary for Nervous Diseases; Neurologist to the State Asylum for the Chronic Insane of Pennsylvania.

1902. Siter, E. Hollingsworth, M.D., Instructor in Genito-urinary Diseases in the University of Pennsylvania; Chief Surgeon to the Genito-urinary Dispensary of the University Hospital; Surgeon to the Dispensaries of the Children's and St. Agnes's Hospitals.

1895. Slocum, Harris A., M.D., Professor of Gynecology in the Philadelphia Polyclinic; Gynecologist to St. Clement's Hospital for Epileptics.

1895. Spellissy, Joseph M., A.M., M.D., Surgeon to St. Joseph's and the Methodist Episcopal Hospitals; Assistant Surgeon to the Orthopædic Dispensary of the University Hospital; Surgeon to the Out-patient Department of the Pennsylvania Hospital.

1897. Spiller, William G., M.D., Associate Professor of Neurology and Professor of Neuropathology in the University of Pennsylvania; Clinical Professor of Nervous Diseases in the Woman's Medical College of Pennsylvania; Professor of Nervous Diseases in the Philadelphia Polyclinic and College for Graduates in Medicine.

1894. Stahl, B. Franklin, Ph.G., B.S., M.D., Instructor in Physical Diagnosis and Lecturer on Dietetics of the Sick in the University of Pennsylvania; Visiting Physician to St. Agnes's Hospital; Neurological Registrar to Philadelphia Hospital.

ELECTED

1875. STARR, LOUIS, M.D.

1898. STEELE, J. DUTTON, M.D., Associate in Medicine in the University of Pennsylvania; Physician to the Medical Dispensary of the University Hospital; Bacteriologist to the Presbyterian Hospital.

1892. STEINBACH, LEWIS W., M.D., Professor of Clinical and Operative Surgery in the Philadelphia Polyclinic; Visiting Surgeon to the Philadelphia and the Jewish Hospitals.

1884. STELWAGON, HENRY W., M.D., Ph.D., Clinical Professor of Dermatology in the Jefferson Medical College and in the Woman's Medical College; Physician to the Department for Skin Diseases of the Howard Hospital; Socio Corrispondente di la Societa Italiano di Dermatologia e Sifilografia.

1895. STENGEL, ALFRED, M.D., Professor of Clinical Medicine in the University of Pennsylvania; Physician to the University, Pennsylvania and Children's Hospitals.

1901. STEVENS, ARTHUR A., M.D., Professor of Pathology in the Woman's Medical College of Pennsylvania; Lecturer on Physical Diagnosis in the University of Pennsylvania; Physician to the Episcopal and St. Agnes's Hospitals.

1888. STEWART, DAVID D., M.D., Consulting Physician to the Kensington Hospital for Women.

1902. STEWART, FRANCIS T., M.D., Professor of Surgery in the Philadelphia Polyclinic and College for Graduates in Medicine; Surgeon to the Germantown Hospital; Assistant Surgeon to the Jefferson Medical College Hospital; Surgeon to the Out-patient Department of the Pennsylvania Hospital.

1898. STILES, GEORGE M., M.D.

1898. STOUT, GEORGE C., M.D., Professor of Otology in the Philadelphia Polyclinic and College for Graduates in Medicine; Laryngologist and Aurist to the Presbyterian Hospital, the Children's Aid Society, and to the William Penn Charter School.

1884. STRYKER, SAMUEL S., M.D., Physician to the Presbyterian Hospital.

1900. SWAN, JOHN M., M.D., Demonstrator of Osteology in the University of Pennsylvania; Instructor in Clinical Medicine in the Philadelphia Polyclinic; Pathologist to St. Mary's Hospital.

ELECTED

1898. Sweet, William M., M.D., Demonstrator of Ophthalmology in the Jefferson Medical College; Assistant Attending Ophthalmic Surgeon to the Jefferson Medical College Hospital; Ophthalmic Surgeon to the Phœnixville Hospital.

1900. Talley, James Ely, A.B., M.D., Physician to the Out-patient Department of the Presbyterian Hospital; Assistant and Consulting Physician to the Country Branch of the Children's Hospital.

1901. Taylor, J. Gurney, M.D., Physician to the Pennsylvania Institution for the Instruction of the Blind.

1886. Taylor, John Madison, M.D., Pediatrist to the Philadelphia Hospital; Assistant Physician to the Orthopædic Hospital and Infirmary for Nervous Diseases; Assistant Physician to the Children's Hospital.

1887. Taylor, William J., M.D., Surgeon to the Orthopædic Hospital and Infirmary for Nervous Diseases, and to St. Agnes's Hospital; Consulting Surgeon to the West Philadelphia Hospital for Women.

1886. Taylor, William L., M.D.

1867. Thomas, Charles Hermon, M.D.

1897. Thomson, A. G., M.D., Ophthalmic Surgeon to the Children's Hospital; Assistant Surgeon to the Wills Eye Hospital; Assistant Ophthalmologist to the Orthopædic Hospital and Infirmary for Nervous Diseases.

†1869. Thomson, William, M.D., Emeritus Professor of Ophthalmology in the Jefferson Medical College; Surgeon to Wills Eye Hospital.

1896. Thorington, James, A.M., M.D., Professor of Diseases of the Eye in the Philadelphia Polyclinic; Member of the American Ophthalmological Society; Ophthalmologist to the Vineland and Elwyn Training Schools for Feeble-minded Children.

1898. Thornton, Edward Q., M.D., Assistant Professor of Materia Medica in the Jefferson Medical College.

1896. Toulmin, Harry, M.D., Assistant Medical Director of the Penn Mutual Life Insurance Company.

1901. Tucker, Henry, M.D.

†1894. Tunis, Joseph Price, M.D., Medical Examiner to the Equitable Life Assurance Society of the United States.

ELECTED

1901. Turner, John B., M.D., Clinical Assistant at the Wills Eye Hospital.

1866. Tyson, James, A.M., M.D., Professor of Medicine in the University of Pennsylvania and Physician to the Hospital of the University of Pennsylvania; Physician to the Philadelphia Hospital; Member of the Association of American Physicians.

1897. Tyson, T. Mellor, M.D., Assistant Physician to the Hospital of the University of Pennsylvania; Physician to the Rush Hospital, the Philadelphia Lying-in Charity Hospital and the Children's Aid Society of Philadelphia.

1873. Van Harlingen, Arthur, Ph.B. (Yale), M.D., Emeritus Professor of Dermatology in the Philadelphia Polyclinic; Dermatologist to the Children's Hospital.

1903. Van Pelt, William Turner, M.D., Ophthalmic Surgeon to the Episcopal Hospital.

1893. Vansant, Eugene Larue, M.D., Professor of Diseases of the Throat and Nose in the Philadelphia Polyclinic; Visiting Physician to the Throat, Nose and Ear Department of the Howard Hospital.

1897. Veasey, Clarence A., M.D., Adjunct Professor of Diseases of the Eye in the Philadelphia Polyclinic and College for Graduates in Medicine; Demonstrator of Ophthalmology in the Jefferson Medical College; Chief Clinical Assistant to the Ophthalmological Department of the Jefferson Medical College Hospital; Consulting Ophthalmologist to the Philadelphia Lying-in Charity Hospital.

†1883. Vinton, Charles Harrod, M.D.

1903. Wadsworth, William Scott, M.D.

1885. Walker, James B., M.D., Ph.D., Consulting Physician to the West Philadelphia Hospital for Women and Children.

1893. Warren, Joseph W., M.D., Associate Professor of Physiology in Bryn Mawr College.

1895. Watson, Arthur W., M.D., Professor of Diseases of the Throat and Nose in the Philadelphia Polyclinic; Laryngologist to the Howard Hospital and to the Hospital for Diseases of the Lungs, Chestnut Hill.

1886. Watson, Edward W., M.D.

ELECTED

1903. WEBER, CHARLES H., M D., Physician to the Episcopal Hospital; Physician to the Dispensary of the Children's Hospital.

1883. WELCH, WILLIAM M., M.D., Physician-in-Charge of the Municipal Hospital for Contagious Diseases; Consulting Physician to the Northern Dispensary and to the Northern Home for Friendless Children.

1897. WELLS, WILLIAM H., M.D., Adjunct Professor of Obstetrics and Diseases of Infancy in Philadelphia Polyclinic; Demonstrator of Clinical Obstetrics in the Jefferson Medical College.

1893. WESTCOTT THOMPSON S., M.D., Associate in Diseases of Children in the University of Pennsylvania; Visiting Physician to the Methodist Episcopal Hospital; Assistant Physician to the Children's Hospital.

1884. WHARTON, HENRY R., M.D., Clinical Professor of Surgery in the Woman's Medical College of Pennsylvania; Surgeon to the Presbyterian and Children's Hospital; Consulting Surgeon to the Bryn Mawr Hospital, St. Christopher's Hospital for Children and the Pennsylvania Institution for the Deaf and Dumb.

1901. WHITE, COURTLAND Y., M.D., Assistant Director of the William Pepper Laboratory of Clinical Medicine; Pathologist to the State Live Stock Association; Lecturer on and Demonstrator of Gross Morbid Anatomy in the Veterinary Department of the University of Pennsylvania; Pathologist to the Children's and the Jewish Hospitals.

1878. WHITE, J. WILLIAM, M.D., Ph.D., John Rhea Barton Professor of Surgery in the University of Pennsylvania; Surgeon to the University Hospital; Fellow of the American Surgical Association and of the American Association of Genito-urinary Surgeons.

1898. WHITING, ALBERT D., M.D., Assistant Surgeon and Registrar to the German Hospital, and Surgeon to the Out-patient Department of the same; Surgeon to the Southern Home for Destitute Children.

†1880. WILLARD, DE FOREST, A.M., M.D., Ph.D., Professor of Orthopedic Surgery in the University of Pennsylvania; Surgeon to the Presbyterian Hospital; ex-President of the American Surgical Association; Consulting Surgeon to the Germantown, the Atlantic City, and Phœnixville Hospitals.

ELECTED

*1878. WILLIAMSON, JESSE, M.D., Wilmington, Delaware, one of the Surgeons to the Delaware Hospital.

1902. WILLSON, ROBERT N., JR., M.D., Instructor in Physical Diagnosis, and Students' Physician in the University of Pennsylvania.

1881. WILSON, H. AUGUSTUS, M.D., Emeritus Professor of Orthopedic Surgery in the Philadelphia Polyclinic; Clinical Professor of Orthopedic Surgery in the Jefferson Medical College; Consulting Orthopedic Surgeon to the Philadelphia Lying-in Charity Hospital and to the Kensington Hospital for Women.

1874. WILSON, JAMES C., M.D., Professor of the Practice of Medicine and of Clinical Medicine in the Jefferson Medical College, and Physician to the Hospital of the same (Faculty Staff); Physician-in-Chief to the German Hospital; Attending Physician to the Pennsylvania Hospital.

1902. WILSON, SAMUEL M., M.D.

1897. WILSON, W. REYNOLDS, M.D., Visiting Physician to the Philadelphia Lying-in Charity Hospital.

*1901. WITMER, A. FERREE, M.D., New York.

1893. WOOD, ALFRED C., M.D., Assistant Professor of Surgery in the University of Pennsylvania; Assistant Surgeon to the University Hospital; Surgeon to the Philadelphia Hospital.

1900. WOOD, GEORGE B., M.D., Instructor in Laryngology in the University of Pennsylvania; Assistant in the Clinic for Diseases of the Nose and Throat at the Polyclinic Hospital.

1865. WOOD, HORATIO C., M.D., LL.D. (Yale and Lafayette); Professor of Materia Medica and Therapeutics in the University of Pennsylvania; Associate Fellow in Medicine and Surgery of the American Academy of Arts and Sciences; Member of the National Academy of Science.

1903. WOOD, HORATIO C., JR., M.D., Demonstrator of Pharmacodynamics in the University of Pennsylvania; Associate in Clinical Medicine in the Philadelphia Polyclinic; Assistant Visiting Physician to the Philadelphia Hospital.

1880. WOODBURY, FRANK, M.D., Associate in Laryngology in the Philadelphia Polyclinic.

1866. WOODS, D. F., M.D., Physician to the Presbyterian Hospital.

ELECTED

1901. Woods, Richard F., M.D., Assistant Surgeon to the Gynecean Hospital.

1888. Woodward, Charles E., M.D., Secretary of the West Chester Board of Health; U. S. Examining Surgeon; Member of the Medical Staff of the Chester County Hospital.

†1897. Woodward, George, M.D.

1903. Worden, Charles B., M.D., Associate in Diseases of the Stomach and Intestines in the Philadelphia Polyclinic; Physician to the Dispensary of the Presbyterian Hospital; Anæsthetizer to the Orthopedic Department of the University Hospital; Physician to the Presbyterian Orphanage.

1860. Wurts, Charles Stewart, M.D.

1889. Young, James K., M.D., Professor of Orthopedic Surgery in the Philadelphia Polyclinic; Clinical Professor of Orthopedic Surgery in the Woman's Medical College of Pennsylvania; Instructor in Orthopedic Surgery in the University of Pennsylvania and Assistant Orthopedic Surgeon to the University Hospital.

1894. Zentmayer, William, M.D., Attending Surgeon to the Wills Eye Hospital; Ophthalmic Surgeon to St. Mary's Hospital; Ophthalmologist to the House of Refuge.

1899. Ziegler, S. Lewis, M.D., Attending Surgeon to the Wills Eye Hospital; Ophthalmic Surgeon to St. Joseph's Hospital; Membre Société Française d'Ophthalmologie.

1887. Ziegler, Walter M. L., A.M., M.D.

1895. Zimmerman, Mason W., M.D., Ophthalmic Surgeon to the Germantown Hospital.

ASSOCIATE FELLOWS.

[Limited to Fifty, of whom Twenty may be Foreigners.]

American.

ELECTED

1876. Billings, John S., M.D., U. S. A. (retired), New York.
1886. Bowditch, Henry P., M.D., Boston, Massachusetts.
1877. Chaillé, Stanford E., M.D., New Orleans, Louisiana.
1886. Cheever, David W., M.D., Boston, Massachusetts.
1896. Conner, Phineas Sanborn, M.D., Cincinnati, Ohio.
1893. Councilman, William T., M.D., Boston, Massachusetts.
1876. Davis, N. S., M.D., Chicago, Illinois.
1892. Emmet, Thomas Addis, M.D., New York.
1892. Fitz, Reginald H., M.D., Boston, Massachusetts.
1895. Fletcher, Robert, M.D., Washington, D. C.
1903. Gorgas, William C., M.D., U. S. A., Washington, D. C.
1891. Jacobi, A., M.D., New York.
1895. McBurney, Charles, M.D., New York.
1886. Reeve, John C., M.D., LL.D., Dayton, Ohio.
1886. Senn, Nicholas, M.D., Chicago, Illinois.
1896. Sternberg, George M., M.D., U. S. A., Washington, D. C.
1886. Thomas, T. Gaillard, M.D., New York.
1896. Tiffany, L. McLane, M.D., Baltimore, Maryland.
1894. Warren, J. Collins, M.D., Boston, Massachusetts.
1894. Weir, Robert F., M.D., New York.
1892. Welch, William H., M.D., Baltimore, Maryland.

Foreign.

1890. Baccelli, Guido, Rome, Italy.
1877. Barnes, Robert, M.D., London, England.
1894. Brunton, Sir T. Lauder, M.D., London, England.

ELECTED

1883. Fayrer, Sir Joseph, M.D., LL.D., F.R.S., London, England.

1903. Finlay, Charles J., M.D., Havana, Cuba.

1899. Fraser, Thomas R., M.D., LL.D., F.R.C.P., F.R.S., Edinburgh, Scotland.

1883. Heath, Christopher, F.R.C.S., London, England.

1903. Horsley, Sir Victor Alexander Haden, F.R.S., London, England.

1896. Jaccoud, Prof. S., M.D., Paris, France.

1874. Jackson, J. Hughlings, M.D., London, England.

1893. von Jaksch, Rudolf, M.D., Prague, Bohemia.

1903. Kocher, Prof. Theodor, M.D., Berne, Switzerland.

1896. Leyden, Ernst, M.D., Berlin, Germany.

1877. Lord Lister, M.D., LL.D., F.R.S., London, England.

1903. von Mikulicz-Radecki, Prof. J., M.D., LL.D., Breslau, Germany.

1873. Ogle, John W., M.D., London, England.

1898. Roddick, Thomas G., M.D., Montreal, Canada.

1896. Pye-Smith, P. H., M.D., London, England.

1869. Valcourt, Th. de, M.D., Cannes, France.

CORRESPONDING MEMBERS.

1880. Carrow, Flemming, M.D., United States.

1880. Chiara, Domenico, M.D., Florence, Italy.

1886. Dey, Kanny Lall, M.D., Calcutta, India.

1885. Rendu, Jean, M.D., Lyons, France.

NECROLOGICAL LIST.

FELLOWS.

THOMAS G. MORTON,	May 20, 1903.
WILLIAM H. PARISH,	July 19, 1903.
THOMAS J. YARROW,	August 6, 1903.
CHARLES SCHÄFFER,	November 23, 1903.
SAMUEL B. HOWELL (Non-resident),	December 12, 1903.
WILLIAM H. WEBB,	December 20, 1903.

CONTENTS.

PAGE

List of Officers and Standing Committees iii
List of Presidents of the College v
List of Fellows of the College vii
List of Associate Fellows of the College xxxvii
List of Corresponding Members xxxviii
Necrological List for 1903 xxxix
Memoir of Charles Henry Burnett, A.M., M.D. By Francis R. Packard, M.D. xliii
Memoir of Francis West Lewis, M.D. By Morris J. Lewis, M.D. li

A Case of Intradural Spinal Cyst, with Operation and Recovery. By W. G. Spiller, M.D., J. H. Musser, M.D., and Edward Martin, M.D. With a Brief Report of Eleven Cases of Tumor of the Spinal Cord or Spinal Column. By William G. Spiller, M.D. 1
Exhibition of a Specimen of Abdominal Pregnancy Removed at the End of Twenty-one Months by Cœliotomy. By Charles P. Noble, M.D. 19
A New Osteoplastic Trephine. By W. Barton Hopkins, M.D. . 21
Tortuosity of the Aorta. By Joseph Sailer, M.D., and G. E. Pfahler, M.D. 24
The Ocular Complications of Variola. By Burton K. Chance, M.D. 34
A Physiological, Anatomical, and Pathological Study of the Glossopharyngeus and Vagus Nerves in a Case of Fracture of the Base of the Skull. By William G. Spiller, M.D. 40
A Case of Probable Multiple Serositis. By M. Howard Fussell, M.D., and Henry D. Jump, M.D. 55
Report of a Case of Suturing the Omentum to the Abdominal Wall (Talma) for the Relief of Ascites Due to Cirrhosis of the Liver, Twenty-one Months after Operation. By Thomas R. Neilson, M.D. 62

PAGE

Case of Cirrhosis of the Liver, with Ascites; Suture of the Omentum to the Abdominal Wall; Non-recurrence of the Ascites after Two Years. By HENRY M. FISHER, M.D., and W. W. KEEN, M.D. 67

The Relation of Neuralgic Headaches to Storms. By S. WEIR MITCHELL, M.D. 71

Successful Intraneural Infiltration of the Median and Ulnar Nerves during an Operation for Dupuytren's Contraction of the Fingers. By W. W. KEEN, M.D 75

Mercurial Nephritis. By JOHN M. SWAN, M.D. 77

Observations on the Medical Treatment of General Washington in his Illness. By JOHN BRICKELL, M.D. With Introductory Remarks, by WARD BRINTON, M.D. 90

Volvulus of the Omentum. By FRANCIS T. STEWART, M.D. . . 95

Report of a Case of Tumor of the Brain, an Endothelioma of the Dura; Operation; Recovery; Death in One Hundred and Eight Days from Recurrence of the Disease. By WILLIAM J. TAYLOR, M.D. 100

A Report of Five Cases of Tumor of the Brain, with Operation. By WILLIAM G. SPILLER, M.D., and CHARLES H. FRAZIER, M.D. 107

Exhibition of a Specimen of Intestinal Sand. Exhibited by JOHN K. MITCHELL, M.D. 152

A Case of Seborrhœa Nigricans (Black Mask of the Face). By ARTHUR VAN HARLINGEN, M.D. 154

Sarcoma of the Abdominal Wall and Probably of the Pelvic Viscera, which has Disappeared under the Use of the X-rays. By GEORGE ERETY SHOEMAKER, M.D. 158

Presentation of a Case of Unilateral Pulsating Exophthalmos. By CHARLES H. FRAZIER, M.D. 162

The Blood in Epilepsy: Experiments on Animals. (Preliminary Report.) By F. SAVARY PEARCE, M.D, and L. NAPOLEON BOSTON, A.M., M.D. 164

APPENDIX.

Abstract of the Report of the Committee on Mütter Museum, 1903 . 179

Summary of the Report of the Library Committee for 1903 . . 180

List of Papers: Section on Ophthalmology 183

List of Papers: Section on Otology and Laryngology . . . 185

List of Papers: Section on General Medicine 187

List of Papers: Section on Gynecology 189

MEMOIR OF CHARLES HENRY BURNETT, A.M., M.D.[1]

By FRANCIS R. PACKARD, M.D.

The late Charles Henry Burnett was born in Philadelphia on May 28, 1842. After receiving his preliminary education in the schools of his native city he entered Yale in 1860, and graduated in 1864. During his career at Yale he took a prominent part in the life of his class. He was a member of TheBrothers in Unity, the Glyuna Boat Club, Delta Kappa, Alpha Sigma Phi, Psi Upsilon, and Scroll and Key. In his Sophomore year he won a prize in oratory and was historian of the first division on Presentation Day. At graduation he received a dissertation appointment.

After graduating from Yale he entered the Medical Department of the University of Pennsylvania, receiving the degree of M.D. in March, 1867. He was soon after appointed resident physician in the Episcopal Hospital of Philadelphia, serving a full term in that capacity. Upon the completion of this service he went abroad, spending ten months in the laboratories and hospitals of Europe during the years 1868–69. Upon returning to Philadelphia he practised medicine for a year.

He had always had his attention strongly attracted to the study of otology, and at length decided to return to Europe and devote himself to a special study of that subject. In the pursuit of this design he gave up his practice in 1870 and went abroad, where he worked for over a year, especially in the laboratories of Helmholtz and Virchow, and in the clinic of Politzer. These three eminent men became greatly attached to the American student,

[1] Read March 4, 1903.

and in the subsequent years their friendship was continued. With Helmholtz, in particular, he established most cordial relations, conducting in his laboratory his invaluable series of investigations into the condition of the membrane of the round window during the movements of the auditory ossicles and upon the various effects of changes in intralabyrinthine pressure. This research work of Dr. Burnett placed him at once among the most eminent investigators into the physiology of hearing.

He returned to Philadelphia in April, 1872, and took up practice once more, devoting his work solely to diseases of the ear. Dr. Burnett's skill and ability quickly won recognition of his eminent talents among his professional colleagues, and he soon acquired a large and lucrative practice.

He never enjoyed robust health, and his unflagging industry was often a source of anxiety and wonder to his friends who knew how severe a physical strain it must have been for him to bear. On one occasion, during his stay abroad, he contracted a severe bronchitis, and his life-long friend, Dr. Duhring, tells me that he thinks his life was only saved by a sojourn in Southern Italy. His warm friend, the late Dr. William F. Jenks, accompanied him on this journey, and to his self-sacrifice much of its success was due.

In the latter years of his life there were but few aurists in the United States who approached him in the amount of consultation work which fell to his share. In spite of the arduous labor involved in his attention to his practice, Dr. Burnett never ceased to pursue his investigations into the scientific side of the specialty of otology. Appended to this sketch of his life will be found a bibliography, comprising as nearly as possible the numerous articles, monographs, and books which appeared from his pen.

Of literary work of large scope, we would mention particularly his *Treatise on Diseases of the Ear*, published in 1877 ; *Hearing, and How to Keep It*, one of the American Health Primers published in 1879 ; *The System of Diseases of the Ear, Nose, and Throat*, edited by him in 1893 ; and the chapters on Otology in the *American Text-book of Surgery*, 1896, in the *Encyclopædia of Diseases of Children*, edited by Keating, and in the *American*

Year-book of Medicine and Surgery. For many years Dr. Burnett edited the department of Progress of Otology in the *American Journal of the Medical Sciences*, and the author can bear personal testimony to the diligence and assiduity with which he labored.

Of the many positions which he held the following may be regarded as the most important:

In 1882 he was elected Professor of Diseases of the Ear in the Philadelphia Polyclinic Hospital and College for Graduates in Medicine, and upon his resignation of this chair some years later was made an Emeritus Professor in the institution. At various times he was Clinical Professor of Otology in the Woman's Medical College; Aural Surgeon to the Presbyterian Hospital; Consulting Aurist to the Pennsylvania Institution for the Deaf and Dumb; to the Convent of the Holy Child, Sharon Hill, Pa.; to the Baptist Orphanage; to St. Timothy's Hospital; to the West Philadelphia Hospital for Women; to the Dispensary of the Alumni of the Woman's Medical College; to the Philadelphia Hospital for Epileptics, and to the Bryn Mawr Hospital. In 1876 he was a delegate to the International Medical Congress.

Dr. Burnett was an invaluable member of the medical societies and associations to which he belonged. A faithful attendant upon the meetings of most of them, he not only read communications before them, but was an active participant in the discussions of the contributions of others. In many of these societies he held high office, and he was universally looked up to by his colleagues, and exerted a great influence upon their affairs.

I have accompanied this memoir by a list as nearly complete as possible of the societies to which he belonged, and of the offices which he held in them.

Dr. Burnett was a particularly kind friend to the younger members of the profession; he was uniformly courteous in discussions on professional topics with them, and never utilized his recognized position as an authority to override opinions which might be opposed to his own. Among his contemporaries in the profession, Dr. Burnett enjoyed a wide circle of friends; his kindly disposition and warm heart held by his side many who, in the daily rush and hurry of their labors, were unable to hold

as much intercourse with him as they wished. One of his friends, in writing to the author about him, says: "As a young man his presence and manner was dignified and genial. His personality was distinctly attractive. There was no one in his class who seemed to stand upon a higher plane of morals; his daily life being without blemishes, and beautiful in its simplicity. As a student he was earnest and patient, his natural, well-balanced, and perspicacious mind, and his early collegiate training at Yale giving him a ready ability to grasp difficult medical subjects with ease."

This outline of his youthful characteristics holds true throughout the latter years of his life. No man was more eager to grasp the later advances in otology, or more anxious to avail himself of new methods of work as they were brought forward to the notice of the profession. Although no one deprecated more than he the adoption of new-fangled notions or ideas without sufficient trial of their usefulness and safety, yet none were more anxious to avail themselves of the wonderful strides of science within the last few decades.

But a few months before his death, Dr. Burnett published, in collaboration with Drs. E. Fletcher Ingalls, of Chicago, and James E. Newcomb, of New York, a *Text-book of Diseases of the Ear, Nose, and Throat*, which may be regarded as the most advanced work of its character in the English language. The last literary work of Dr. Burnett, aside from this book, was an article on "Scarlatinous Empyema of the Anterior Superior Squamomastoid Cells," which appeared in the *American Journal of the Medical Sciences* for March, 1902, after its author had passed away. He attended the meeting of the Section on Otology and Laryngology of the College of Physicians of Philadelphia, on the evening of Wednesday, January 15th, and took an active part in the discussion of the papers read upon that occasion. A few days later he developed pneumonia, and died, after a brief illness, on January 30th, at his home in Bryn Mawr, Pa. His widow, who was Miss Anna Lawrence Davis, of Buffalo, N. Y., and four children survive him.

Dr. Burnett was a Fellow of the College of Physicians of

Philadelphia, and active in the organization of the Section on Otology and Laryngology, of which he was for several terms the chairman. He was Vice-President and subsequently President of the American Otological Society, besides serving on many of the committees of that Society. He had also served as chairman of the Section on Otology and Laryngology of the American Medical Association. He was a member of the Philadelphia County Medical Society, the Pathological Society, the Pediatric Society, and the Pennsylvania State Medical Society.

LITERARY WORKS OF CHARLES H. BURNETT, M.D.

"Some Common Forms of Diseases of the Ear," International Clinics, vol. ii. Second Series.

"Anatomy of the Membrana Tympani and Ossicles; Diseases of the Auditory Nerve." Wood's Reference Handbook.

"Hearing and How to Keep It." (American Health Primers.) Lindsay & Blakiston, 1879.

"A Treatise on Diseases of the Ear." H. C. Lea, 1877.

"An Investigation Concerning the Mechanism of the Ossicles of Hearing and the Membrane of the Round Window." Annals of Ophthalmology and Otology, 1872, vol. xi., No. 2.

"Untersuchung über die Mechanik der Gehorknochlchen und über die Membran des runden Fensters." Monatschrift für Ohrenh., July, 1871.

"Clinical Notes." Medical Times, October 5, 1872.

"A Contribution to the Comparative Distribution of the Bloodvessels in the Membrana Tympani." American Journal of the Medical Sciences, January, 1873.

"A Rare Case of Restitution of the Membrana Tympani after Fifteen Years of Disease." Medical Times, May 10, 1873.

"The External Ear, a Synthetic Resonator." Medical Times, October 4, 1873.

"The Resonant Functions of the External Ear." Medical Times, April 4, 1874.

"A Case of Movable Exudation in the Tympanic Cavity, Attended with Variable Hearing." Medical Times, October 17, 1874.

"An Objective Noise in the Ear Accompanied by Spasmodic Retraction of the Membrana Tympani and Velum Palati." Medical Times, February 13, 1875.

"An Addendum to an Article on 'Objective Noise in the Ear,'" etc. Medical Times, April 17, 1875.

"Caries of Mastoid Cells; Removal of Sequestrum; Facial Paralysis and Recovery." Medical Times, May 22, 1875.

"Living Larvæ in the Ear and the Methods for Their Destruction." Medical Times, November 27, 1875.

"Twenty Cases of the Growth of Aspergillæ in the Human Ear." American Journal of Otology, April, 1879.

"The Growth of the Fungus Aspergillus in the Human Ear." Medical Times, June 22, 1878.

"A Modification of the Blake-Wilde Aural Polypus Snare." Medical Times, January 18, 1879.

"A Case of Probable Syphilitic Deafness in One Ear." American Journal of Otology, July 1, 1881.

"Malignant Growth in the Nasopharynx, with Early Aural Symptoms." Transactions American Otological Society, 1881, vol. ii., pt. 5, pp. 479–483.

"Scented Iodoform Powders for the Ear." Medical Times, February 11, 1882.

"Aural Vertigo." Medical Times, June 3, 1882.

"Further Observations on the Usefulness of Chinoline Salicylate in Otorrhœa." American Journal of Otology, October, 1882.

"On the Growth of Aspergillus in the Ear, with a Case of the Rare Form of the Parasite, the Aspergillus Glaucus." Medical News, November 4, 1882.

During the eighties he wrote "Reports on the Progress of Otology" for the Medical Times.

"Is the Chorda Tympani a Separate and Distinct Cranial Nerve?" Medical Times, February 24, 1883.

"The Use of Resorcin and Chinoline Salicylate in Otorrhœa." Medical Times, November 17, 1883.

"Clinical Report of a Case of Recurrent Dropsy of the Left Middle Ear, Complicated after Eight Years' Duration by an Acute Attack of Monocular Optic Neuritis (Choked Disk) on the Same Side; Followed by General Tabetic Symptoms." By C. H. Burnett and C. A. Oliver. American Journal of the Medical Sciences, January, 1884.

"Reflex Aural Phenomena from Nasopharyngeal Catarrh; Objective Noises in and from the Ear." Medical News, July 26, 1884.

"The Relation between Chronic Otitis Media Catarrhalis and Chronic Rhinitis." Medical News, July 25, 1885.

"Hernial Protrusion of the Mucous Membrane of the Tympanic Cavity through the Membrana Tympani in Some Cases of Chronic Purulent Otitis Media." Medical News, October 24, 1885.

"Chronic Purulent Otorrhœa: its Nature and Treatment." Medical News, October 30, 1886.

"The Frequent Dependence of Disease of the Ear upon Catarrhal Disease of the Nose." Medical News, July 10, 1886.

"Ear Trumpets." College of Physicians, April 6, 1887.

"Aural Vertigo Relieved by Operation." Polyclinic, Philadelphia, August, 1888.

"Chronic Purulent Inflammation of Tympanic Attic." New York Medical Journal, November 24, 1888.

"Aspergillus in the Human Ear." Medical and Surgical Reporter, November 16, 1889.

"A Purulent Discharge from the Ear Cured by Excision of Membrana Tympani and Malleus." Medical News, November 2, 1889.

"Permanently Good Results of Excision of the Membrane Tympani and Malleus in a Case of Chronic Aural Vertigo; also in a Case af Chronic Suppuration of the Tympani Attic." Medical News, August 16, 1890.

"Excision of Membrana Tympani, Malleus and Incus as a Means of Treatment in Otitis Media Catarrhalis Chronica, and in Otitis Purulenta Chronica." Medical News, September 26, 1891.

"On the Relief of Chronic Catarrhal Deafness by Excision of the Membrana Tympani and the Two Larger Ossicula" Medical News, July 4, 1891.

"Excision of the Membrana Tympani and Necrotic Malleus in Four Cases of Chronic Suppurative Otitis Media." Annals of Ophthalmology and Otology, January, 1892.

"Partial Myringectomy and Removal of the Incus and Stapes." Medical News, May 13, 1893.

"The Surgical Treatment of Chronic Tympanic Vertigo, often Miscalled Ménière's Disease." Medical News, September 30, 1893.

"The Relief of Chronic Deafness, Tinnitus Aurium, and Vertigo by Removal of the Incus and Stapes." Journal of the American Medical Association, November 18, 1893.

"Three Cases of Chronic Tinnitus Aurium and Tympanic Vertigo Relieved by Removal of the Incus." Medical News, April 28, 1894.

"Surgical Treatment of Chronic Otorrhœa." Journal of the American Medical Association, October 13, 1894.

"The Preventiou of Mastoid Empyema." Medical News, August 17, 1895.

"Otitic Brain Abscess and Aural Vertigo." University Medical Magazine, March, 1896.

"Chronic Tympanic Vertigo." Polyclinic, Philadelphia, May 2, 1896.

"A Foreign Body in the Ear." Polyclinic, Philadelphia, October 2, 1897.

"A Foreign Body in the Ear." Polyclinic, Philadelphia, December, 11, 1897.

"Intratympanic Surgery, Especially in Chronic Purulent Otitis Media." International Medical Magazine, December, 1897.

"Chronic Tympanic Vertigo: its Cure by Tympanotomy and Removal of the Incus." Pennsylvania Medical Journal, February, 1898.

"Four Recent Cases of Excision of the Malleus and Incus in Chronic Purulent Otitis Media." Philadelphia Medical Journal, February 26, 1898.

"Intratympanic Surgery, Especially in Chronic Purulent Otitis Media." Journal of the American Medical Association, March 19, 1898.

"A Case of Acute Mastoiditis; Perforation of the Medial Plate of the Process and Consecutive Abscess in the Neck." University Medical Magazine, February, 1899.

"Further Considerations of the Mechanism of Ear Vertigo and its Relief by Removal of the Incus." American Journal of the Medical Sciences, April, 1899.

"A Modified Siegle's Pneumatic Aural Speculum." Journal of the American Medical Association, June 3, 1899.

"Pneumomassage of the External Auditory Canal Compared with Inflation of the Tympanum." University Medical Magazine, August, 1899.

"A Case of Suspected Typhoid Fever Shown to be Acute Catarrhal Otitis Media." Philadelphia Medical Journal, March 3, 1900.

"Grave Diseases in Young Children often Due to Latent and Unsuspected Inflammation of the Middle Ear." Pennsylvania Medical Journal, May, 1900.

"Chronic Ear Vertigo (Ménière's Disease): its Mechanism and Surgical Treatment." Philadelphia Medical Journal, September 22, 1900.

"The Arrest of Progressive Hardness of Hearing Tinnitus Aurium, and Ear Vertigo by Incudectomy." Virginia Medical Semi-Monthly, June 21, 1901.

"Incudectomy in the Treatment of Progressive Hardness of Hearing, Tinnitus and Aural Vertigo." Pennsylvania Medical Journal, October, 1901.

"Scarlatinous Empyema of the Anterior Superior Squamomastoid Cells." American Journal of the Medical Sciences, March, 1902.

MEMOIR OF FRANCIS WEST LEWIS, M.D.[1]

By MORRIS J. LEWIS, M.D.

Francis West Lewis, the subject of this memoir, was born in Philadelphia on June 17, 1825. He was the son of Mordecai D. Lewis, a well-known merchant of this city at that time, and Sarah West.

At the age of seven years he was sent to A. Bronson Alcott's school in Germantown. Alcott was called to Germantown as a teacher by those dissatisfied with the prevailing methods of teaching, and taught for a comparatively few years only. His school was for the very young, and his method of education most strange, being largely directed toward fostering the imagination of his young pupils.

Dr. Owen J. Wister, a Fellow of this College, now dead, went to this school at that time. Subsequently Dr. Lewis' education was principally received at boarding-school, finishing his primary education at Bishop Hopkins' Institution at Burlington, Vermont.

In 1839, at the age of fourteen years, he entered the Academical Department of the University of Pennsylvania and, after a four-years' course, graduated. The choice of a profession gave him much anxiety; having no financial tastes, and feeling that he was unfitted for the study and practice of law, he finally decided upon medicine, and chose as a preceptor the well-known Dr. Mütter, matriculating at the Jefferson Medical College in 1843. A marked friendship sprang up between preceptor and pupil, and before his graduation he was asked by Dr. Mütter to

[1] Read April 1, 1903.

accompany him on a pleasure trip abroad of several months' duration.

He graduated in medicine in 1846, and very soon went abroad again for two years, spending a portion of the first year in Dublin, studying under Sir William Wilde the oculist, the father of Oscar Wilde, and the latter part of the year in London. This was the dreadful summer of 1847, the year of the epidemic of typhus fever in Ireland and of the famine.

His second year abroad was spent in Paris during the revolution of 1848, much of his time being occupied with work in the wards of the Salpêtrière Hospital. Upon returning to Philadelphia, in the latter part of 1848, he was soon fortunate enough to be elected Resident Physician to the Pennsylvania Hospital, serving in this capacity in 1849 and 1850. Soon after leaving the hospital he opened a private office, and from 1850 to 1854 he worked in connection with the Philadelphia Dispensary. Dr. Lewis soon found that his health unfitted him for the strain of practice, which was entirely among the poor, as he refused to attend the well-to-do, and frequent voyages abroad were subsequently undertaken to regain his strength.

During the Civil War he was deeply interested in organizing relief, and held several military medical positions, among these Surgeon to Satterlee Military Hospital in Philadelphia, and a short time before the battle of Gettysburg he was in charge for a few months of a temporary military hospital in Harrisburg. In 1864 he also held the position of Surgeon to St. Joseph's Hospital.

He decided to give up all practice in 1865, and again went abroad, and on his return, in 1866, he refused all attendance on patients, as he considered that he was not keeping abreast of the times, and removed his sign from his window, although he still interested himself in professional work in connection with the Children's Hospital until 1868, as he fortunately was so situated financially that he could bend all his energies toward philanthropy.

While in London in 1847 he became much interested in children after visiting the Children's Hospital on Great Ormond Street, and this interest was still further fostered during his resi-

dentship in the Pennsylvania Hospital, where he thought that these little patients were at a great disadvantage, medically and morally, in such a large general institution.

His long-cherished idea of a hospital solely for the treatment of children grew, and during the next few years finally took shape in his mind, and in 1855 he, in connection with Drs. R. A. F. Penrose and Thomas Hewson Bache, organized the Children's Hospital of Philadelphia.

This hospital was opened November 23, 1855, in a small house on Blight Street, near Broad and Pine Streets, and furnished with twelve beds, and notwithstanding this modest beginning, the amount of work done during the first year of its existence and the relief afforded to sick and injured children proved the wisdom of the enterprise started by Dr. Lewis and his collaborators. From the very incipiency of this hospital until the day of his death Dr. Lewis was identified with its welfare, being Physician to the hospital until 1868; Secretary of the Board of Managers, of which he was a most important member, from 1868 to 1895, and President of the Board from that date until his death.

Scarcely a day passed, regardless of the weather, except during his summer vacations, that did not find Dr. Lewis at the hospital investigating the minutest detail of its management, planning additions and improvements, and looking after the welfare of his little friends, who on his appearance in the wards welcomed him with shouts of joy.

When the hospital was smaller, and he could watch each case more easily, this interest did not cease with their discharge, for he watched the subsequent career of many of them, writing to them and receiving letters and visits of inquiry from them after they had arrived at woman's and man's estate and had children of their own.

The present hospital on Twenty-second Street, growing by successive steps from the modest beginning on Blight Street, through rapidly growing stages up to the present well-ordered institution, is mainly owing to the indefatigable watchfulness and care of Dr. Lewis, its principal founder, aided by his great generosity, in which he was always ably seconded by his sisters. Truly his

death was a severe blow to this hospital, which has been, not inaptly, called his "Child."

Several times after the hospital was well under way Dr. Lewis' heart misgave him, as he wondered whether he was acting wisely in being instrumental in saving the lives of delicate infants and children, for the thought arose in his mind that it might possibly be better to let them die when young rather than to save them for greater suffering later, and possibly lives of poverty, invalidism, and crime.

Several times later in his life his mind must have occasionally slipped back into this same channel of thought to prompt him to announce the death of an infant in the hospital in the words "another infant cherubized."

Dr. Lewis' tastes were varied; he was very facile with his pen and pencil—in fact, quite an artist. He was imbued with a spirit of fun, which manifested itself early in life, and later found relief in humorous sketches and caricature. He was extremely fond of desultory scientific research, although he added but little to the fund of literature. A single pamphlet, *Notes on New and Rare Species of Diatomaceæ of the United States Seaboard*, written and illustrated by him, and which was published in 1861, is the sole representative of his work on the shelves of the College Library.

A weakness of the eyes appearing at this time prevented further work in this direction with the microscope. Subsequently he took up the study of botany and fungi, and was much interested in these subjects all the latter years of his life, amusing himself during his later summer vacations by coloring plates of flowers and fungi from nature.

He was a voluminous reader and took particular pleasure in poetry. During his numerous trips abroad he made the best of the opportunities which offered themselves of exercising his artistic taste, by making a fine and very valuable collection of Oriental china, glass, and bronzes, which for a time graced his home at 2016 Spruce Street, but which have been donated to the School of Industrial Art and placed in Memorial Hall; most of these were gathered during the later years of his life, and form a valuable collection for students of art. The fine arts also interested

him, and his knowledge of the subject enabled him to make an intelligent and valuable collection of paintings and casts, many of which were presented to the Pennsylvania Academy of the Fine Arts, of which he was for many years an efficient and earnest member of the Board of Directors. For a number of years he was the Chairman of its Committee on Exhibitions.

As one of the Directors of the House of Refuge his philanthropic leanings found ample scope, his medical training making him an especially valuable member of the Board of this institution, and the deep personal interest that he manifested in the boys and girls had much influence for good in moulding their characters for the future. He became a Manager in 1881 and, with the exception of a single year, served in this capacity until the day of his death.

As President of the Seventh Ward Charity Organization he was on its Relief Committee, and no one took more interest in the cases than he, visiting them, and when necessary securing the attendance of the District Physicians, seeing to the transfer of the proper cases to the various hospitals, and generally superintending relief.

In addition to the positions already mentioned he had been Manager of the Pennsylvania Institution for the Instruction of the Blind, and held at the time of his death the following positions: Fellow of the College of Physicians of Philadelphia since 1855; Director of the Academy of Natural Sciences; Member of the American Philosophical Society; Director of the Zoological Society; Director of the Philadelphia Library, and Member of the Historical Society of Pennsylvania.

Modest and unassuming, and shrinking from all publicity and notoriety, none but those who had the good fortune of knowing him intimately and of being associated with him in his daily life, can form a just appreciation of his worth and the good he did in his day and generation. Liberal and unostentatious, the full extent of his beneficence will never be known. Zealous in the discharge of his duties, it is worthy of note that notwithstanding the severity of the weather on February 21, 1902, the day of the severe blizzard, Dr. Lewis decided to brave the fury of the

elements to attend a meeting of the Seventh Ward Charity Organization, of which he was President. A chill was the result of this exposure; pneumonia soon followed, and on March 2d his illness proved fatal.

Dr. Lewis was never married, and is survived by two sisters.

It may be truly said of him that he obeyed the Scriptural injunction:

"When thou doest alms let not thy left hand know what thy right hand doeth."

A CASE OF INTRADURAL SPINAL CYST, WITH OPERATION AND RECOVERY.[1]

By W. G. SPILLER, M.D., J. H. MUSSER, M.D.,

AND

EDWARD MARTIN, M.D.

With a Brief Report of Eleven Cases of Tumor of the Spinal Cord or Spinal Column.

By WILLIAM G. SPILLER, M.D.

A. B., a woman, aged twenty-six years, single, in 1898 or 1899 suffered from pain at night in the left side of the sacrum. This pain would awaken her, but by putting an extra pillow under her head she would get relief and be able to go to sleep again. The pain was felt about two nights in a week, but was not present during the day. The suffering could not have been severe, as in most accounts of her condition she made no mention of pain previous to 1901. In April, 1901, she began to have sharp pain, like that of toothache, extending down the front of the left thigh as far as the knee, but never beyond, and confined to the left lower limb, and felt only at night. The pain would usually awaken her about 2 or 3 A.M., and she was able to obtain relief only by sitting up in bed. In October, 1901, the pain still seemed to start in the same spot, and extended across her back. She remained in bed until January, 1902, and was treated for sciatica. The pain still was felt only at night. On January 2, 1902, she came to the Presbyterian Hospital under our observa-

[1] Read January 7, 1903.

tion. She remained there seven weeks, and the pain was less severe during her stay in the hospital. During the two weeks following her arrival in Philadelphia she was obstinately constipated, but she was then given an iodide and her bowels became loose. An examination was made on February 8, 1902. The pain was then felt in the anterior part of the left thigh, over each sacrosciatic foramen, and in the lumbar region on both sides of the spinal column. It had changed somewhat in character, and was duller. The patellar reflex on each side was exaggerated, and patellar clonus was present on each side, but ankle clonus was not obtained on either side. Achilles-jerk was prompt. Babinski's reflex was not obtained on the right side, and the toes on this side were flexed from irritation of the sole of the foot, but irritation of the left sole caused slight extension of all the toes except the big toe, the latter not being moved. No objective sensory disturbances were found, and there was no pain on pressure over the spinal column, over the sacrosciatica foramina, or elsewhere. She had a slight scoliosis. The tendon reflexes of the upper limbs were prompt, but not exaggerated, and the upper limbs were not implicated. The urinary examination was normal, except that the specific gravity was high. From the results of this examination the opinion was expressed that the case was probably one of tumor on the spinal cord. Pott's disease and syphilis were considered, but the symptoms were regarded as more indicative of tumor.

On February 11, 1902, the patient was seen again. Patellar clonus or ankle clonus was not obtained on either side. The patellar reflex was very prompt on each side. Babinski's reflex was not distinct on either side. No objective sensory disturbances were obtained anywhere. Walking increased the pain. She had no girdle sensation. She expressed the opinion that the pain had become more severe, because during the summer of 1901 she danced much, and sat out in the dampness after dancing.

Miss A. B. returned home February 15, 1902, and was comparatively comfortable for two or three weeks; then the pain became more severe, and began to be felt during the day. She went to Brooklyn and was treated during nine weeks by elec-

tricity, which made her much worse, and she then returned home. At this time the pain was felt across the lower part of her back, down the front of her left thigh, down the back of the left lower limb, and in both hips, but more in the left. She now noticed numbness in the toes of the left foot, extending on to the dorsum of the foot, and the pain was becoming even more severe than it had been.

She was examined again on June 10, 1902, and the notes made then are as follows:

The pain has become much more severe since last January, and is felt while the patient is lying down. It is deep in the hip-joint, and feels as though something were pressing on a nerve. The pain is chiefly down the front of the left thigh, and only occasionally along the course of the sciatic nerve. It is felt at the sacrosciatic notch, and low in the lumbar region on both sides, but chiefly on the left side. It has been felt in the left lumbar region at a time when it was not felt in the right lumbar region, but never in the right lumbar region without being felt in the left lumbar region. No muscular atrophy or weakness of either lower limb has developed. The pain has never been felt in the right lower limb. Since last January constipation has been pronounced, and the patient has not during this time been on a special diet or confined to bed. Sometimes, when the pain is severe in the left lower limb, the leg will give way if the patient is standing. The patellar reflex is exaggerated, and equally so on the two sides, but patellar clonus cannot be obtained on either side. The Achilles-jerk is present on each side, equal on the two sides, and about normal. Babinski's reflex is not obtained on either side. Tactile sensation is normal in each lower limb. No bladder symptoms are present. No tenderness is felt on pressure over any of the nerves. The patient has noticed once or twice that pressure over the vertebral column of the lumbar region caused a shooting pain in the back of the left thigh. Lasègue's sign—*i. e.*, pain in flexion of the thigh on the abdomen with the leg extended—seems to be present on each side.

She came to the University Hospital June 26, 1902, and notes made at that date are as follows: Since the last examination,

June 10th, the pain has become much more intense, and has on several occasions been felt in the right lower limb, in the anterior part of the thigh, and it did not extend below the knee. She has not felt any pain in the posterior part of the right thigh. The pain has become intense in the right lumbar and sacral regions since the examination on June 10th, and is almost as intense on the right side as on the left. Constipation has not increased, possibly because the patient has been taking magnesium. She has no girdle sensation, and has not felt any loss of motor power in the lower limbs. During the last two or three days she has had considerable pain in the left inguinal region. Menstruation has persisted during her disease. While being examined the pain is so intense that she is unable to sit still, and squirms from side to side in her chair in the hope of getting relief. Tactile sensation is more acute in the right lower limb below the knee than in the corresponding part of the left lower limb. She complains of numbness in the left foot, and both feet are cold. The patellar reflex on the right side is exaggerated, but is not obtained on the left side even by reinforcement. Patellar clonus and Babinski's reflex are not obtained on either side. Achilles-jerk is present on the right side, but absent on the left side. Ankle clonus is not obtained. Attempts to extend passively the right leg and thigh cause great pain in the lumbar region. Standing gives some relief. Gait is peculiar only because of the movements caused by pain. The upper limbs are not affected. Turning the head passively from side to side or coughing causes pain in the lumbar region.

On June 28th the left foot felt dead; the paræsthesia did not extend above the ankle, and the foot was also described as if asleep. Resistance to passive movement in the flexors of the left thigh was distinctly less than in the right thigh, but resistance to passive movement in the muscles of the left leg seemed to be as good as in the right leg. Since the day previous the left lower limb gave way when the patient stood. When walking she spared the left lower limb, but would stand on either limb alone, and yet the left limb soon gave way.

On June 30th the flexor muscles of the left thigh were very

weak. The flexor muscles of the right thigh were also affected, but not so much so as those of the left thigh. The extensors of each leg were not weak. The patellar reflex was lost on each side. An operation was decided upon, and done on this day.

As the pain had been felt chiefly in the distribution of the left third and fourth lumbar roots (see Fig. 1), it was decided to remove the laminæ of the first, second, and third lumbar vertebræ, as in this way the whole of the third and the greater part of the second and fourth lumbar roots would be exposed. The operation was done by Dr. Edward Martin, and his report is here given:

Though the operation of laminectomy often fails in accomplishing the purpose for which it is attempted, it is one which, if performed in a cleanly manner, is so simple, rapid, and safe, and apparently so devoid of crippling after-effects, that the conservative attitude of the profession toward it is somewhat surprising. In the case reported by Drs. Spiller and Musser there seemed every reason for believing that a pressure lesion would be found in or upon the cord.

No attempt was made to turn back the osteoplastic flap. An incision was made in the middle line, and carried close to the bone on either side of the spinous process of the last dorsal and four lumbar vertebræ until the site of the laminæ was reached. No attempt was made to check the bleeding with hæmostats, the wounds, as soon as made, being tightly stuffed with gauze. This packing was kept up at all points excepting that at which the periosteal elevator was engaged in stripping up the soft parts. The removal of the spinous processes of the last dorsal vertebra gave free access to the upper lumbar laminæ, which were rapidly divided by means of a cutting drill attached to an electro-surgical engine. This instrument greatly facilitated this part of the work, which, in the absence of such a tool, should be accomplished by a long pair of bone-cutting forceps. The veins lying in the layer of fat which covered the dura mater were much less prominent than usual. On splitting the dura a cyst about one inch in length and half an inch wide presented itself at once, with walls of flimsy consistence, so diaphanous and thin that in opening this cyst to

Fig. 1.

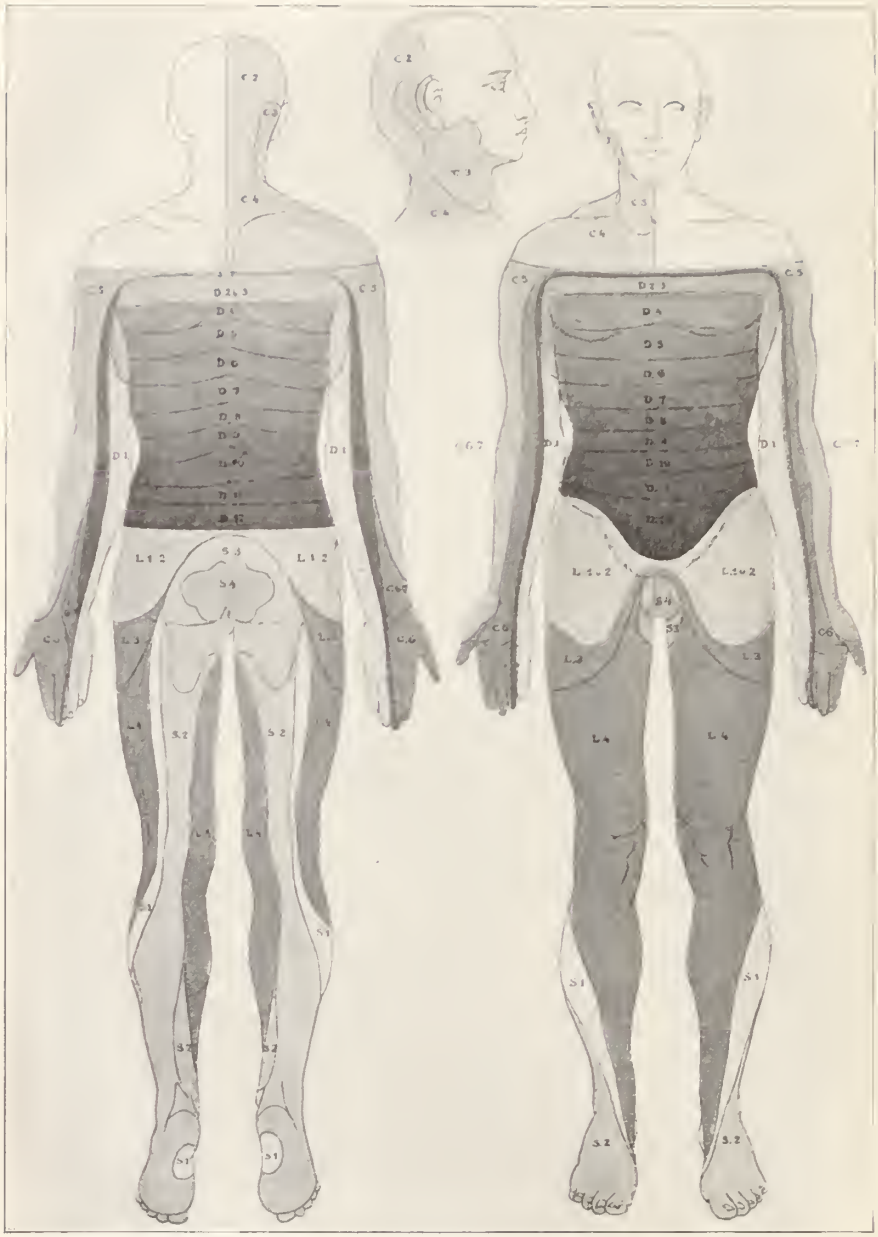

Diagram showing distribution of the sensory roots, from Edinger's "Vorlesungen über den Bau der nervösen Centralorgane." Sixth edition.

the pia these walls could no longer be identified. The fluid evacuated was clear, and after emptying the cyst there was a forcible continuous gush of cerebrospinal fluid, of about five or six ounces, indicating unusual intradural pressure. The escape of the fluid caused clonic spasms. Because of this the dura was completely closed by suture, and the external wound was sewed up without drainage. The spinous processes and the laminæ of the first, second, and third lumbar vertebræ were removed. The exposure of the lower part of the cord and the cauda equina was perfectly satisfactory.

There was very little bleeding from the operation, incident to the fact that pressure was carefully employed, and no effort was made to clamp the vessels by the hæmostats.

In the ventral decubitus chosen for operation the breathing was not interfered with, since sand-bags were placed under the shoulders and beneath the bony pelvis, thus supporting the weight on these parts of the body and preventing the abdominal viscera from being thrust up against the diaphragm. This, I believe, an important matter. Free diaphragmatic motion should also be secured in these spinal operations.

Notes made on July 10th are as follows: Miss A. B. had no pain in the left lower limb after the operation until July 5th, but during this period she had pain at the end of the spine and in the rectum. This was supposed to be from the operation. The numbness in the left foot began to lessen four or five days ago, but is still present. On July 5th she began to have attacks of severe pain, confined to the anterior part of each thigh and exactly in the middle of each thigh; in the right limb this pain extends as far as the foot; in the left limb the pain extends only as far as the knee. She began at the same time to have severe headache on the left side only, the pain beginning in the neck and shooting up into the head. Patellar reflex and Achilles-jerk are not obtained on either side. Resistance to passive movements in the flexor muscles of each thigh is not very great.

On July 14th the patellar reflex was obtained on the right side, but not on the left.

By July 26th the numbness in the left foot had become much

less than it was before the operation. She still had some pain in the front of the left thigh. Resistance to passive movements was somewhat diminished in the left lower limb, but was normal in the right lower limb. The bowels and bladder were in good condition.

On August 21, 1902, Miss A. B. still had some pain across the back near the wound. Since the operation she has had no pain near the left sacrosciatic foramen, where the pain was so intense before the operation. The pain occasionally shoots down the front of the left thigh as far as the knee, but there is no pain in the thigh on pressure, and she has no pain during the daytime. The pain in the back has been getting less severe and less frequent since the operation. She can stand well on her left limb alone, and her gait is normal. The right lower limb is normal and entirely free from pain. Resistance to passive movements is about normal in the left lower limb. Patellar reflex is not obtained on the left side, but is normal on the right side. Babinski's reflex is not present on the left side, and the left Achilles-reflex is absent. Sensation for pain and touch is normal in the left lower limb. She returned to her home on August 23, 1902.

At the time this report is published Miss A. B. is in excellent health. She has some pain at times down the front of the left thigh, but only after walking or getting excited. She has no pain in the thigh when she is quiet. As she has at times had hysterical manifestations, the pain she now has may be hysterical, especially as it appears when she gets excited. She may be said to be cured, although of course we cannot say with certainty that no further pathological condition exists.

The question has arisen whether the cyst found was of parasitic nature. It was probably not a parasitic cyst.

H. Schlesinger,[1] in his monograph on *Tumors of the Spinal Cord and Vertebræ*, remarks that parasitic cysts within the vertebral canal are either cysticerci or echinococcus cysts, and the latter occur about five times more frequently than the former, and yet the cysticerci are more likely to be overlooked, because they are

[1] Beiträge zur klinik der Rückenmarks und Wirbeltumoren, Jena, 1898, p. 51.

smaller and not so numerous in any one case. Cysticerci have never been found within the vertebral canal unless they existed elsewhere in the body, especially in the brain and its membranes. They occur as round or oval cysts, or much more rarely as cysts with processes—cysticercus racemosus—as in the cases of Hirt and Richter. In these two cases numerous cysts were found within the spinal dura. Of seven other cases of cysticercus of the vertebral canal six were examined critically by Schlesinger. (Cases of Westphal, Hebold, Walton, Gerhardt, Rokitansky, Gribbohm, Alcalai.) In seven of the eight cases the cysts were intradural, so that this variety is much more frequently intradural than extradural. As many as seven cysts have been found within the vertebral canal in one case, but there may be only one within the vertebral canal. The cysts are frequently on the ventral side of the cord, and sometimes within the substance of the cord. Usually they are not very large, the size of a pea, and rarely as large as a bean. They are sometimes free, sometimes attached to the spinal cord.

Schlesinger collected forty-four cases of echinococcus cysts of the spinal cord and its membranes. When the parasite is intradural it is round or oval and compresses the cord. The dura is usually not implicated and merely distended. They are more frequently extradural than intradural. Of the forty-four cases only five were intradural, so that the extradural location is seven times more frequent than the intradural. The cysts are usually unilocular, and frequently multiple, but in the cases of Ransom, Anderson, and Cruveilhier only one cyst was found in each case, and in these the cysts were extradural. The cysts are usually on the posterior surface of the spinal cord. The thoracic region is the portion of the vertebral canal most frequently affected, at least in the extradural variety. The cysts may be the size of a pea, the size of a walnut, or even larger, and their contents are clear, and they often contain daughter cysts. The rapidity of growth of these cysts varies greatly, and years may pass after symptoms have appeared before the symptoms become very serious.

A BRIEF REPORT OF ELEVEN CASES OF TUMOR OF THE SPINAL CORD OR SPINAL COLUMN.

Tumor of the spinal cord, either extradural or intradural, is a subject of interest alike to the physician and the surgeon, and at present it seems to be attracting unusual attention. The two papers by Oppenheim,[1] the paper by Collins,[2] and the paper by Putnam, Krauss and Park,[3] have been published so recently that it is unnecessary to refer further to the literature. I shall report briefly my own exprience as regards spinal tumors. At least eleven cases of tumor of the spinal cord or vertebræ with operation or necropsy have come under my observation; some of these were seen in the service of others and some were cases of my own.

The first was in the service of Dejerine[4] at the Salpêtrière, in 1895, and presented the symptoms of compression of the cauda equina. Operation was attempted by Chipault, but was unsuccessful, and the patient died three hours after the completion of the operation. A round-cell sarcoma of the cauda equina was found, but it could not be removed. The case was reported by Dejerine and myself.

The second case was also in the service of Dejerine at the Salpêtrière. A small intradural osteoma confined to one sacral root was a chance finding at the necropsy. So far as I know no symptoms of tumor had been observed during the life of the patient. The tumor was so small that it probably did not give rise to any symptoms. Had it done so it probably would have caused severe pain in a very limited area, and the correct diagnosis would have been extremely difficult. It is important to remember that a tumor confined to one root may exist, and this possibility should be in our minds when we meet with a case of intense and persisting pain in one nerve root territory. The spinal cord in this case of osteoma of one root was examined by me, but secondary

[1] Berliner klin. Wochenschrift, 1902, Nos. 2 and 39.

[2] Medical Record, December 6, 1902, p. 882.

[3] American Journal of the Medical Sciences, January, 1903, p. 1.

[4] Dejerine and Spiller. Comptes-rendus des Séances de la Soc. de Biologie, 1895.

degeneration could not be detected. The report of this case has never been published.

The third case was also in the service of Dejerine, and the tumor, a lipoma of the filum terminale, was likewise a chance finding at necropsy. It had caused no symptoms. A lipoma of the central nervous system is a very rare tumor, and I[1] believe there is no other case of lipoma of the filum terminale on record, although Gowers[2] has reported a lipoma of the conus medullaris. A tumor of the filum, as in a case of glioma of this portion of the spinal cord reported by Lachmann, may compress the spinal roots nearest to it—*i. e.*, the lower sacral—which innervate the bladder. Such a tumor may cause disturbance of function only of the bladder, without motor or sensory symptoms in the lower limbs, and in Lachmann's[3] case the mistaken diagnosis of carcinoma of the bladder was made.

The fourth case was seen in the service of F. Kraus, in Vienna. A sarcoma of the vertebræ compressing the spinal cord was found. No report of this case has been published so far as I know. Operation was not attempted.

The fifth case was a patient of Dercum,[4] and the case was reported in full by him. Quadriplegia finally developed. A chondrosarcoma situated at the foramen magnum was found. I merely saw the patient once and assisted in the necropsy and prepared the microscopic specimens.

The sixth case was in my service at the Polyclinic Hospital, and has not been published.

A woman, aged forty-eight years, in November, 1898, began to have severe pain in the back of the neck and back of the head, and this pain was attributed by her to taking cold. In December, 1898, the pain became more severe after an attack of grippe. When seen by me on October 14, 1899, the pain was felt in the back of the neck and head, and radiated into the shoulders and down each upper limb half-way to the elbow. Sight had

[1] Spiller. Journal of Nervous and Mental Disease, 1899.

[2] Transactions of the Pathological Society of London, 1876, vol. xxvii.

[3] Archiv für Psychiatrie, 1882, vol. xiii. p. 50.

[4] Journal of Nervous and Mental Disease, August, 1899.

been failing for three years. She had been obstinately constipated. The movements of the head in all directions were much restricted, but she had free use of the upper and lower limbs. The patellar reflex was prompt on each side. Pressure upon the head downward caused pain in the back of the neck. The gait was slow but not ataxic. Movements of the upper limbs were not ataxic. High-grade choked disk was found on each side. She was admitted to the hospital on October 23, 1899. Vomiting began soon after she entered the hospital, and became frequent. Vision gradually was lost. Sense of smell was lost when tested on November 9, 1899, and on this date her hearing was good. The first attack of unconsciousness was observed November 19, 1899, and these attacks soon became frequent, and lasted from a few minutes to half an hour or more, and during the attacks the heart-beat became weak and sometimes rapid. Weakness of the shoulder and upper arm muscles soon developed, and at a time when the hands could not be moved at the wrists the movements of the fingers was fair, but later the fingers could not be moved voluntarily. Pain preceded this paralysis for months. The patellar reflexes were never very distinctly exaggerated, and on several examinations were weak or even absent. The only cranial nerves implicated were the optic and to a very slight extent the right hypoglossal.

Hearing may have been affected late in the disease. The facial nerve on each side functionated normally. Babinski's reflex was not obtained until the day before the patient's death, and was soon exhausted. Dizziness was complained of on March 3d. The upper limbs were never spastic, and when paralyzed the limbs were very flaccid. Objective sensation was not found disturbed in the upper limbs until May 2d. The sensation of constriction passed downward gradually from the neck to the chest. Slight nystagmus on lateral movement was observed April 4th. No paralysis of the external ocular muscles existed. On May 9th weakness in the lower limbs was intense, and much pain was felt in the left lower limb. Death occurred on May 17, 1900. Extension of the head was employed for some time after the patient entered the hospital, and at first seemed to be of benefit. At a time

when the patient could walk without difficulty no ataxia of gait was observed, but no note is made of her gait later than October 23d. The attacks of unconsciousness became so frequent and were so serious in the cardiac involvement, and the patient disliked so

Fig. 2

Flat tumor (*b*) covering the medulla oblongata and the left side of the pons.

much to be disturbed, that the gait was not tested in the later stage of the disease.

I made a diagnosis in this case of tumor of the upper cervical cord near the foramen magnum, and during many months I watched the paralysis passing from the muscles of the shoulder to the fore-

Fig. 3.

The tumor shown in Fig. 2 extends downward (*c*) on one side of the cervical cord. At *d* a smaller tumor is found.

arm and hands, until finally the lower limbs became paralyzed. The tumor was believed to be extramedullary, but operation was not attempted on account of the position of the growth. A necropsy was obtained, and an intradural tumor, that probably should be classed under the sarcomata, although it has some peculiarities, was found compressing the upper cervical cord and medulla oblongata, and extending on to the pons. A small tumor was found in the lower thoracic region. (See Figs. 2 and 3.)

The seventh case was not under my care, but was one in which the necropsy was made by me. An intradural fibroma of the lower cervical cord was found, and could have been removed easily if operation had been done. (See Fig. 4.)

Fig. 4.

Intradural fibroma compressing the cervical cord.

The eighth case was one in my service at the Philadelphia Hospital. The man was completely paralyzed when he came under my care, and his previous condition could not be fully determined. A sarcoma within the spinal cord in the thoracic region and entirely destroying the cord at this portion was found.

The ninth case was seen with Dr. Van Gasken at the Woman's Hospital of Pennsylvania. The patient, a woman, had been

well until one year after marriage. Three days after the birth of her child she had severe headache in the occipital region. After the headache ceased she was dizzy, and had diplopia from external ocular muscle palsy. The lower limbs gradually became stiff and weak, until finally they became completely paralyzed and control over bladder and rectum was lost. Examination of the eyes showed paralysis of both external recti muscles, with paralysis of one of the oblique muscles, but the patient's condition made it impossible to determine which one. There was marked swelling of the optic disks, with hazy outlines, and the vessels were tortuous. I saw the patient about five months after the birth of her child. The head was slightly retracted and the neck was a little stiff, and she moved the head from side to side with difficulty. The headache was still severe. The upper limbs were moved voluntarily and freely, and sensation in the upper limbs was normal. The lower limbs were completely paralyzed and the patellar reflex was much diminished on each side. A slight ankle clonus was present on the right side, and Babinski's reflex was present on each side. All forms of sensation were lost in the lower limbs. Kernig's sign was present on each side. The patient died about two months after my examination. Operation was not advised in this case, because the process was evidently a diffuse one, and the symptoms were suggestive of meningitis, especially as they developed one year after marriage and a few days after the birth of a child. Syphilis and septic infection were considered, but the duration of the process for five months seemed to make a diagnosis of purulent meningitis improbable. Sarcomatosis of the entire spinal pia was found, with a large sarcoma on the pons and another within the spinal cord in the thoracic region. The sarcomatosis of the pia resembled meningitis pathologically as well as clinically.

The tenth case was one of multiple carcinoma of the vertebræ, with compression of the spinal cord. The patient was in my service at the Philadelphia Hospital. She was weak in all four limbs, especially in the lower, and suffered much pain. The muscles were greatly atrophied.

The eleventh case is the one reported in this paper, in which

a cyst and not a tumor was found, but the case may be classed with those of spinal tumor, as the symptoms were the same.

These eleven cases are not the only cases of spinal tumor that I have seen, but they are sufficient for statistical purposes. Only three were cases in which operation could have been attempted justifiably, and these were cases one, seven, and eleven, and in the first operation hastened death; in the seventh operation was not attempted, and in the eleventh very great benefit was obtained by operation.

The cases to which I have referred are interesting in connection with the recent paper by Collins,[1] in which he says: "Basing the statement upon the reports of cases operated upon, and those that have come to autopsy without operation, it may be said that 50 per cent. of intraspinal tumors are operable, and of this number one-third to one-half are benefited by operation. Spinal cord tumors are, therefore, twice as operable as brain tumors, and the results of operation are twice as successful." I take the following from the paper by Putnam, Kranss, and Park:[2] "The percentage of recovery [from spinal cord tumors with operation] in Brun's and Lloyd's collections is practically the same, being 30 per cent. in the former and 31.37 per cent. in the latter. In Putnam and Warren's collection the percentage is lower, being 21.2 per cent., while the percentage of improvement is also 21.2 per cent."

My own experience makes me very careful in giving a favorable opinion regarding operation in cases of tumor of the spinal cord or vertebræ, and yet in view of the hopelessness of treatment without operation I believe that operation should be attempted in every case of spinal tumor which seems suitable.

Of the eleven cases to which I have referred two were without clinical signs of tumor; two were cases of tumor of the spinal vertebræ; four were cases of intradural but extramedullary growths, the tumor being situated on the medulla oblongata in two, compressing the cervical region of the cord in one, implicating the cauda equina in one. Two were intramedullary growths in the tho-

[1] Loc. cit. [2] Loc. cit.

racic region. One was an intradural cyst compressing the spinal cord in the lumbar region. Disregarding the cases without symptoms of tumor and those with tumor of the vertebræ, we have remaining seven cases of tumor on or within the spinal cord, and in only two of these was operation advisable.

EXHIBITION OF A SPECIMEN OF ABDOMINAL PREGNANCY REMOVED AT THE END OF TWENTY-ONE MONTHS BY CŒLIOTOMY.[1]

By CHARLES P. NOBLE, M.D.

I HAVE here a specimen of extrauterine pregnancy which had developed probably to seven months normally, and then apparently the fœtus died. It had been twenty-one months from the time of pregnancy until the operation. I believe that the case is one of ruptured tubal pregnancy, the left tube being the one involved, and that as a result of the rupture there was a roofing-in of the left side of the pelvis by adhesions between the broad ligament and sigmoid, which formed a cap, and the fœtus developed in the sac formed in that way. At the time of operation the sac extended above the umbilicus. The fetal head was in the pelvis. The mass made a tumor about the size of a seven months' pregnancy.

The points of interest in the specimen are, that the fetal head shows very clearly the markings due to the head resting upon the sacrum, and where the head rested against the shoulder of the fœtus the skull is also indented. There was a thick sac which covered the fœtus, and the liquor amnii was all absorbed, which caused a very solid tumor with a thick wall. At various points the fœtus was adherent to the sac. This doubtless came about after the death of the fœtus.

Clinically there are one or two points of interest. About two weeks after the woman's pregnancy she was taken with violent pain, and the case was diagnosed as one of appendicitis. When she was seven months pregnant she was also ill with chills and fever and diarrhœa. The condition was treated as typhoid fever. A doctor was engaged to attend her in labor, but the labor did not come off. There were none of the symptoms of labor at full time. As a rule, in these cases there is a spurious labor. She had no symptoms until some months past the full time, when she went to a dispensary and was told she had a tumor. The same diagnosis was made later by other physicians, and operation was recommended. It was twenty-one months before she came under my care. She was sent to the Kensington Hospital for Women, with the diagnosis of fibroid tumor. Upon exam-

[1] Exhibited February 4, 1903.

ination it struck me that it was probably a pregnancy because of the feel of the fetal head. I could not be positive, because I could not feel the fontanelles. The history was, however, so suggestive: A young woman of thirty, a nullipara, with all the characteristic symptoms of pregnancy, the pregnancy developing normally until the seventh month, and after that a gradual lessening of the size of the tumor. The history was very characteristic of extrauterine pregnancy. After the abdomen was opened the diagnosis was confirmed by feeling a fontanelle.

The prominent feature in the operation was the control of hemorrhage. This has been so difficult in most cases that, as a rule, operators have removed the fœtus and left the sac and placenta. In this particular case I was satisfied from examination that I could do preliminary ligation of the ovarian and uterine arteries. After doing this I split open the broad ligament, passed my hand under the sac, separated it from below, and turned it up so that I could get at the upper vessels, the mesenteric vessels, from below and behind, and in that way, as each bleeding vessel needed only a single ligature, it was quite easy to remove the mass entire. On the other hand, if the enucleation had started from above, removing the mass from above downward, there would have been much hemorrhage.

The patient made a good recovery. The only complication was suppuration in the pelvic portion of the sac, and that gave very little trouble.

A NEW OSTEOPLASTIC TREPHINE.[1]

By W. BARTON HOPKINS, M.D.

This instrument, through the firm fixation of its centre-pin and the powerful control of its cutter, renders the forming of large osteoplastic



Osteoplastic trephine: *a*, circular frame; *b b*, set-screws, to which pads are applied; *c*, curved adjustable bracket; *d*, lock-joint; *e*, centre-pin with drill-point; *f*, cutter; *g*, lever handle.

cranial flaps comparatively easy and very expeditious. It will cut a three-inch bone-flap in from three to five minutes, and it cuts so smoothly that

[1] Read February 4, 1903.

the shock from cranial jar is, in this preliminary step to operation upon the brain, avoided. Its adjustment may be carefully and deliberately effected as follows: The circular frame (*a*) is clamped by set-screws (*b*) to the head in a position which will bring the adjustable bracket (*c*) approximately over the proposed site of the operation and in a plane beneath the greatest diameter of the head. The pressure of the pads of the set-screws need not be excessive; they can be brought to bear on points best able to stand pressure, and they are made to adhere closely to the integument by covering their surfaces with rubber adhesive plaster, adhesive side out. The curved bracket is next set by a binding-screw in a position which will bring the centre-pin (*e*) nearly in place, when a small incision is made into the scalp to receive it. The final and accurate adjustment is then completed by setting up the lock-joint (*d*) while the centre-pin is held absolutely perpendicular to the cranial dome. The drill-point of the centre-pin is then, by a few turns of its handle, made to engage in the bone. A circular incision of the integument may be made with a scalpel in a line indicated by a gentle impression of the teeth of the cutter (*f*), or a knife may be inserted in the notch of the lever corresponding to the size of the proposed flap. The notches 1, 2, 3, and 4 in the lever, in one of which the cutter is held by the binding-screw, cut flaps two, two and a half, three, and three and a half inches in diameter.

DISCUSSION.

Dr. Charles K. Mills: I have had the pleasure of seeing this instrument used at the Pennsylvania Hospital by Dr. Hopkins in opening two skulls. It is an ingenious and, I believe, practical instrument, based on good scientific and mechanical principles.

The question arises whether it is a better instrument than the Stellwagen trephine, which is the only other one which may be said to be in competition with it. Of course, it is of great importance to make a rapid osteoplastic flap. This instrument, as I saw it used, required about five minutes to open the skull, and Dr. Hopkins states that he has opened a skull in from two and a half to four minutes. In four cases on the living subject I have had the Stellwagen trephine used. The time in these four cases was: in one eighteen and one-half minutes, in another twenty-six minutes, in another thirty minutes, and in another about an hour. Of course, this included the cutting of the scalp and the tying of vessels. We did not note exactly how long it took to do merely the bone-cutting. Dr. Hearn has in another case opened the skull in about thirteen minutes with the Stellwagen trephine, and that also included the cutting and tying of vessels. So I suppose the Stellwagen trephine in its most perfect form, and

in the hands of a man who has used it a time or two, may be said to be capable of opening a skull, including the tying of vessels, in from twelve to fifteen minutes. In cases in which it took longer there were complications, and in one case the time was lengthened by the wobbling of the centre-pin of the trephine. The Stellwagen trephine requires a stronger centre-pin, and in some cases a better saw than has been used in one or two cases.

So far as I can infer, the skull can probably be opened in a somewhat shorter time by Dr. Hopkins' instrument; perhaps in one-half the time so far as the bone-cutting is concerned. Whether this difference between four or five minutes, and ten minutes, or a little more, would be a very great advantage remains to be considered. The only possible criticism of Dr. Hopkins' instrument would seem to me to be its rather formidable appearance and the fact that it takes a longer time for adjustment than the other instrument; but, as Dr. Hopkins said, the matter of a few minutes more or less in the adjustment of the ring previous to the operation is not of great moment, I suppose the size and character of the instrument would not interfere with etherization.

It is of importance that the pin should be easily made aseptic. It is much better not to use the hand in cutting the flaps. One of the excellent features of the Stellwagen trephine is that the knife-cut and saw-cut correspond exactly. I have two cases now in which the scar left by the Stellwagen trephine is so slight that it could scarcely be photographed for reproduction. The instrument exhibited this evening is certainly an ingenious one, and has nothing else to compare with it except the Stellwagen trephine, so far as I know.

TORTUOSITY OF THE AORTA.[1]

By JOSEPH SAILER, M.D., and G. E. PFAHLER, M.D.[2]

In the course of a series of studies upon lesions of the aorta, which consisted of careful clinical examinations combined with fluoroscopic and radiographic examinations, we were surprised at the frequency with which some of the lesser signs of aortic aneurism were present. Among these were inequality of the radial pulses, suprasternal pulsation, tracheal tugging, accentuation of the aortic second sound, and brassy cough. Not infrequently the patients complained of certain other symptoms, particularly dyspnœa, anginoid attacks, and localized pain. In many cases aneurism was undoubtedly present, either causing characteristic pressure symptoms or being manifest as an external expansile pulsation. In a number of cases, however, we observed with the fluoroscope an expansile pulsation at the level of the fifth or sixth dorsal vertebra, extending from one-half to two inches to the left. This, we supposed, represented an aneurismal dilatation of the aorta at this point. Upon all cases that died effort was made to obtain autopsies, sometimes successfully, and we discovered that in the majority of cases in which this skiagraphic picture was observed no dilatation of the aorta was present, nor did sections through the wall of the aorta at this point indicate that there was any diminution of the muscular layer such as might have accounted for dilatation under pressure of the blood current. In the second autopsy careful dissection showed that at this point the aorta made a bend to the left, not very unlike the tortuosity that is observed frequently in cases of atheroma of the

[1] Read February 4, 1903.
[2] Not a Fellow of the College.

peripheral arteries. Altogether we have records of eighteen cases, with skiagraphs, in which this combination occurred, and of these, four have been examined post-mortem, all with similar results. It seems not unlikely, therefore, that among subjects of arterial sclerosis this tortuosity of the aorta, giving rise to some of the signs of aneurism of the arch, is relatively a common process. There is no reason to suppose that tortuosity of the arch of the aorta differs in any way from tortuosity of the other arteries of the body. In all probability it is produced by a loss of elasticity, a gradual elongation and dilatation of the bloodvessel as a result of this loss, and the fact that at certain points in its course the artery is fixed, so that between these points compensation for elongation is only accomplished by bending. It would seem as if in the aorta this compensation could be attained by increase in the height of the arch. The arch of the aorta is practically fixed at two points—the aortic orifice of the left ventricle, and the point where it reaches the vertebral column at the level of the fifth dorsal vertebra. The position of the attachment to the heart can only vary when the heart itself is moved; the attachment to the vertebra is not quite so firm, and is made by connective tissue and by the intercostal arteries. Nevertheless it is sufficiently firm to prevent extension downward, in which it is aided by the large vessels arising from the arch. The extension upward of the arch is hindered only by the closeness of the manubrium to the bodies of the vertebræ and the fact that the space between them contains the trachea, the œsophagus, and the vessels arising from the arch. That a certain amount of extension upward usually does occur is evidenced by the frequency of suprasternal pulsation; but this extension can only be moderate, and the elongation of the aorta, exposed as it is to the full force of the contraction of the left ventricle, in all probability must be frequently so great that it cannot be compensated entirely by this movement. Therefore, it is obliged to deviate laterally, in which direction it meets little to resist it except the compressible upper lobe of the left lung. As a result of this the descending portion, before it reaches the vertebral column, becomes separated further than normally from it, so that it produces a slight bending at the

point where they join, and this bend is the tortuosity that we have observed in our skiagrams. The examinations of the aorta in old persons have convinced us that this tortuosity is by no means uncommon even in patients who have not necessarily had clinical symptoms that attracted the attention. If at an autopsy or a dissection, after the removal of the sternum, the left lung is carefully dissected away without disturbing the position of the heart, aorta, or right lung, the whole arch of the aorta is then exposed, and any irregularity readily demonstrated.

Atheroma of the aorta has received considerable attention from clinicians. The physical signs that it is supposed to cause, however, have been, as a rule, limited to an impairment of the resonant note over the upper portion of the sternum, which may extend slightly to either side of its border, and is due to dilatation of the first portion of the aorta ; a systolic murmur, heard best over the manubrium and transmitted into the vessels of the neck, and occasionally, it is stated, heard also at the apex ; and sometimes a double murmur, due less to the atheromatous condition than to the insufficiency of the aortic valves, which is secondary to it. Sansom mentions the fact that sometimes the arch of the aorta is elevated, causing elevation of the left subclavian and the innominate, and rendering these arteries more susceptible to palpation, so that it is easy to produce a thrill in them on pressure. Occasionally, however, the thrill will occur spontaneously. The symptoms of atheroma are pain, dyspnœa, and sometimes anginoid attacks. We have been unable to find any reference to the inequality of the pulses, tracheal tugging, inequality of the pupils, and suprasternal pulsation. There is some difference of opinion as to whether the second aortic sound is invariably accentuated or not. It does not appear to have been recorded that typical aneurismal cough may occur as a result of an atheromatous condition without aneurismal dilatation.

The investigators who have employed the fluoroscope or skiagrams for the purpose of studying changes in the aorta were early impressed by the fact that although aneurism was occasionally overlooked, it was more frequently diagnosed when it did not exist. In 1897 Levy-Dorne stated that the early stages of

aneurism were more common than had hitherto been supposed, and that the prognosis of commencing aneurism appeared to be not so unfavorable, especially as only a few had any tendency to enlarge. His pictures illustrate the small pulsating projections to the left of the sternum. Goeht, a year later, thought that by means of the Roentgen ray it was possible for the clinician to determine the presence of aneurism in cases in which doubtful symptoms were present. In opposition to this, Dumstrey and Metzner recommend considerable caution in the diagnosis of aneurism by means of the Roentgen rays, especially when there are no physical symptoms. They thought that mediastinal tumors might give rise to the same picture. Holzknecht was the first to show that pulsating hemispherical shadows just above the heart are not always aneurisms. He argued that this idea was based upon the supposition that the thoracic aorta was always situated in the median line, and that the arch lies in the shadow of the sternum. This is true only of the ascending portion of the arch, and as the transverse and descending portions lie practically in the same plane, they are projected as a pulsating band-like shadow, intensely dark and with a free end. It may be seen during life, although he agrees with Weinberger, that it rarely projects considerably to the left. This projection has also been observed and described by Immelmann. Holzknecht later discussed the subject more thoroughly in his text-book. In this he stated that aneurism of the arch theoretically was usually seen to the right of the sternum in sagittal pictures. Dilatation gives rise to a shadow seen on either side of the sternum and is readily confused with aneurism. The differential diagnosis can be made by the fact that there are no pressure symptoms and no tendency of the shadow to enlarge. Simple dislocation of the aorta usually appears just to the left of the spinal column, and the pulsating shadow sometimes extends as much as six inches to the left of the left border of the sternum, forming, in fact, a pulsating shadow much larger than that projected by aneurism of the arch. In cases in which the heart is elevated the natural bending of the heart to the left is increased. In forty-six cases that he observed in which this shadow was present, only six proved ultimately to

be cases of aneurism. Holzknecht has undoubtedly seen and correctly interpreted the picture to which we call attention; but he classifies all these conditions as dislocation of the aorta, and fails to recognize that there is usually an actual elongation of the vessel, and that in addition to the thrusting of the arch to one side there is also a condition of tortuosity.

The following are the abridged notes of the cases that we observed:

Case I.—P. H., aged thirty-eight years, a negro hostler. Had syphilis at the age of fifteen years. Eighteen months before death he received a blow over the right clavicle, and later noticed pulsation in the right side of the neck, followed by pain, cough, and paroxysms of dyspnœa.

Physical Examination. The pupils were equal. The right radial pulse was absent; the left radial pulse was small. The right carotid pulse was absent, and the left carotid pulse and its branches pulsated vigorously. There was pulsation of the prominent sternal end of the right clavicle, due to a mass beneath, in which there was neither thrill nor murmur. The right external jugular vein was distended. The area of cardiac dulness was normal. The aortic second sound was accentuated. A diagnosis of innominate aneurism was made, but it was difficult to explain why the left radial pulse was so weak. The fluoroscope showed a pulsating tumor in the region of the innominate, and a prominence to the left of the descending aorta that had expansile pulsation. At the autopsy there was found aneurism of the innominate artery and atheroma and tortuosity of the arch of the aorta.

Case II.—W. B., aged sixty-nine years, white, a printer. Had been an inmate of an insane asylum. There was no history of rheumatism; he denied syphilis; he had smallpox at thirty-nine. He complained of dyspnœa on exertion, pain and cough. He was also maniacal.

Physical Examination. The left subclavian artery and its branches pulsated more weakly than the corresponding arteries to the right. The carotids were equal. There was distinct downward tracheal tugging and suprasternal pulsation. The left ventricle was dilated, and there was a systolic murmur transmitted into the vessels of the neck. The fluoroscope showed a prominence to the left of the aorta which had expansile pulsation. At the autopsy there was atheroma of the aorta, with tortuosity of the descending portion. There was no aneurism and no dilatation.

Case III.—J. H., aged fifty-seven years, white, a machinist. He denied rheumatism and syphilis, but had had heart trouble for ten years. He complained of pain in the precordial region and dyspnœa.

Physical Examination. There was a receding pulse with Traube's and Duroziez's signs. There were suprasternal pulsation and doubtful tracheal

tugging. The left ventricle was considerably enlarged. There was the double murmur of aortic regurgitation. There was no accentuation of the aortic second sound. The X-ray showed the characteristic pulsating prominence to the left of the aorta. A diagnosis was made of insufficiency of the aortic valves, dilatation of the aorta and tortuosity.

CASE IV.—J. L., aged ninety-seven years, white, a shoemaker. He denied syphilis and rheumatism. He suffered from dyspnœa on exertion. He had no cough and no pain.

Physical Examination. The arteries of the distribution of the left subclavian pulsated more feebly than those of the right. The carotids were equal. There was suprasternal pulsation and slight tracheal tugging. The percussion note over the base of the sternum was impaired. There was general atheroma. The fluoroscope showed a pulsating mass to the right of the descending arch of the aorta. At the autopsy the aorta was found to be tortuous, and there was no aneurism and no dilatation.

CASE V.—N. McC., aged seventy-three years, white, a stonemason. Had had rheumatism and used alcohol to excess. He complained of dyspnœa on exertion, and had a cough that was slightly metallic.

Physical Examination. The carotid and radial pulses were equal. There was distinct suprasternal pulsation and tracheal tugging. There was impaired resonance over the manubrium, and the second aortic sound was accentuated. The fluoroscope showed an abnormally broad aortic arch and a pulsating prominence to the left of the descending arch.

CASE VI.—W. S., aged twenty-four years, white, a barber. He gave a history of rheumatism, and admitted alcohol in moderation, but denied syphilis. He had no dyspnœa and no pain. He had a hoarse but not metallic cough. The radial and carotid pulses were equal; there was distinct tracheal tugging; there was impaired resonance over the manubrium, and a faint systolic murmur heard over the base and transmitted into the vessels of the neck. There was no thrill. The fluoroscope showed a pulsating prominence to the left of the descending portion of the arch of the aorta.

CASE VII.—A. T., a laborer, had had rheumatism. Admitted alcohol in moderation, but denied syphilis. There was dyspnœa upon exertion and precordial pain, but no cough.

Physical Examination. The left radial pulse was smaller than the right. There was no tracheal tugging and no suprasternal pulsation. The fluoroscope showed a pulsating projection to the left of the descending portion of the arch of the aorta.

CASE VIII.—J. W., aged forty-three years, a negro laborer. Many of his family had heart disease. He had acute articular rheumatism at twenty-five. On admission he had dyspnœa, increased by exertion, cough and expectoration, and pain in the chest and epigastrium.

Physical Examination. The left radial was smaller than the right and seemed slightly retarded. The arteries were atheromatous. The heart was

enlarged; there was a systolic musical murmur transmitted into the vessels of the neck, which subsequently showed a double murmur. There was slight tracheal tugging; a thrill was readily produced by pressure upon the subclavians, and occasionally was spontaneous. The fluoroscope confirmed the great enlargement of the heart, the increased breadth of the arch of the aorta, and also showed a projection to the left of the descending portion of the arch that had expansile pulsation. At the autopsy obliterative pericarditis was found with hypertrophy of the heart, atheroma and marked dilatation, and tortuosity of the aorta at the junction of the arch and the vertebral column.

Case IX.—H. W., aged sixty-eight years, white, a carpenter. He suffered from dyspnœa on exertion, and gave a doubtful history of paralytic stroke.

Physical Examination. The left radial pulse was smaller than the right. The carotids were equal; the left pupil was slightly dilated. The heart was enlarged; there was a double murmur over the base; suprasternal pulsation and distinct tracheal tugging. Percussion resonance over the manubrium was impaired. The fluoroscope showed a pulsating projection to the left of the descending portion of the arch.

Case X.—W. S., aged seventy years, white, a laborer. Had had rheumatism, but denied syphilis. He complained of severe cough, which was distinctly metallic in character.

Physical Examination. The left radial pulse was smaller than the right. There was distinct tracheal tugging and impaired resonance over the manubrium. The fluoroscope showed a distinct bulging to the left of the descending portion of the arch of the aorta, which had expansile pulsation.

Case XI.—S. McH., aged fifty-one years, white, a carpenter. Admitted syphilitic infection. At forty-three had right hemiplegia.

Physical Examination. Pupils were equal; the carotids and radial pulses were equal. There was tracheal tugging and a faint suprasternal pulsation. The heart was not enlarged. The second aortic sound was not accentuated, but the first sound was loud. There was impaired resonance over the manubrium, and the patient had a hoarse, aneurismal cough, which had lasted seven years. The fluoroscope showed increased width of the arch of the aorta and a projection to the left of the descending portion of the arch, which had expansile pulsation.

Case XII.—M. O., white, a female domestic. Had been conscious of heart disease for two years.

Physical Examination. Pupils were equal; the right radial pulse was slightly weaker than the left. There was expansile pulsation in the lower portion of the neck, which was apparently due to an atheromatous anomalous vessel. There was no tracheal tugging and no thrill. The heart was enlarged to the right and left. There was a systolic murmur transmitted into the vessels of the neck. The aortic second sound was greatly accent-

uated, and the pulmonic second was reduplicated. The percussion note over the manubrium was impaired. The patient had dyspnœa, but no pain and no cough. The fluoroscope showed dilatation of the ascending portion of the arch of the aorta that had expansile pulsation.

Case XIII.—T. W., aged thirty-six years, white, laborer. Had had malaria, rheumatism, and syphilis. Admitted excessive indulgence in alcohol. For about two years he had had boring pain in the left chest, located usually in the sixth interspace, either just beneath the angle of the scapula or in the nipple line. It was worse after exertion, and the sixth rib was tender.

Physical Examination. Pulsation in the left subclavian, brachial, and radial arteries could not be felt. In the right subclavian, brachial, and radial arteries it was strong. The carotids were equal. There was a systolic murmur heard best at the apex. The aortic second sound was greatly accentuated. There was slight paralysis of the left vocal cord (Dr. Gleason). The fluoroscope showed a distinct prominence of the descending portion of the arch, which had expansile pulsation. There was no dilatation of the aorta in any part. The patient is still alive, and the signs have not changed in eighteen months. It seems not impossible that in this case we are dealing with an actual aneurism, although the fluoroscopic picture is the same as that in the other cases.

Case XIV.—R. W., aged forty-four years, white, a knife-grinder. Had had psoriasis for twenty years; had used alcohol and tobacco to excess. He denied venereal disease. One year ago he had erysipelas.

Physical Examination. The pupils were equal; the left brachial and radial arteries pulsated more weakly than the right. The carotid pulses were equal. The heart was not enlarged. The aortic second sound was accentuated; there was no suprasternal pulsation, but distinct tracheal tugging. The fluoroscope showed increase in the width of the arch of the aorta and a projection to the left of the descending portion which had expansile pulsation.

Case XV.—M. B., female, aged seventy years, white, a domestic. Had had rheumatism for many years. Had dyspnœa upon exertion, and had complained for twenty years of pain in the left side of the chest. There was a cough which was not metallic in character.

Physical Examination. The radial pulses were equal; there was an anomalous vessel crossing the anterior portion of the neck which was atheromatous. There was no tracheal tugging. The heart was slightly enlarged, and there was a double murmur over the base, the systolic element being transmitted into the vessels of the neck. The fluoroscope showed dilatation of the ascending portion, and a projection to the left of the descending portion of the arch of the aorta which had expansile pulsation.

Case XVI.—J. T., aged sixty-one years, white, a broom-maker. Had malaria at thirty-six, pleurisy at forty-five, and several attacks of asthma.

He denied syphilis. He complained of cough and moderate expectoration.

Physical Examination. The right carotid and subclavian arteries and their branches pulsated more vigorously than the corresponding vessels on the left. There was no tracheal tugging, but a powerful suprasternal pulsation. The heart was slightly enlarged. There was a systolic murmur transmitted into the vessels of the neck, and the aortic second sound was accentuated. The fluoroscope showed dilatation of the ascending portion of the arch of the aorta, and distinct prominence of the descending portion of the arch with expansile pulsation.

Case XVII.—P. D., white, a stonecutter. Had used alcohol to excess; he never had rheumatism, and denied syphilis. There was moderate dyspnœa, pain in the region of the heart, and a cough which was not metallic in character.

Physical Examination. The pupils were equal and of the Argyll-Robertson type. The right pupil was smaller than the left. The carotid and radial pulses were equal. There was a thrill in the vessels of the neck upon pressure. There was suprasternal pulsation and distinct tracheal tugging. The heart was slightly enlarged to the left; there was a soft systolic murmur at the apex and base, and a harsh systolic murmur at the base. There was also a harsh systolic murmur in the vessels of the neck. The aortic second sound was not accentuated. The fluoroscope showed dilatation of the ascending portion of the arch of the aorta, and a projection to the left of the descending portion which had expansile pulsation.

Case XVIII.—C. H., female, aged eighteen years, white, a domestic. Patient had recently had acute articular rheumatism.

Physical Examination. The carotids and radials were equal. There was suprasternal pulsation, but no tracheal tugging. The heart was not enlarged; the second aortic sound was greatly accentuated. The fluoroscope showed that the ascending portion of the arch was increased three-fourths of an inch in width, and to the left of the descending portion there was a shadow that had expansile pulsation.

In summarizing these cases we find that the inequality of the pulses was present in 10 and not present in 8 cases. That in 9 of the 10 cases pulsation was more vigorous on the right than on the left side. Inequality of the pupils was present in 3 cases; in 1 of these there was reason to believe that it was due to some nervous condition, as the pupils showed the Argyll-Robertson phenomenon. Suprasternal pulsation was present in 12 cases and absent in 6. Tracheal tugging of distinct downward character was present in 11 and absent in 7 cases. A systolic thrill was felt in the vessels of the neck either with or without slight pressure,

Fig. 1.

Normal chest. No bulging in the shadow of the aorta at the junction of the transverse and descending portion.

Fig. 2.

Tortuosity of the aorta. The dark shadow of the spinal column may be seen in the central portion of the skiagraph. The shadow of the aorta extends upward about one inch to the right of the spinal column, and at the left makes a sharp bend about two inches to the left, then curves inward and downward, where it joins the shadow of the heart.

Fig. 3.

Tortuosity of the aorta, shown by the projections in the shadow at the left portion of the arch.

Fig. 1.

Tortuosity of the aorta and aneurism of the innominate artery. The shadow of the aorta may be seen extending upward to the right of the spinal column where it is continuous with the shadow of the innominate aneurism; then a bulging is seen at the left portion of the arch, which is indicative of the tortuosity.

Fig. 5.

Tortuosity of the aorta, shown by the projection in the shadow at the left portion of the arch.

Fig. 6.

Tortuosity of the aorta. This is shown by the marked bulging of the shadow at the junction of the transverse and descending portions of the arch of the aorta.

Fig. 7.

Tortuosity of the aorta. This is indicated by an increase of about one inch in the shadow of the aorta at the junction of the transverse and descending portions.

Fig. 8.

Tortuosity of the aorta, indicated by the bulging of the shadow at the left portion of the arch.

in 9 cases, and it could not be elicited in 9 cases. A systolic murmur, usually transmitted into the vessels of the neck, was present in 11 cases, but was not heard in 7 cases. Twelve of the cases had dyspnœa; in one of these there were physical signs of emphysema and chronic bronchitis, in the others it was probably due to the cardiac condition. Many of these patients were old, and nearly all of them had atheromatous arteries. Precordial pain was present in 7 cases and not complained of in 11 cases. In many of the cases complications in the form of valvular heart disease were present. In one case there was actually an aneurism of the innominate artery. The degree of atheroma and the age of the patient also modified the symptoms, and the extent of the tortuosity must vary considerably in different cases.

It is difficult from this study to give a clear picture of the symptomatology of the condition of atheroma of the aorta leading to tortuosity of the descending portion of the arch. It may at least be said that in those conditions in which atheroma and tortuosity exist, certain of the physical signs, particularly tracheal tug and inequality of the radial pulses, which have been supposed to be strongly suggestive of aneurism, are not uncommon, and that they are associated with other signs and symptoms, such as murmur, thrill, suprasternal pulsation, inequality of the pupils, accentuation of the aortic second sound, which are also found in aneurism of the arch. Probably it would be justifiable to suspect tortuosity in cases in which there is inequality of the radial pulses, slight tracheal tugging, dyspnœa, and in which the symptoms are stationary for a considerable period of time and the fluoroscope shows a projection to the left of the descending portion of the arch of the aorta that has expansile pulsation.

References.

1. Sansom. Diseases of the Heart, London.
2. Levy-Dorne. Congress für innere Medicin, Berlin, 1897, p. 316.
3. Goeht. Lehrbuch der Röntgenuntersuchung, Stuttgart, 1898, p. 199.
4. Dumstrey and Metzner. Fortschritt auf dem Gebiete der Röntgenstrahen, vol. i.
5. Holzknecht. Wiener klin. Woch., 1900, No. 10
6. Weinberger. Atlas per Radiographie der Brustorgane, Vienna, 1901.
7. Immelmann. Röntgen Atlas des Normalen Menschlichen Körpers, Berlin, 1900.

THE OCULAR COMPLICATIONS OF VARIOLA.[1]

By BURTON K. CHANCE, M.D.,
ASSISTANT SURGEON, WILLS EYE HOSPITAL, PHILADELPHIA.

This communication is based upon a series of observations made in the course of the epidemic of variola that visited Philadelphia in the years 1901 and 1902. In addition to the opportunities for study obtained elsewhere on earlier occasions, I was repeatedly called into consultation by Drs. William M. Welch and Jay F. Schamberg at the Municipal Hospital. To the courtesy of these gentlemen I am indebted for the facilities afforded for a personal study of the cases under their care and for other data which have enabled me to present a complete report of the ocular complications found in variola.

Variola is a disease with which the ophthalmic surgeon of the present day only rarely comes in contact, for since Jenner's discovery it is no longer the general scourge it was, and the destructive effects on the ocular tissues are less than in former times; then, too, early recognition of the disease and therapy of the ocular lesions have been insisted upon in recent years, with the result that fewer cases are seen to progress to the degree so commonly noted in past years.

In spite of this, ocular affections are quite usual in variola, attacking almost every portion of the visual apparatus. They appear oftentimes in the acute stages of the disease; again, they may not appear until convalescence, and they are frequently found for the first time as a sequel.

In the analysis of over 2000 cases at the Municipal Hospital of Philadelphia there were 36 instances of corneal ulcer, 17 of which were followed by perforation, with destruction of one eyeball, and

[1] Read February 4, 1903.

15 were cured without perforation. Of these cases 15 were in unvaccinated individuals; in 6 others vaccinated at periods more or less remote the lesions were less severe. Pustulation of the lid borders was a common affection; conjunctivitis was frequently found with it, and was also found independently. Especially to be noted were 10 cases of iritis.

The report of the ocular lesions occurring in variola is necessarily incomplete scientifically because of the difficulty in studying satisfactorily the eyes of infected persons and the impossibility of keeping track of the individuals after their discharge from the hospital. This incompleteness is increased by the fact that in several cases in which continued observation has found intraocular lesions it is almost impossible to determine whether the conditions noted are due to the specific variolous infection or whether they were present prior to the onset of the exanthem.

In taking up the systematic consideration of the action of variola on the parts of the eye we find that the skin of the lids is commonly a site of the pustular eruption. So much swelling of the tissues may accompany the eruption that the eyes cannot be opened for several days. In such cases severe conjunctivitis is usual and often leads to corneal ulceration. The edges of the lids are liable to ulceration, and the subsequent cicatrization distorts them, so that styes, misplaced cilia, eversion of the lids, adhesion of the lids, or occlusion of the Meibomian ducts, etc., may result. The lids, like other portions of the skin, may be, after the subsidence of the eruption, the seat of abscesses which produce various deformities, requiring operation later. As to the mucous membrane of the lacrymal passages, pustules may also form there and give rise to acute, and, later, chronic inflammation of the canal and duct. On the orbital borders periostitis with carics occurs but rarely.

Passing on to the conjunctiva we find that, as in other febrile diseases, it is commonly affected. Inflammation develops about the fifth day of the eruption. The conjunctiva appears congested and occasionally presents a catarrhal inflammation, which is usually of moderate severity and of brief duration, yielding in a few days to treatment. An exception to this appeared in a young man recently under treatment, in whom severe conjunctivitis began on the

seventh day, and, in spite of careful treatment, persisted over a month.

The intensity of the ophthalmia is related directly to that of the pustular eruption in general, and more particularly to that of the eruption on the face and eyelids. On the conjunctiva pustules form but rarely. Among the 2000 patients with variola examined by us in 1901 to 1902 they were noticed in only two or three instances. When they do occur these pustules much resemble in appearance and course the phlyctenular eruption observed in strumous children. They are the size of small lentils, elevated but slightly, and usually situated midway between the corneal margin and the inner and outer canthus. They appear sometimes at the limbus, and, when there, frequently cause ulceration of the cornea. On the tarsal conjunctiva pustules may be found at the inner fold and on the caruncle, but never at the fornix. In these cases the conjunctival inflammation markedly resembles that of gonorrheal infection. The inflammation is always severe and is accompanied by profuse secretion and chemosis. Subconjunctival ecchymosis may occur and may produce intense chemosis in hemorrhagic variola. The bacteriological examination of the conjunctival secretions showed the presence of no specific or hitherto undescribed organisms, but there were present in abundance staphylococci, streptococci, and pneumococci.

The cornea, according to other observers, is not subject to the specific lesions of variola, and our experience in the treatment of over 7000 patients leads us to accept this conclusion. Ulceration of the cornea does occur, but it is usually independent of the general process, being rather a consequence of the conjunctival affection; and now, just as in past times, it is the most fruitful cause of blindness as a sequel of variola.

The corneal complications may arise in two ways: first, either without pustules on the conjunctiva or by pustulation, especially when this is at the limbus; second, during the stage of desiccation, when the contagion is transmitted from some broken-down pustules—as, for instance, those of the skin of the eyelids.

The corneal inflammation may be only a slight superficial haze confined to the corneal conjunctiva or Bowman's membrane, or it

may extend rapidly and involve the entire membrane. Commonly, near the margin of the cornea is seen a small phlyctenular bleb, filled with clear fluid, the thin and delicate covering of which is soon macerated by the increased conjunctival discharge, and the vesicle is ruptured, exposing an area of necrotic tissue of grayish color. The symptoms of pain and redness, although usually marked, vary in intensity and duration. As the ulcerated surface spreads the several layers of the cornea are involved until the membrane is perforated, and then the aqueous humor escapes and prolapse of the iris follows. At this time the painful symptoms abate. In bad cases pus forms in the anterior chamber, or the crystalline lens and the vitreous humor may be extruded, panophthalmitis developing from a general suppuration of the eyeball, accompanied by great pain, with marked bulging of the lids. Fortunately, the majority of cases present a milder form of keratitis. In this there is only a circumscribed superficial inflammation, which heals promptly and leaves the eye damaged only by the formation of an opacity as the result of the cicatrization of the necrosed area. These scars cause marked irregular astigmatism, which greatly interferes with the acuteness of sight.

In severe cases of confluent variola rapid destruction of the cornea may take place as early as the eighth day. It is usually a forerunner of fatal collapse. In some instances both eyes are affected. As an example of this, four patients in our own wards sank rapidly after the destruction of both eyes at an early stage of the general disease. In these cases it was noted that the ulceration was preceded by a grayish infiltration of the bulbar subconjunctival tissues. This chemosis rapidly increased, rising above the cornea and surrounding it, choking off its circulation. Immediate destruction of the cornea followed—a true keratomalacia. In certain instances the chemosis is so great as to produce an œdema of the subconjunctival and subcutaneous tissues, even to such an extent as to make it almost impossible for the lids to be opened.

It was our experience to find the ulceration of the cornea less extensive in size and degree in the case of those who had been vaccinated; consequently the healing was more prompt and the sequels were less damaging to the integrity of the eyeball.

Parenchymatous keratitis after variola has been reported by but few observers. We observed two cases. The first was in a young man with confluent variola, who developed, about the seventeenth day, a general haziness of the left cornea. This gradually improved, leaving a slight opacity behind it. About two weeks later an ulcer developed upon this site, without, however, producing serious complications. The second was in a young woman, aged nineteen years, heretofore of apparent robust health. With her, marked corneal haze was noticed in the third week of the general disease. Her convalescence was prompt, yet on discharge from the hospital there was noticed well-defined interstitial infiltration and iridocyclitis associated with it. For two months she has been under treatment, and her progress toward recovery has been rapid.

The uveal tract is not so frequently affected as the cornea. In our examinations we noted ten cases of iritis, not plastic in form but of the serous type. This condition was especially marked in hemorrhagic variola. Other observers have noted iritis developing after the subsidence of the general symptoms. Slight pericorneal injection has been sometimes noticed in the first week, accompanied by lacrymation, photophobia, tenderness, and a small, immobile pupil. Although this ciliary irritation may be an independent affection, it is usually a symptom of corneal or iritic disease. It appears to be more frequent in the milder cases, and may persist for a considerable time after the termination of the attack of variola. Choroiditis was revealed only by the presence of opacities in the anterior or posterior part of the vitreous. We have had the opportunity of studying the ocular conditions of a vigorous young man for several weeks after his discharge from the hospital. In each eye were numerous floating vitreous opacities, which rapidly lessened as he regained strength.

In none of the cases examined did we find circumscribed choroidal inflammation, nor did we see posterior polar cataract. We can report no cases of glaucoma due to variola, nor any cases of retinitis or neuroretinitis; but all these have been reported in the literature of variola by other observers.

While renal disease in the course of the variolous attacks was commonly observed, yet it did not progress far enough so that we

were able to record any real cases of albuminuric retinitis; and patients with pronounced uræmia sank into a coma so rapidly that it was impossible to ascertain whether or not the uræmic condition had affected the retinal sheet, although it probably had. In hemorrhagic variola there is no reason to doubt the occurrence of hemorrhages into the retinal sheet, and very probably hemorrhages into the optic nerve may occur. We have not been able to find any such cases reported as actually observed, but Knies is of the opinion that such hemorrhages must have been the cause of some of the affections described as neuritis with and without stasis and with and without termination in atrophy of the optic nerve.

Meningitis as an undoubted sequel is rarely found, but we have come in contact with cases of meningitis for which no logical cause could be found except a far distant attack of variola.

A PHYSIOLOGICAL, ANATOMICAL, AND PATHOLOGICAL STUDY OF THE GLOSSOPHARYNGEUS AND VAGUS NERVES IN A CASE OF FRACTURE OF THE BASE OF THE SKULL.

By WILLIAM G. SPILLER, M.D.,
ASSISTANT CLINICAL PROFESSOR OF NERVOUS DISEASES AND ASSISTANT PROFESSOR OF NEUROPATHOLOGY, UNIVERSITY OF PENNSYLVANIA.

(From the William Pepper Laboratory of Clinical Medicine, Phoebe A. Hearst Foundation.)

The opportunity to study the effect on man of unilateral degeneration of the glossopharyngeus and vagus nerves from a lesion near the medulla oblongata is rarely offered, and the following case is reported in the hope that it may throw some light on the physiology and the anatomy of these nerves. H. R., aged about fifty-four years, on April 8, 1902, fell about eight feet from a car, striking on the top of the head. There was no detectable fracture of the skull, and no paralysis of the limbs. He was unconscious fifteen or twenty minutes after the fall; he then got up and walked a short distance. He was not able to swallow at all after the accident. The tongue when protruded was said to deviate a little to the left. He had a small scalp wound over the right frontal bone. The man was sent to the University Hospital by Dr. D. P. Miller, of Huntingdon, Pa., and was referred to my service by Dr. James Tyson. My notes, made May 6th, are as follows:

"Sensation for touch and pain is intact in the limbs and trunk. The grasp of each hand is normal. No loss of motor power is

[1] Read March 4, 1903.

detected in any of the limbs. The patellar reflex on the right side is normal or slightly diminished, and on the left side it is present, but not very strong. Ankle clonus is not present on either side. The Babinski reflex is not obtained on either side. The Achilles-jerk is normal on each side, but not quite so prompt on the right side as on the left. The station and gait are normal even with the eyes closed, but the man has a tendency to drag his feet slightly. The reflexes of the upper limbs are normal. He has no muscular atrophy. He has no hysterogenic zones. The tongue is protruded straight, and shows no atrophy and no fibrillary tremors. The soft palate is a little better innervated on the right side than on the left. The pharyngeal reflex is preserved on each side. Salt and sugar are tasted correctly and promptly on the anterior two-thirds of each side of the tongue. The ticking of a watch is not heard plainly in either ear, but he has always been a little hard of hearing. The facial muscles are not implicated. The movements of the eyeballs are normal in all directions. Slight nystagmus is present in looking to either side, and the left external rectus may be a little weak."

The nystagmus was probably the result of the injury of the left cerebellar lobe.

The report of the examination of his eyes by Dr. Mellor is as follows: "There are no evidences of injury in the eye-ground. The right eye is very highly myopic. A cataract is present in the left eye."

The report of the laryngeal examination by Dr. Grayson is as follows: "Complete paralysis of the left half of the larynx. Absolute immobility of the left vocal cord and arytenoid cartilage. Moderate amount of simple inflammatory infiltration."

The man was kept alive by nutrient enemata, but he became gradually weaker, and finally was unable to retain the enemata. Dr. D. L. Edsall, with great difficulty, succeeded in passing the stomach tube on May 23d, but after it had been passed twice the patient declined to permit it to be passed again, preferring to die rather than to undergo the discomfort caused by passing the tube. The tube seemed to lodge in a pocket of the œsophagus at the cardiac end of the stomach. The pocket was probably the

result of paralysis of the œsophagus on the left side. The stomach tube was not passed until May 23d.

At 11.30 A.M., May 24th, the pulse became more rapid and the temperature subnormal, and at 1 P.M. the man died.

My diagnosis in this case had been fracture of the base of the skull, possibly with hemorrhage at the base of the brain, and the necropsy showed that the diagnosis was correct. The necropsy was made by Dr. W. F. Hendrickson. His notes are as follows:

"*Pathological Diagnosis.* Cerebellar hemorrhage and softening, with pressure upon adjoining nerves; multiple abscesses of lung (probably bronchopneumonic in origin); parenchymatous degeneration of the liver and kidneys; chronic interstitial splenitis.

"*Detailed Description of the Organs. External Appearance.* Body that of a fairly well-developed and fairly well-nourished white male. Slight rigor mortis. No œdema. Superficial abrasion over auricle of left ear, also on neck just below left ear.

"*Abdominal Cavity.* Normal.

"*Pleural Cavity.* Normal.

"*Pericardial Cavity.* Normal.

"*Heart.* Weight, 270 grammes. Normal.

"*Lungs.* Left lung voluminous, and on palpation numerous nodules of increased consistence and averaging 1.5 cm. in diameter can be felt. On section the general lung surface is congested, and corresponding to the nodules referred to above are quite a few small areas of consolidation, dark red in color, and with a granular surface. Most of these resemble the areas of bronchopneumonia, but others show distinct breaking down in the centre with abscess formation. The abscesses are little more than the size of a split pea.

"The right lung shows a similar condition throughout the middle lobe. Upper and lower lobes the seat of congestion.

"*Spleen.* Somewhat enlarged. Cut surface grayish-red. Consistence slightly increased. Trabeculæ prominent.

"*Gastrointestinal Tract.* Slight hyperplasia of solitary follicles throughout gut.

"*Liver.* Weight, 1 kilo. Normal in size. Cut surface cloudy. Consistence slightly decreased.

"*Gall-bladder.* Moderately dilated, and found to contain from fifteen to twenty stones of light yellowish-white color, superficially dark brown in tint.

"*Pancreas.* Slight increase in consistence. Cut surface shows lobules more clearly than normal.

"*Adrenals.* Negative.

"*Kidneys.* Normal in size. Capsule strips readily. Surface markings indistinct and cloudy. Consistence slightly decreased. Weight, 290 grammes.

"*Genito-urinary Organs.* Negative.

"*Aorta.* Negative.

"*Brain.* Marked œdema of pia-arachnoid coat. Examination of the base of skull reveals a fracture of the left side of the occipital bone into the foramen magnum, with a spicule of bone projecting at least one-quarter inch upward. Corresponding to this projecting spicule of bone is discovered an area of hemorrhage and softening on under surface of the cerebellum. Area of cerebellar involvement measures 1.5 x 1 cm. in size. Bony projection undoubtedly pressed upon adjacent nerves coming off from the medulla."

The microscopic examination was made by me.

The left glossopharyngeus and vagus roots in teased preparations stained with 1 per cent. osmic acid appeared intensely degenerated. The left recurrent laryngeal nerve and portions of the left vagus below the cranium treated in the same way were greatly degenerated. The left facialis and hypoglossus, the roots of the left trigeminus and of the right glossopharyngeus were normal.

Fine black dots were found by the Marchi method along the intramedullary portion of the left hypoglossus, so that this nerve was slightly degenerated. The descending root of the left glossopharyngeus and vagus nerves was intensely degenerated by the Marchi method, as was also the transverse portion of the intramedullary part of the left glossopharyngeus and vagus roots, and the degeneration was found as far cephalad as there are fibres of these nerves. The fibres arising in the left nucleus ambiguus and passing toward the fourth ventricle were degenerated by the Marchi method. Degenerated fibres could be traced across the raphe to

the right fillet, but were lost here. They crossed the raphe about midway between the ventral and dorsal surfaces of the medulla oblongata. It is impossible to say whether or not they were fibres of the glossopharyngeus and vagus nerves passing to the opposite side of the medulla oblongata. Most of the degenerated fibres

FIG. 1.

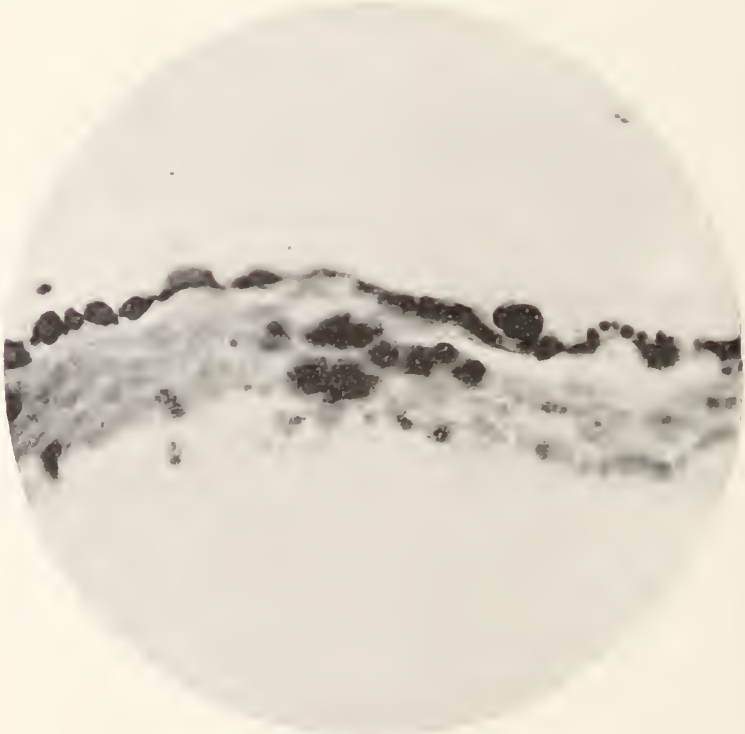

Photograph of degenerated root fibres of the glossopharyngeus and vagus nerves. Teased preparation stained with 1 per cent. osmic acid.

of the left glossopharyngeus and vagus roots entered the descending root of these nerves, but some passed this root on its median side in their course, apparently toward the posterior nucleus. The left facialis root at its exit from the pons was not degenerated by the Marchi method, and the fibres within the left facialis nucleus were not degenerated. The left cochlear branch of the

acusticus nerve was not degenerated within the medulla oblongata by the Marchi method.

Some of the cells of the left hypoglossus nucleus were swollen, and in these the nuclei were eccentric. The cells of the left nucleus ambiguus were much degenerated, they had lost their dendritic processes, the nuclei were not distinct, and the cells did not stain well. The nuclei in most of the cells in the posterior nucleus of

Fig. 2.

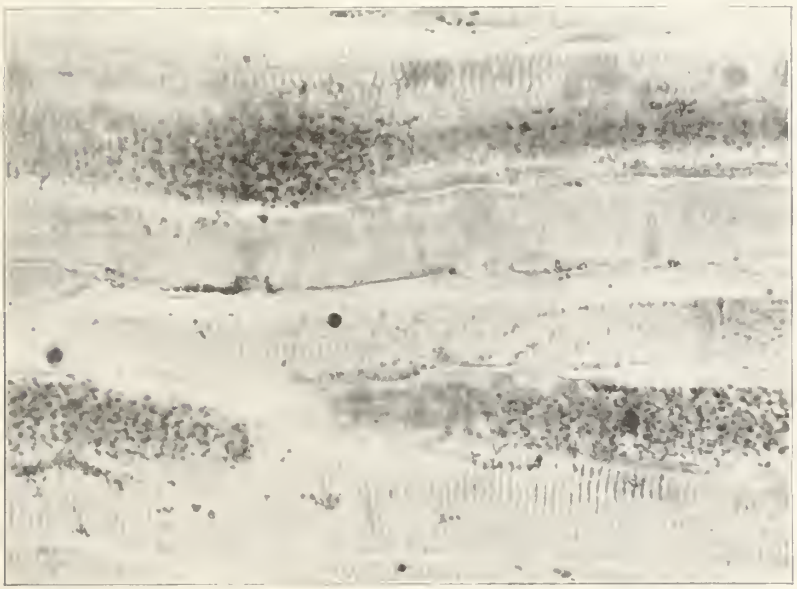

Photograph of the left laryngeal muscles, showing degeneration by the Marchi method.

the left glossopharyngeus nerve were eccentric, whereas in the corresponding right nucleus they were central, with few exceptions.

A very few muscle fibres in the left side of the tongue in the region of the circumvallate papillæ were degenerated by the Marchi method, but the left laryngeal muscles were intensely degenerated. Sections of the left side of the pharynx at the level of the hyoid bone, stained by the Marchi method, contained some degenerated fibres, but not nearly so many as did the left laryngeal

muscles. Sections from the middle of the arch of the left soft palate contained only a few degenerated muscle fibres.

The degeneration of the vagus on the left side in my case affords an opportunity to study the effect of injury of this nerve on the heart and lungs. This subject has received careful study by reliable observers. Bernhardt,[1] in his recent work on the nerves, says that according to some authors the inflammatory changes in the lungs of the character of bronchopneumonia, occurring after vagus lesions, are the result of paralysis of the bronchial musculature and of the vasoconstrictor fibres, which causes neuroparalytic hyperemia of the pulmonary tissue. He says, further, that, according to Deibel, it is not a fatal operation. Only division of both vagus nerves is fatal. Similar views were expressed by Demme and Mackenzie. The observations, however, of Demme and Stromeyer show that occasionally in man disquieting symptoms may result from unilateral division of the vagus; such as at first slow, deep respiration, hoarseness or almost loss of voice, diminished respiratory murmur on the injured side, dyspnœa, danger of suffocation, and small and rapid pulse. Stromeyer's case, however, is not altogether satisfactory.

According to Traumann,[2] pulmonary symptoms were present in all reported cases of bullet wound of the vagus except in his own case, as in all there was a weak respiratory sound, or even absence of respiratory sound on the side of the injury, or even pneumonia. Unilateral division of the vagus in experiments on animals, he says, has caused few pulmonary symptoms. Only rarely in dogs, never in rabbits, and after a considerable period has it caused any grave disease of the lungs. One vagus seems to be sufficient for the function of both lungs. Traumann says that in twenty cases known to him in which the vagus was resected during the removal of a tumor, no persisting impairment of respiration was observed. He points out that in Stromeyer's case of injury of the vagus both vagi were injured. Other cases, he

[1] Die Erkrankungen der peripherischen Nerven: Nothnagel's Specielle Pathologie und Therapie, vol. xi. part 1.

[2] Deutsche Zeitschrift f. Chirurgie, 1893, vol. xxxvii. p. 161.

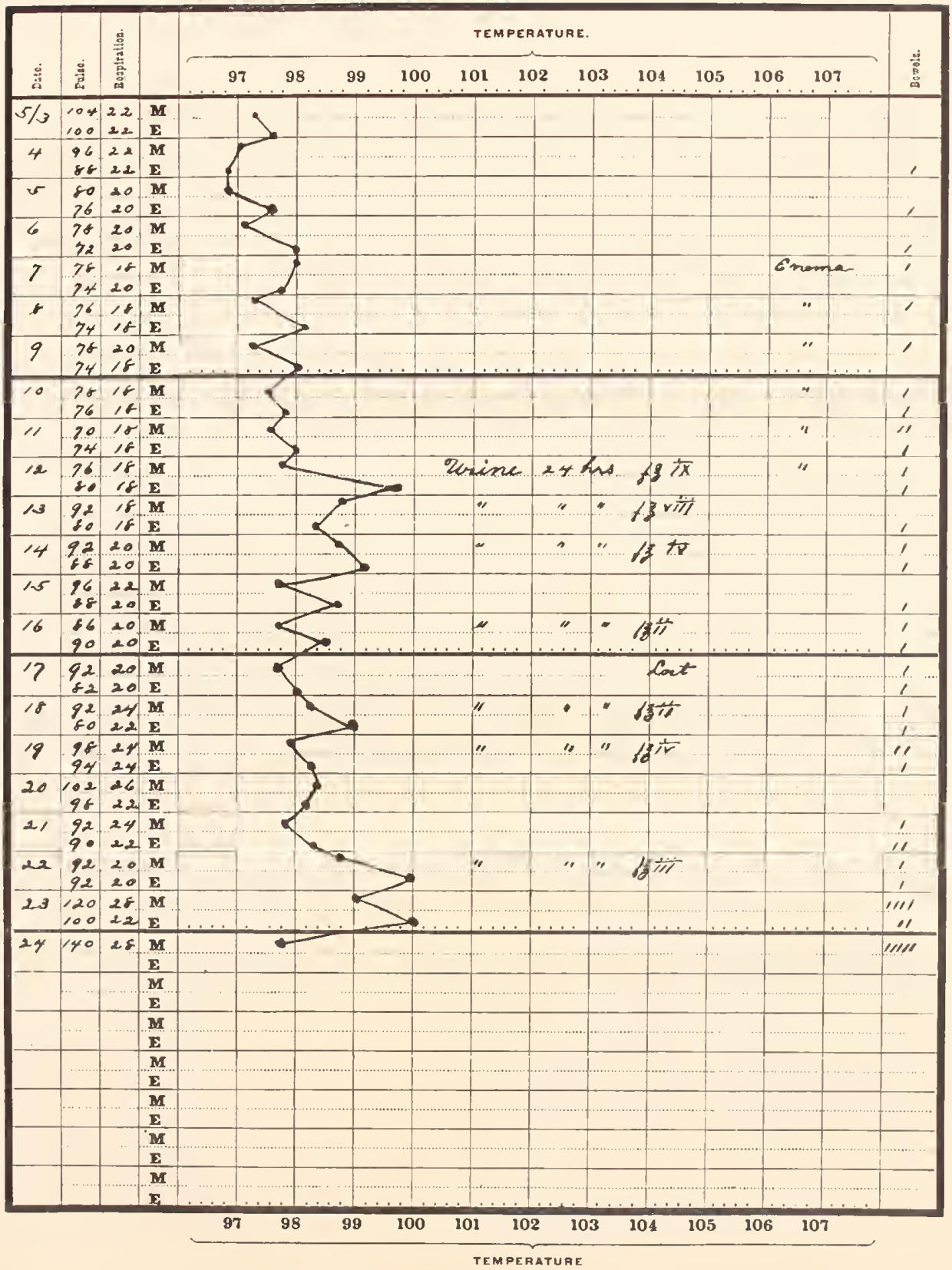
TEMPERATURE.
97 98 99 100 101 102 103 104 105 106 107
Date.
Pulse.
Respiration.
Bowels.
5/3 104 22 M
100 22 E
4 96 22 M
88 22 E
5 80 20 M
76 20 E
6 78 20 M
72 20 E
7 76 18 M
74 20 E
8 76 18 M
74 18 E
9 76 20 M
74 18 E
10 78 18 M
76 18 E
11 70 18 M
74 18 E
12 76 18 M
80 18 E
13 92 18 M
80 18 E
14 92 20 M
88 20 E
15 96 22 M
88 20 E
16 86 20 M
90 20 E
17 92 20 M
82 20 E
18 92 24 M
80 22 E
19 98 24 M
94 24 E
20 102 26 M
96 22 E
21 92 24 M
90 22 E
22 92 20 M
92 20 E
23 120 28 M
100 22 E
24 140 28 M
E
M
E
M
E
M
E
M
E
M
E
M
E
M
E
Enema
Urine 24 hrs
Cat
TEMPERATURE

thinks, are described too briefly or are too complicated to be of much service in determining whether or not lesion of one vagus causes pulmonary disease.

In another case reported by Traumann, one of injury of the hypoglossus and accessorius, bronchopneumonia developed on the second day after the injury occurred, and was attributed to particles entering the lungs. He believes this could not be explained by the unilateral paralysis of the accessorius alone, but was caused by this in association with hypoglossus paralysis. By the paralysis of the geniohyoid and thyrohyoid muscles on one side, the movement of the larynx upward and forward was disturbed.

Adolf Widmer,[1] in 1893, collected the reports of a large number of cases in which the vagus had been divided during operation. According to Widmer, Traube in 1871 showed that division of the vagus nerve in the neck caused pneumonia by paralysis of the larynx and œsophagus, this paralysis allowing saliva and food to enter the lungs. O. Frey (1877) confirmed Traube's statements by numerous experiments, which seem to have been on both vagi. Widmer says that the results of unilateral vagotomy are contradictory; in some cases important pulmonary changes occurred, in others they were absent. The cases in which pulmonary changes occurred after unilateral vagotomy, as reported by Widmer, are of difficult interpretation.

Of nine cases in man in which the vagus was cut intentionally, no alteration of the character or frequency of the respiration was observed in seven; slight change of respiration was observed in one, and the respiration was deep and irregular in one case of difficult interpretation. Widmer concludes that aside from paralysis of the larynx and irritation causing coughing, unilateral vagotomy is a harmless operation so far as the lungs are concerned.

George W. Crile,[2] in his recent paper "On the Effect of Severing and of Mechanically Irritating the Vagi," remarks that in the literature of this subject the clinical reports of the effects of mechanically irritating, dividing, or resecting the vagus are much at variance. His experiments showed that severing one vagus

[1] Deutsche Zeitschrift f. Chirurgie, 1893, vol. xxxvi. p. 283.
[2] American Journal of the Medical Sciences, April, 1902, p. 652.

was attended by comparatively little effect upon either respiration or circulation. Usually there was a slight rise in the blood pressure, and a slight decrease in the frequency of respiration, with an increase in the amplitude. His reports of severing of the vagus in man seem to show that this operation is not usually followed by persisting serious results so long as only one vagus is injured.

The respiratory rate in my case was about normal, but the pathological findings in the lungs were exceedingly interesting in this connection. The left lung was voluminous, and on palpation numerous nodules of increased consistency and averaging 1.5 cm. in diameter were felt. The lung surface appeared congested on section, and small areas of consolidation, dark red in color, with a granular surface and corresponding to the nodules mentioned above, were found in the left lung. Most of these areas resembled the areas of bronchopneumonia, but others showed distinct breaking-down in the centre, with abscess formation. The abscesses were about the size of a split pea. A similar condition was found throughout the middle lobe of the right lung, and the right upper and lower lobes were congested. It seems improbable that this pulmonary condition was caused by the entrance of foreign bodies into the lungs, because the patient was entirely unable to swallow. Saliva, however, doubtless passed into the trachea and carried with it micro-organisms. I tested the patient once with a glass of water, and his choking was so alarming that the attempt was not repeated. He was nourished by rectal enemata, and the stomach tube was passed only on the day before his death. The choking was probably the result of impaired function of the epiglottis. It seems reasonable to attribute the pulmonary condition to the paralysis of the vagus nerve, but these pulmonary lesions were not recognized until a necropsy was obtained forty-six days after the accident. Recovery in some cases is probably reported before the cases have been observed sufficiently long.

Bernhardt[1] quotes Eichhorst as saying that the vagus is the trophic nerve of the heart, and that the lesion of one vagus may cause fatty change in the heart. He says that Masoin, in 1872,

[1] Loc. cit.

and Arloing and Tripier, in the same year, showed by experimentation that the two vagi do not exert the same inhibitory action on the heart, and that the right vagus exerts a more powerful inhibitory action than the left. Eichhorst has come to similar conclusions from experimentation. Bernhardt remarks that in seven cases of vagotomy that could be employed for a determination of the question, reported by Deibel, no remarkable cardiac phenomena were observed. In Traumann's case of injury of the vagus by a bullet, without necropsy, the pulse was 90 to 130 for weeks, although the patient was kept quiet, and after exertion it became 180. The increase in the rapidity of the pulse was not permanent. In the cases of bullet wound of the vagus reported by Demme and Schüller the pulse was rapid. Traumann says that in none of the cases of injury of the vagus by the removal of a tumor has any peculiarity in the beat of the heart been observed. In experiments on animals unilateral division of the vagus has not caused any change in the heart-beat, but bilateral division has produced an increase in the rapidity of the beat.

Blanke regarded the pulse of 90 to 100 in his case of bullet wound of the vagus, hypoglossus, and glossopharyngeus as a vagus symptom, but this case was complicated with pneumonia, and fever existed.[1]

In my case the heart weighed 270 grammes, and on inspection appeared to be normal. The pulse, however, was a little accelerated. The man was kept very quiet, and yet the pulse at times was as high as 104, 96, or 92 when he came under my observation four weeks after the accident. It is a pity that the heart was not preserved for microscopic examination. Only on three occasions, except two days before death, did the temperature rise as high as 99° F., and on one of these occasions it was 99.8° F.

Vomiting was present in Traumann's case of bullet wound of the vagus during the first few days following the accident, and was attributed by Traumann to irritation of the vagus. Vomiting has been observed as a sign of injury of the vagus by Boinet also. It was not present in my case after the patient came under my

[1] Eine Schussverletzung des linken Vagus. Dissertat., Göttingen, 1871. Cited by Traumann.

care, and no mention was made of its having existed previously. The influence of the vagus on the kidneys in man is not well known. In my case parenchymatous degeneration of the kidneys and liver was present, but it is questionable whether this was caused by the degeneration of the vagus nerve.

The distribution of taste fibres to the tongue is still a subject of much dispute. Recent critical studies of this subject are by C. K. Mills[1] and Frankl-Hochwart.[2] The former comes to the conclusion that the glossopharyngeus supplies all parts of the tongue with taste fibres, while the latter concludes that the trigeminus is the nerve of taste to the anterior two-thirds of the tongue in many persons, although not in all. The evidence that the glossopharyngeus supplies the part of the tongue behind the circumvallate papillæ, and including these papillæ, and that the chorda tympani supplies the part in front, seems very strong, but it is still uncertain in what way the taste fibres within the chorda tympani reach the brain. According to some writers (Schiff, Erb, Bernhardt) the taste fibres supplying the anterior portion of the tongue pass by the chorda tympani, the facialis, the petrosus superficialis major, the ganglion sphenopalatinum, the second branch of the trigeminus to the brain. Brücke and Carl (cited by Bernhardt) believe they pass by the ganglion oticum, the petrosus superficialis minor, the plexus tympanicus, the ganglion petrosum, the glossopharyngeus to the brain; still others believe that the portio intermedia, really a part of the glossopharyngeus, conveys the taste fibres from the facialis to the brain. Gowers[3] believes that the trigeminus is the nerve of taste to the entire tongue.

My case may throw some light on this subject. Salt and sugar were promptly recognized on both sides of the anterior two-thirds of the tongue. By some oversight the condition of taste in the posterior third of the tongue was not recorded, but it was probably tested. It is extremely difficult to determine accurately the condition of taste in the posterior portion of the tongue. I can-

[1] The Nervous System and its Diseases. J. B Lippincott Company, Philadelphia, 1898.
[2] Nothnagel's Specielle Pathologie und Therapie, Band i., II. Theil, IV. Abtheilung.
[3] Journal of Physiology, July 21, 1902, No. 4.

not determine whether in this case the taste fibres of the chorda tympani reached the brain through the portio intermedia or the trigeminus, as neither nerve was degenerated and taste in the anterior two-thirds of the tongue was normal. I may, however, assume that the taste fibres from the anterior portion of the tongue could not have reached the brain by the glossopharyngeus, as described by Brücke and Carl, inasmuch as the glossopharyngeus was intensely degenerated, and yet taste in the anterior part of the tongue was normal.

There has been some doubt concerning the condition of the taste buds of the circumvallate papillæ of the tongue after a lesion of the glossopharyngeus. The views of the different investigators are clearly set forth by Frankl-Hochwart.[1] Vintschgau and Hönigschmied found that the taste buds of these papillæ in the rabbit disappear soon after division of the glossopharyngeus, and that after three weeks no taste buds are found in the papillæ foliatæ or in the papillæ circumvallatæ. Their investigations were confirmed by Ranvier, Drasch, Sandmeyer, and Rosenberg; while Benno Baginsky[2] alone has disputed their statements.

From his experiments on nine rabbits he concluded that after division of either the left or the right glossopharyngeus, in young or old animals, the taste buds were not affected, that they neither degenerated nor disappeared, no matter how long the animals lived after the operation. Rosenberg found degeneration of the taste buds in the circumvallate papillæ in a man in whom the glossopharyngeus had been destroyed by a tumor. The taste buds were degenerated on the side on which was the degenerated nerve, but the condition of the taste buds on the other side is not mentioned, although it seems to be implied that they were not degenerated. This is the only case in man that I know of, except my own, in which the taste buds of the circumvallate papillæ were found degenerated after a lesion of the glossopharyngeus nerve.

The taste buds in the circumvallate papillæ in my case had disappeared on the left side of the tongue, but were present though possibly not so numerous as normal on the right side of the tongue.

[1] Loc. cit.

[2] Virchow's Archiv, 1894, vol. cxxxvii. p. 389.

The taste buds probably are not so numerous nor so perfect in a person aged fifty-four years as in a child, but I have obtained for comparison the circumvallate papillæ from a man aged sixty-two years. I must believe, therefore, that the taste buds of the circumvallate papillæ are innervated by the glossopharyngeus. They are not nearly so numerous in man as in preparations from the rabbit loaned me by Dr. G. A. Piersol.

It is uncertain to what extent the trigeminus gives sensory fibres to the soft palate and pharynx. Inasmuch as in my case the pharyngeal reflex on the side of the degenerated glossopharyngeus was preserved, I believe that the sensory distribution of the pharynx cannot be confined to the glossopharyngeus.

The motor innervation of the soft palate has been supposed by many to be through the seventh nerve, and deviation of the uvula is described in facial palsy, but Hughlings Jackson, Gowers, and Frankl-Hochwart dispute the correctness of this opinion. In Traumann's case of bullet wound of the vagus the soft palate was paralyzed on one side, but as the superior laryngeal nerve escaped, the paralysis could not have been a vagus symptom. It was attributed by Traumann to injury of the palatine nerves from the sphenopalatine ganglion. In my case the soft palate was still innervated on the left side, and yet there was a distinct although slight difference between the two sides. A few degenerated muscle fibres also were found in the left side of the soft palate by the Marchi method. I conclude, therefore, that the innervation of the soft palate is, in part, by means of the glossopharyngeus or vagus.

The posterior nucleus of the vagus and glossopharyngeus is usually described as sensory, and yet strong evidence is offered that it is motor. Oppenheim[1] remarks that Forel, von Monakow, and Bruce regard it as a motor nucleus, or at least as the origin of centrifugal fibres. Marinesco has regarded it as a motor nucleus, and van Gehuchten by the silver stain has traced the axis-cylinder processes of the nerve cells of this nucleus toward the periphery of the medulla oblongata. In 1898 I[2] spoke of a

[1] Lehrbuch der Nervenkrankheiten, third edition.
[2] Journal of Nervous and Mental Disease, 1898, p. 677, and February, 1899.

case of amyotrophic lateral sclerosis, in which, in association with Dr. Dercum, I found degeneration of this posterior nucleus, and I remarked that the degeneration of this nucleus in amyotrophic lateral sclerosis suggested that the nucleus was motor in function, inasmuch as in this disease the degeneration is chiefly of the motor system. In my case described in the present paper the cells in the posterior nucleus on the left side were swollen and their nuclei were eccentric. As such alterations as these would not be likely to occur if the nucleus were sensory, because then these cells would not be an integral part of the peripheral fibres, it seems more probable that the posterior nucleus is motor.

There is much doubt concerning the origin of the accessorius. It is commonly spoken of in English and American works on anatomy as the spinal accessory nerve (nervus spinalis ad pneumogastricum accessorius), and the Germans describe it as the accessorius vagi. The nerve fibres innervating the larynx have been supposed to be derived from the accessorius, but Grossmann and Grabower have disputed this. The latter showed by experimentation that the motor fibres of the larynx are contained in the lowest four or five root bundles of the vagus, and that these fibres have their origin in the nucleus ambiguus; whereas the accessorius has only a spinal nucleus. An accessorius vagi, according to Grabower, does not exist, as the ramus internus is a portion of the vagus. This view was held earlier by Holl, and seems to be accepted by most of the recent investigators. Bunzl-Federn, Roller, Darkschewitsch, and Dees believe the accessorius nucleus extends into the medulla oblongata and gives fibres to the vagus.[1] Inasmuch as the distal portion of the vagus roots is associated with the accessorius only for a small portion of its course and becomes a part of the vagus after its exit from the cranium, Obersteiner[2] suggests that it would be well to speak of it as distal vagus roots, and to describe the spinal portion alone as the accessorius.

This suggestion seems to me a proper one, but the name, accessorius, is then hardly suitable. My case shows that the fibres

[1] See Oppenheim. Loc. cit.
[2] Anleitung beim Studium des Baues der nervösen Centralorgane, fourth edition, p. 512.

innervating the laryngeal muscles may be paralyzed by a fracture extending into the jugular foramen, when the fibres supplying the sternocleidomastoid and trapezius muscles escape, inasmuch as paralysis of these muscles was not observed. The nerve-root fibres that were degenerated could not be distinguished from those of the vagus, and it seems to me better to regard the nerve roots having their origin dorsal to the lower olive as belonging exclusively to the glossopharyngeus and the vagus. The association of the lower portion of these roots with the accessorius within the jugular foramen cannot be very intimate, as a fracture passing into this foramen may cause paralysis of the fibres innervating the larynx, while those to the sternocleidomastoid and trapezius muscles escape.

A CASE OF PROBABLE MULTIPLE SEROSITIS.[1]

By M. HOWARD FUSSELL, M.D.,
ASSOCIATE PROFESSOR OF MEDICINE, UNIVERSITY OF PENNSYLVANIA,

AND

HENRY D. JUMP, M.D.,
INSTRUCTOR IN CLINICAL MEDICINE, UNIVERSITY OF PENNSYLVANIA.

MULTIPLE serositis has been described under the name of Zuckergussleber by Curschmann, as pericarditic pseudocirrhosis of the liver by Pick, as indurative mediastinopericarditis by Harris, as polyorrhomenitis by Picchini and other Italian writers, as multiple hyaloserositis by Nicholls, and as multiple serositis by Kelly. The last two terms are the best from the descriptive point of view, and that of Kelly seems to be preferable because it includes many cases in which the process has been identical, but which would have to be excluded under Nicholls' term because of an absence of hyaline degeneration of the serous membranes. The disease is characterized by a progressive inflammation of the serous membranes of the body, namely, pleura, pericardium, and peritoneum, with ascites and little or no œdema of the extremities. The onset, in many cases, has been acute, and in others it has been insidious, and has remained undiscovered for a long time. Its course is long and ascites has been disproportionate to the general œdema. The process is a progressive one, though often latent, the course depending on the serous membrane first affected. Nicholls has divided the cases in his comprehensive monograph on the subject into those with a *primary perihepatitis* and those with a *primary pericarditis.* When Glisson's capsule is the first to be affected the prominent symptom

[1] Read March 4, 1903.

at the onset is ascites, which repeatedly returns after tapping. The liver is large, smooth, and hard, and later becomes contracted. The disease usually attacks the pleura next and then the pericardium. In Nicholls' second division the pericardium is the first serous membrane to be affected, and the only symptoms for some time are those of an adhesive pericarditis. Later the process attacks the right or left pleura, or both, and then the capsule of the liver. The acute symptoms may subside, and the patient may be able to resume his work. Later the œdema of the extremities, which may have been extreme in the first stage, lessens, the liver becomes smaller, its surface irregular, and ascites sets in. Then the great ascites, though prominent in all cases, may not appear until late in the course of the disease.

Various theories have been offered to explain the disproportionate ascites, and these have been very fully discussed by Kelly. The most probable cause is the extension of the process to the peritoneum, and in those cases in which it appears early the peritoneum has been affected early, and in those in which it appears late the peritoneum has been affected late, and the ascites does not appear until that serous membrane has been involved. The case here reported has shown no ascites as yet. It is as follows:

C. B., aged twenty years, negro, single, and porter by occupation, appeared at the University Hospital Dispensary in September, 1901, complaining of a large liver, which he said he had had for a year. With the exception of a brother, who died from abscess, the family history is negative. His previous history includes pleurisy and pneumonia when a baby, and an attack of pleurisy (?) each winter for several years. He has not had diphtheria, scarlet fever, typhoid fever, malaria, influenza, nor any venereal disease. He smokes moderately, but has never used alcohol. He tells us that the present illness began five years ago, with flatulence, diarrhœa, pain in the hepatic region, and œdema of the legs. The œdema comes and goes. Before coming to us he had been in bed for a week, but showed no weakness; bowels moved daily. There had been no jaundice, no loss of weight, and no cough. He had been operated on for hernia of the left side, at which time the left testicle was removed. At his first visit examination showed a small area of dulness at the apex of the right lung, increased cardiac dulness with a pericardial friction rub, no cardiac murmurs, an enlarged and pulsating liver, and a marked pulsation in the suprasternal notch (pulsating anterior jugular vein). There was no ascites, but there was a mild œdema of the legs. In June, 1902, while under our care he had

an attack of acute pleurisy of the left side, with effusion. His condition at the present time is as follows: A well-nourished man, fairly muscular, with no superfluous fat. There is a marked pulsation in the suprasternal notch, which appears to be more frequent than the radial pulse, but is not. There is a marked prominence of the epigastrium and of the right hypochondrium, which reaches to within two inches of the navel. Below this the abdomen is normal in appearance. There are no enlarged veins visible in any part of the trunk. On cessation of breathing the cardiac impulse is visible, but no distinct apex-beat is to be made out. The whole of the precordia is prominent. The impulse of the heart can be faintly felt beneath the nipple, but this is not a distinct apex-beat. Tactile fremitus is greater over the whole right lung than over the left, and at the right apex it is quite marked. The liver can be seen and felt to distinctly pulsate. The lower edge can be felt on a line with the navel on the right side. There is no evidence by palpation or percussion of fluid in the abdomen. The upper border of heart dulness begins at the second rib, left sternal margin, and extends downward to the left one inch outside the midclavicular line and downward to the right one inch outside the sternum. There is dulness at the apex of the right lung as far down as the third rib anteriorly and to the middle of the scapula posteriorly. There is good resonance elsewhere. Liver dulness in the erect position begins at the fifth rib in the nipple line and extends posteriorly in a curved line to the lower angle of the scapula. The lower edge is midway between the xiphoid and the navel, and extends posteriorly in a straight line. Splenic dulness extends from the posterior axillary fold to within two inches of the spine and from the seventh rib down. It cannot be palpated. Auscultation in a reclining posture reveals a to-and-fro friction rub over the body of the heart, which is a little louder in full expiration. This is especially distinct in the region of the normal apex-beat. At the base, in the aortic region, there is a slight rub in diastole, which becomes very distinct at the lower end of the sternum. There are no endocardial murmurs. In the vessels of the neck a slight diastolic sound is heard on the right side, but not on the left. There is a prolongation of the expiration at the apex of the right lung, but no râles.

To sum up, then, we have an enlarged cardiac dulness, with a feeble apex-beat and feeble cardiac impulse; a distinct friction rub marked in the apex region, and distinct, but of somewhat different character, over the sternum; marked jugular pulse, an enlarged and pulsating liver, enlarged spleen, signs of an old lesion (probably consolidation) at the right apex, a distinct history of a left pleural effusion, the absence of any ascites, and a very distinct œdema of the legs. The urine is normal, and the examination of the blood shows no change from the normal.

In considering the diagnosis one must consider, on the one hand, multiple serositis and on the other adhesive pericarditis, with subse-

quent changes in the liver and an intercurrent pleurisy. The fact that the liver pulsates practically rules out primary disease of that organ.

Viewing the disease serositis, so little understood, as successive involvement of the various serous membranes, this case certainly comes under that head, because at least two of the serosa have been affected. The absence of ascites, which has been the predominant symptom in all cases which have come to autopsy, is not sufficient proof that this does not belong to this class, because typical cases of serositis have been reported in which ascites has appeared only after the long continuance of the other symptoms. The latent course of the disease in this case is also in favor of serositis, notwithstanding the œdema of the legs. If this case be one of serositis, and we believe it is, it must be classed as one of *primary pericarditis*, the symptoms of this type being pericarditis, enlargement of the liver, pleurisy, and œdema of the legs primarily, later contraction of the liver, lessening of the œdema, and appearance of ascites. The absence of symptoms referable to the heart, the long continuance of the case, and the presence of a certain inflammation of the pleura make the case as at least probably belonging to the third group of cases of obliterative pericarditis mentioned by Kelly, namely, multiple serositis. The following case, reported by Siegert and abstracted by Nicholls, has many points in common with ours:

Male, aged nineteen years. History of syphilis in the father; measles at the age of four, followed by palpitation of the heart and a sense of oppression; was treated at times for some heart affection. At the age of nine œdema of the legs appeared, with pain in the abdomen and back and increased rotundity of the abdomen. On examination there was considerable œdema of the face, lower extremities, and trunk. The heart dulness was increased to the right, but there were no murmurs; ascites was not recognized. The urine was free from albumin and there was dulness at the bases of both lungs behind; was improved by his stay in the hospital; five months, returned with moderate œdema of the trunk and lower extremities, ascites and hydrothorax. The liver was enlarged, with smooth surface; spleen at no time was palpable. He went about with a varying degree of ascites and œdema until he was readmitted a year later. The ascites was then extreme and the œdema very marked. Heart dulness increased to the right; was attacked by erysipelas and an umbilical hernia developed. He was discharged somewhat improved, and returned eighteen

months later with œdema only slight, but ascites extreme: aspirated. Two and a-half months later a marked friction was felt over the liver. Patient remained fairly well, only complaining of ascites. The liver gradually became smaller. On subsequent aspirations the fluid removed was of a serous character—pale, opalescent; specific gravity, 1005—and contained 3.5 per cent. of albumin. The liver gradually became markedly smaller and its edge thickened and rounded. The spleen was slightly enlarged; osteomalacia and chronic bronchitis developed. The patient finally died of heart weakness after nine years of illness.

Autopsy. Chronic inflammation of the serous membranes, "zuckerguss" liver, chronic deforming perihepatitis, osteomalacia, adhesions of both lungs, bilateral hydrothorax; adhesion of gall-bladder to stomach, and of spleen and stomach to diaphragm. The liver was covered with a white, shining membrane 5 mm. There was complete pericardial synechia; the intestines and kidneys normal; "zuckerguss" spleen, which was but little enlarged. The liver showed brown atrophy, but no cirrhosis.

In regard to the etiology of the disease, Nicholls has suggested that we should look to a germ of relative low virulence for the cause of the proliferative inflammation. He says that the pneumococcus, the bacillus of typhoid, the bacillus coli, and the bacillus tuberculosis are the most likely ones. In this case there is an old consolidation of the right apex, and, while no sputum has been collected and no examination for the tuberculosis bacillus has been made, it is possible that this bacillus has been operative as a cause in this condition.

References.

Curschmann. Deutsche medicinische Wochenschrift, 1884, p. 564.
Harris. Medical Chronicle, 1895, vol. xxii. pp. 1, 87, 178, 250.
Kelly. American Journal of the Medical Sciences, vol. cxxv. p. 116.
Nicholls. Studies from the Royal Victoria Hospital, vol. i., No. 3.
Pick. Zeitschrift für klinische Medicin, 1896, p. 385.
Siegert. Cited by Nicholls, loc. cit.

DISCUSSION.

Dr. F. P. Henry: As I understand the paper just read, multiple serositis is a term applied to coincident inflammation of several serous membranes, especially the pericardium, the pleura, and the peritoneum. In common with all clinicians I have frequently seen cases in which two of these membranes, the pleura and the pericardium, were involved. It is quite as common to see inflammation of the pleura extend to the peritoneum

through the diaphragm, or, *vice versa*, from the peritoneum to the pleura, especially if such inflammation be chronic and tuberculous. In fact, I am accustomed to look for such extension. If three membranes, instead of two, were coincidently involved, I would regard the case as unusual, but would hardly consider myself justified in making it the basis of a separate classification.

Dr. A. O. J. Kelly: When we undertake to discuss a diseased condition, it is essential that we have in mind the same thing, that the terms which we use are interpreted alike by each one of us; and when we speak of multiple serositis it is essential that we mean one and the same diseased process. If by multiple serositis we mean an inflammation of more than one serous membrane, the case reported by Drs. Fussell and Jump is unquestionably of this character, and so also are the cases reported as cases of mediastinopericarditis and polyorrhomenitis. My interest in the subject was aroused by a case of ascites, originally thought to be due to cirrhosis of the liver, but found at the necropsy to be associated with obliterative pericarditis, and not with cirrhosis of the liver—a symptom-complex described by Pick under the designation pericarditie pseudocirrhosis of the liver. Now, as I pointed out in the paper that I had the honor of reading at a meeting of the College last year for purposes of study, cases of chronic adhesive or obliterative pericarditis may be divided into three classes: (1) cases in which the pericarditis runs its course entirely devoid of symptoms; (2) eases in which, sooner or later, symptoms of disturbed cardiac action manifest themselves, and in which from the physical signs the obliterative pericarditis is more or less susceptible of diagnosis; and (3) cases characterized clinically by marked ascites with little or no œdema of the legs; cases in which the diagnosis of cirrhosis of the liver is usually made and which at the necropsy reveal chronic obliterative pericarditis and certain morbid changes in other tissues and organs, notably pleuritis, peritonitis, perihepatitis, etc. It was the third class of cases that was especially the object of my study. For the time being, however, I should be inclined to classify the case reported by Drs. Fussell and Jump with the second of aforementioned groups. It does not even remotely suggest cirrhosis of the liver; the clinical symptoms from the beginning have those of failing heart power—œdema of the legs, enlarged pulsating liver, pulsating jugulars, etc. This is, if I can so express it, the more common symptom-complex of obliterative pericarditis—that suggesting cirrhosis of the liver being the rarer. The special interest in the rarer cases centres in the interpretation of the ascites, which has been variously ascribed, but which a careful study of the question leads me to believe is to be interpreted as a manifestation of a peculiar form of serositis—peritonitis. Drs. Fussell and Jump's case, however, is a case of multiple serositis—pleuritis and pericarditis (if you choose, mediastinopericarditis)—and it well exemplifies the fact that the initial lesion in this progressive multiple serositis may be

in either the pericardium, the pleura, or the peritoneum. Should the heart in this case regain its power and continue to perform its functions for a number of years, one might conceive the possibility of the peritoneum becoming involved and of ascites becoming the predominant clinical manifestation. But this is scarcely likely. I should be inclined, therefore, to look upon the case as an example of the more common cases of adhesive pericarditis, with an associated pleuritis and consecutive changes in the liver, spleen, etc., the consequence of failing heart power.

REPORT OF A CASE OF SUTURING THE OMENTUM TO THE ABDOMINAL WALL (TALMA) FOR THE RELIEF OF ASCITES DUE TO CIRRHOSIS OF THE LIVER, TWENTY-ONE MONTHS AFTER OPERATION.[1]

By THOMAS R. NEILSON, M.D.

The case which I desire to put on record in this communication came under my care as a private patient at the Episcopal Hospital in June, 1901, having been transferred to me for operation by my friend and then colleague, Dr. D. D. Stewart. I candidly admit that both because I was not especially favorably impressed with the results as they appealed to me at that time, of the Talma operation for the relief of ascites due to cirrhosis of the liver, and because of the rather rapid course of the case, I entertained grave doubts as to the prospect of any benefit to the patient from operation, and was rather reluctant in consenting to do it.

I desire to express my obligation to Dr. F. W. Sinkler, who was my resident at the time of operation, for his care in observing and noting the condition of the patient while he was in the hospital and for some time after his discharge.

The patient, Mr. G., a large-framed man, aged fifty-one years, was admitted to the hospital, under Dr. Stewart's care, on May 25, 1901. For some ten years he had been in the habit of taking freely of alcoholic drinks. There was nothing else in his history in any way connected with the development of cirrhosis of the liver.

Until April 1, 1901, he had good health, but at that time was taken ill, suffering from weakness of the back and legs, inability to stand, and severe lumbar pains, and was obliged to take to his bed. Marked jaundice appeared and ascites gradually developed, accompanied by œdema of the

[1] Read April 1, 1903.

feet, legs, and scrotum. There were hæmatemesis and epistaxis on several occasions. The urine contained bile. The patient was under the care of two physicians before coming to the hospital, and was twice tapped—first on April 29, four weeks after the beginning of his illness, when one and a quarter bucketfuls of fluid were removed, and again on May 23, the amount then obtained not being stated. Paracentesis was done a third time at the hospital, June 6, when two and three-quarter gallons of clear, straw-colored fluid were removed.

No improvement followed this, and, the fluid rapidly reaccumulating, Dr. Stewart transferred the patient to me for operation on June 16. For two days before that the patient was delirious, restless, and greatly excited, requiring the administration of morphine to quiet him.

When he came under my care the patient was in this condition: There had been some loss of flesh; the skin was slightly jaundiced and muddy; conjunctivæ tinged somewhat yellow. Thorax: heart apex-beat in the fifth interspace, one and one-half inches outside of midclavicular line; aortic and mitral systolic murmurs. Lungs normal. Abdomen tense and greatly distended, superficial veins prominent. Slight infection of the skin around wounds made by trocar, probably caused by patient scratching them. The liver, as outlined by percussion, apparently extended from the upper border of the fifth rib to about an inch and a half below the costal margin. Palpation was, of course, not possible under the circumstances.

The spleen was slightly enlarged and pushed upward, the dulness extending from the sixth to the ninth ribs.

The scrotum, in which on the left side there was a hernia, was œdematous. There was no œdema of the legs at this time.

Urine clear, pale yellow in color; specific gravity, 1012; alkaline; no albumin, no casts.

In view of the infection of the trocar wounds found, and of the risk of peritoneal contamination in the case at the time of operation I might find it expedient to evacuate the fluid by tapping in the lower part of the abdomen, I decided not to operate, if the patient remained fairly comfortable, until the infection was overcome and the skin soundly healed.

Operation on June 22, 1901, under ether anæsthesia. A three-inch incision was made through the right rectus muscle from a point a little above the level of the umbilicus. After opening the peritoneum a large amount of ascitic fluid was forced out of the wound, the patient being turned on his side to aid in its escape, and when it ceased flowing a considerable quantity more was removed by mopping up by means of gauze sponges inserted into the abdominal cavity. When no more fluid could be removed in this way, I explored the liver and found it markedly cirrhotic, hard, and its surface rough, "hob-nailed." Its anterior border reached considerably below the costal margin, and the finger could easily be passed

between the convex surface of the organ and the diaphragm. The spleen was found to be decidedly enlarged. With a gauze sponge the surfaces of the liver and spleen and the parietal peritoneum opposed to them were thoroughly rubbed, as was the peritoneum for some distance on either side of the wound. The omentum, which contained numerous much enlarged veins, was then brought under the wound and by means of silk sutures was stitched to the peritoneum at a distance of two and a half to three inches from each side of the wound, and also close to the margins of the latter, care being taken to avoid wounding with the needle any of the omental veins. The peritoneum was closed by a continuous suture of catgut. Interrupted sutures of silkworm-gut were introduced through the rectus and its sheath, and between them the sheath was approximated by fine silk sutures. Two or three silk sutures brought the skin into accurate approximation between the silkworm-gut sutures. The dressing was secured in place by adhesive straps firmly applied and a scultetus flannel bandage tightly secured.

Drainage was not employed, in conformity with the belief that it is a source of risk always to be avoided when possible.

The progress of the case after operation was excellent. There was entire freedom from abdominal symptoms, and at no time since, up to the present day, has there been the slightest evidence of return of ascites. On several days during the first three weeks the temperature rose somewhat above the normal, with, however, no symptoms of abdominal disturbance. A small stitch abscess at the lower part of the wound was discovered and opened on the thirteenth day. The pulse was good throughout, ranging from 80 to 104. The action of the kidneys was carefully watched, and during the first fortnight the urine was examined at intervals, the reports showing that, beyond a slight trace of albumin on one or two occasions, there was nothing of note abnormal.

As to medicinal treatment, the patient was given, at different times, tincture of digitalis in small doses, infusion of juniper for a few days, a mixture of sodium phosphate, sodium sulphate, and sodium bicarbonate (which he had been ordered while under Dr. Stewart's care), and, lastly, Basham's mixture and strychnine, together with a mild laxative pill.

On the thirtieth day after operation the patient, who was then feeling well, having a clear skin and conjunctivæ and good appetite and digestion, was allowed to sit in a chair for the first time. Two days later he took a short walk on the hospital grounds, and on the second day after that (July 26), thirty-four days after operation, he was discharged, his general condition being noted as "excellent."

Dr. F. W. Sinkler kept in touch with the patient for some time after his discharge, and at intervals made notes of his condition. The latter show an uninterrupted return of health, with steady gain in strength and weight and no ascites.

On October 29, the note states that there had been a gain of twenty-three pounds in weight; the general condition was excellent; appetite good; patient sleeps well; bowels move regularly without laxatives, upon which the patient had been obliged to depend for some years previously. Examination of the liver showed that its anterior margin was an inch and a half below the costal border in the right nipple line, three and a half inches below the ensiform cartilage, and that it did not extend beyond the costal border in the left nipple line.

On March 24, 1903, the patient reported to me and stated that he is enjoying perfect health. He looks to be perfectly well, his skin is in good condition and clear; he is well nourished, his tongue is clean, digestion good, and his bowels move regularly. He now weighs 185 pounds. There is not the slightest evidence of ascites found. The anterior border of the right lobe of the liver extends about two inches below the costal margin.

An examination of the urine made on March 31, by Dr. A. A. Ghriskey, shows it, with the exception of a faint trace of albumin found in both morning and evening specimens, to be free from anything abnormal.

I have delayed reporting this case in order to permit the lapse of sufficient time since the operation to be able to judge of the permanency of its results. It gives me much pleasure to be able to show the patient now in good condition and feeling perfectly well in the twenty-second month after operation. The improvement is apparently permanent, and the object sought by surgical intervention—the relief of ascites—has been accomplished.

The operation, first proposed by Talma, of Utrecht, has for its aim the establishment of anastomoses between the vessels of the omentum and those of the abdominal wall by fixation of the omentum to the peritoneum, thereby affording relief to the obstructed portal circulation in cirrhosis of the liver, in addition to that insufficiently given by the anatomical anastomoses between the portal and systemic circulations.

It is not my purpose to enter, in connection with this report, into a consideration of the pathology of the ascites of hepatic cirrhosis, nor to review at length the literature, now quite abundant, of the operation of Talma.

Upward of two years ago, in January, 1901, our late Fellow, Dr. Frederick A. Packard, and Dr. Robert G. Le Conte read before the College of Physicians a very comprehensive and well-considered paper on "The Surgical Treatment of Ascites Due to Cirrhosis of

the Liver, with Report of Two Cases" (*American Journal of the Medical Sciences*, March, 1901). The results in their cases were unfortunate, one dying in four days of uræmia, and the other in sixty-one days of toxæmia due to the atrophic condition of the liver. Twenty-two cases collected from literature up to date of this paper were analyzed.

Since that time foreign literature, as well as that of this country, has received many additional contributions of reports of cases and a number of papers analyzing the results to the time they were written.

An excellent paper by Greenough on "The Surgical Treatment of Cirrhosis of the Liver, with a Summary of Cases," appeared in the *American Journal of the Medical Sciences* for December, 1902. From this we get the latest statistics of the Talma operation. The writer collected 122 cases, but very properly deducts from this total those, 17 in number, in which the operation was done for ascites due to conditions other than cirrhosis. For the remaining 105 cases he gives the following result "Thirty-one (29.5 per cent.) died within thirty days of the operation; 44 reported improved or slightly improved after the operation (42 per cent.), and 29 (27.6 per cent.) showed no improvement. One case could not be traced." "Thus," he says, "60 cases (57.1 per cent.) obtained no benefit from the operation." Of the cases included in this summary nine were living and improved two years after operation.

The case now reported is to be included, therefore, among those showing continued benefit a considerable time after the operation.

CASE OF CIRRHOSIS OF THE LIVER, WITH ASCITES; SUTURE OF THE OMENTUM TO THE ABDOMINAL WALL; NON-RECURRENCE OF THE ASCITES AFTER TWO YEARS.[1]

By HENRY M. FISHER, M.D.,

AND

W. W. KEEN, M.D.

The following case is put on record for the reason that this method of treatment is now upon trial, and every successful or unsuccessful case should be reported:

MEDICAL HISTORY BY DR. FISHER.

On December 31, 1900, I was called to see Antonio E., aged thirty years, an Italian fruit dealer. In Italy, for a number of years, he had been in the habit of drinking wine to excess, and since he came to America, seven or eight months ago, he had added the habit of drinking raw spirits in the morning. He had for some months suffered from various digestive disturbances, nausea, and occasionally vomiting and irregular action of the bowels.

In September, 1900, three months before I first saw him, he had an attack of severe pain in the epigastric region, lasting for several hours and accompanied by profuse diarrhœa. Following the subsidence of this pain slight swelling of the abdomen was noticed for the first time. This disappeared, however, in a few days. Two nights before my visit, December 29, 1900, he had suffered from another unusually severe attack of vomiting, and the day before had vomited a considerable amount of blood, chiefly dark in color and in clots. Later in the day and during the night he had numerous tarry stools. After this the discharge of blood by vomiting and by the rectum ceased. He was quite pale, and there were some fine

[1] Read April 1, 1903.

moist râles over the base of his right lung. His spleen was considerably enlarged. His heart sounds were clear; his urine was not albuminous.

He was given some subgallate of bismuth, peptonized milk, and beef juice. As no stool had occurred by January 1st, Carlsbad salts was ordered. On January 4th distinct ascites was noted for the first time. There was also much meteorism, the liver was markedly contracted, and the splenic enlargement still greater. The urine was normal.

Two or three days later he was tapped on account of the rapidly increasing ascites. Two gallons of clear serum were removed. On February 12th he was tapped a second time and three gallons of fluid removed. He had never had jaundice.

SURGICAL REPORT BY DR. KEEN.

On February 24, 1901, at the request of Dr. Fisher, the patient was admitted to the Jefferson Medical College Hospital. On admission there was great ascites, he was extremely weak, his appetite was fair, tongue clean, bowels regular, heart and lungs normal. His usual weight is 152 pounds; present weight, 164½ pounds. His urine was turbid, sp. gr. 1028, acid reaction, no albumin or sugar, urea 2.4 per cent. By the microscope there were found amorphous urates, a few leukocytes, but neither crystals, pus, blood nor casts.

Operation, February 27, 1901. An incision in the middle line half-way between the umbilicus and the ensiform gave exit to perhaps two gallons of fluid. I introduced my hand into the abdominal cavity, and determined, first, that the spleen was greatly enlarged; secondly, the liver was greatly shrunken, to at least one-half of its natural size; the omentum was shrunken, but there was no evidence of malignant disease. I then introduced a large gauze sponge and with it scrubbed the upper surface of the liver and the under surface of the diaphragm; then I treated the spleen and its corresponding parietal peritoneum in a similar manner; then the anterior surface of the omentum and the corresponding belly wall. I next passed celluloid thread sutures, two on each side of the opening, through the omentum and the internal surface of the abdominal wall, drawing the omentum tight against the belly wall by these four sutures. The operative incision was then closed by silkworm-gut sutures, four of which caught the omentum as additional security.

On the day after the operation his temperature rose to 102°, but reached the normal by gradual descent at the end of five days. He had to be tapped again on March 8th, when one and one-half gallons of fluid were removed. From March 10th to 18th his abdominal girth increased from 38 to 41 inches; on March 22d three gallons of fluid were removed, and on April 1st three gallons more. It is worthy of note that the early return of the ascites, requiring tapping nine days after the operation, did not prevent firm closure of the abdominal wound.

As he was very anxious to go home for Easter, I allowed him to leave the hospital on April 4th, with a normal temperature and with only a moderately distended abdomen.

LATER HISTORY BY DR. FISHER.

After leaving the hospital he consulted another physician, who informed me that frequent tappings were necessary—about once in two weeks. Later he was lost sight of for several months. I saw him again in the autumn of 1902, and learned there had been no reaccumulation of the fluid and no necessity for tapping, therefore, for over a year—that is to say, since August 1, 1901.

His color has improved and he is out and attending to his fruit business. The spleen, however, has increased considerably in size and now reaches nearly to the crest of the ilium. He also has some discomfort in the splenic region. He is still troubled by flatulent dyspepsia and eats but little, owing to his dread of painful distention after eating.

DISCUSSION.

Dr. W. W. Keen: This operation was done on February 27, 1901, and it is now, therefore, twenty-five months since the operation. It was practically the same as described by Dr. Neilson. There was a median incision and attachment of the omentum on each side. In closing the median incision the omentum was caught up by the stitches as they were passed through. The man is now in good health.

Dr. Frazier: In connection with the subject of the operative treatment of hepatic cirrhosis, the Fellows of the College might be interested in the report of a case which I operated upon in July, 1900. The patient was a laborer of middle life, who was admitted to the University Hospital in May, 1900. He was a free user of alcohol. His heart, spleen, and liver were enlarged; the upper margin of the liver was on a level with the fifth rib, and the lower border could be felt below the costal margin. The administration of digitalis, caffeine, diuretin, urea, and other diuretics had no appreciable effect upon the ascites. Paracentesis was practised at intervals of about two weeks, on which occasion 512, 485, 330, and 400 fluid-ounces, respectively, were withdrawn. The case was regarded as a hopeless one, and, at my suggestion, the patient was transferred from Dr. Tyson's ward to the surgical service. I performed Talma's operation July 25th, beginning with local anæsthesia, but finishing under general anæsthesia on account of the pain attending manipulation of the peritoneum. Subsequent to the operation it was necessary on two occasions to practise paracentesis; on the first occasion, thirteen days after the operation, 328 fluid-

ounces were withdrawn; on the second occasion, thirty-six days after the operation, 96 fluidounces were withdrawn. From that time to the present, now almost three years, there has been absolutely no reaccumulation of fluid. The patient gained rapidly in strength, and was soon able to resume his occupation as a laborer.

The case which I have just alluded to is, I believe, the first successful one to be recorded in American literature. While I am convinced that the operation is justifiable only under certain conditions, I believe that one receives an altogether erroneous view as to the prospects of success in his perusal of the literature upon this subject. Probably for every favorable case which has been reported there are five or ten unfavorable cases which never find their way into medical literature. As for my experience, I must admit that this is the only successful case upon which I have operated. Of three other cases upon which I practised this operation, one died as a result of the operative intervention, and the other two were discharged from the hospital without any apparent benefit.

Dr. W. W. Keen: I think the ultimate result is the point that we want. Hospital patients frequently are not accessible after leaving the hospital, and in this case I was very fortunate, through the kindness of Dr. Fisher, in being able to learn the final result. The operation was in February, and the man had to be tapped up until August. Collateral circulation was established slowly, but the result shows that it has been established fully, and the final outcome is an excellent one. I think we ought not to draw our inferences for at least a year, if not until even a longer time.

THE RELATION OF NEURALGIC HEADACHES TO STORMS.[1]

By S. WEIR MITCHELL, M.D.

It is interesting to call attention to the fact that the only scientific studies of the relation of disease and pain to the weather have been made by Fellows of this College. Among these are my own essays on traumatic neuralgia, aided by Captain Catlin; Morris Lewis' and my own examination of choreas as related to storms; Wharton Sinkler's paper on "The Causal Relation of High Temperatures to Infantile Palsy"; Morris Lewis on "Acute Rheumatism and Storms"—a model paper. I should add Mills on "Choreas," and many minor studies of my own, where efforts were made to determine how far the pain of posterior sclerosis is due to weather.

I desire at present to call attention to the connection between neuralgic headaches and storms. I have many times tried to induce patients to accumulate for me material for such a study, but so far I have failed.

It is rare to find a sufferer both as able and as willing to deal scientifically with his case as was Captain Catlin. His charts now lie on the table to remind you of a study unique in medical research.

The originative causes of hemicrania are as yet unknown. The determining causes of the separate attacks have never yet been made so clear as to enable the victims to avoid them by precautionary measures.

I asserted long ago that eye-strains are rarely the primary trouble, but may add to the number and exaggerate the force of attacks. I

[1] Read May 2, 1903.

have seen no reason to change my belief. Freedom from fatigue, or, rather, from exhaustion of mind and body, is most apt to lessen the number of headaches; hence changes of place and consequent idleness are likely to relieve for a time, and so also is whatever permanently lifts the level of general health. We see this very often when, after a successful rest treatment, the customary headaches vanish or become rare.

Among the influences which produce this form of pain it is very probable that atmospheric conditions have a potent share.

As in traumatic neuralgia, so in headaches, it is only required to come within the outer limits of storm conditions. The sky may be cloudless and the rain or cloud areas two or three hundred miles away, and yet the sufferer be within the area of barometric depression.

I have at different times been able to assure myself that certain migraines were due to storms, but not, as a rule, to the summer electric storms, which, however, in some hysterical women are sure to occasion a general headache, distinct in character from hemicranial attacks.

I shall not trouble you with details of cases, nor do more than observe that in two of them the subjects, who were physicians, became well assured that the months of storm frequency were those in which they suffered most often and most severely.

Mr. H., of Maine, aged thirty-nine years, manufacturer, when twenty-three years of age began to have hemicrania and pain at intervals, which, at first long, became more and more brief. The pain was preceded by the sense of being unusually well. Commonly for three mornings he awakened with slight transient pain, resulting, at last, in a violent left-side migraine, with vomiting. There were no eye troubles, paresis, or aphasia. The headache was followed by the usual free flow of pale urine; in other words, it was a typical case of hemicranial neuralgic headache without notable flushes or pallor. It had one rare, but not exceptional, symptom—an ache in the left crural region, with benumbed sensations. There was no ill health; all the organs were sound; all secretions normal.

For seven years this gentleman kept a record of his attacks and of the means used to aid him. As usual, I asked, "What will cause an attack? What will make attacks severe?" To this he answered, "Overwork, fatigue, much worry or anxiety, severe storms, but not electric storms."

The conditions favoring freedom from pain were absence from home and relief from work.

Dr. Alfred R. Allen has been so kind as to make a curve representing the relation of this man's headaches to the time of year.

As the storm curves of the eastern coast vary little from New England to the Chesapeake, I have set below the pain curves the storm curves of our own locality for three years.

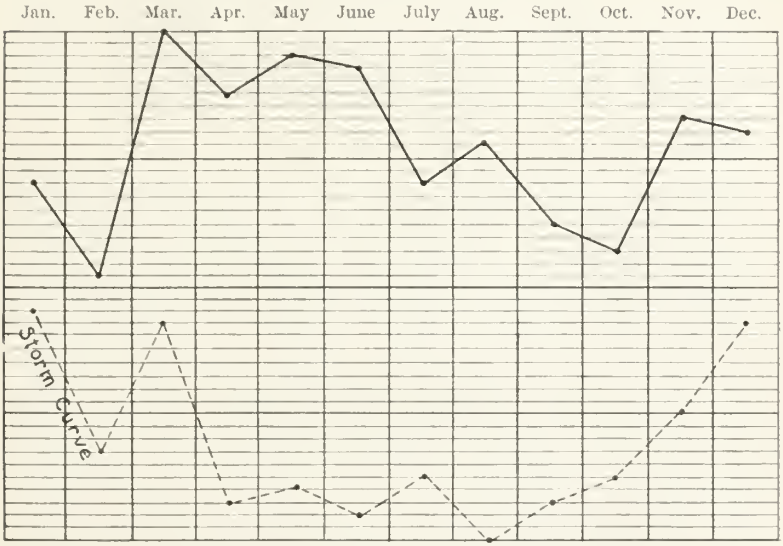

Monthly average of headaches for seven years (1893-1899).

In the well-known case of Captain Catlin, he finally satisfied himself that 95 per cent. of the onsets of a traumatic neuralgia were thus occasioned. It was not needed that there should be rain. To get within the area of low barometer, rising temperature and increasing moisture were sufficient. The sky might be clear and the day altogether pleasant, and yet storm conditions exist.

As Mr. H. was at times away from home during a month, the pain curves may be thus modified; nor is it possible to be secure of our conclusions until a number of persons shall have kept note of their headaches for two or more years. Nevertheless even the small knowledge we here gain is valuable.

You will see how the pain curves crudely follow the storm curves; also, how close it is to the chorea curve, which is so clearly related to the storm curve.

March and April are the worst months and October and February the best. If we could add a curve of business worry and of other causes of anxiety, it would further assist us.

The books have many statements concerning the relation of weather to headaches. It is needless to state them in detail, since, for the scientific study of this matter, the term "headache" is used too vaguely. There is, however, among the later writers a quite general belief that the storm winds favor the production of headaches.

Since, in the books, much is said of barometric pressure as determining headaches, it may be well to state that in Catlin's case low barometer alone had no tendency to bring on his form of neuralgia, and I incline to the belief that the grouped atmospheric conditions which constitute a storm will be found to be in hemicrania, as in traumatic neuralgia, essential to the causation of migraine. It is a question of practical moment and should be readily settled.

Our problem is this: Given a human instrument capable of evolving a group of symptoms, of which pain is the most surely present, what are the agencies which evolve attacks? How far are climatic conditions responsible?

Many of the Fellows must see cases of habitual migraine. If some of these patients could be induced to note on a calendar the dates of headaches during two years, the question of connection between storms and this kind of pain could be surely ascertained. For obvious reasons men should be chosen rather than women.

SUCCESSFUL INTRANEURAL INFILTRATION OF THE MEDIAN AND ULNAR NERVES DURING AN OPERATION FOR DUPUYTREN'S CONTRACTION OF THE FINGERS.[1]

By W. W. KEEN, M.D.,
PROFESSOR OF THE PRINCIPLES OF SURGERY AND OF CLINICAL SURGERY, JEFFERSON MEDICAL COLLEGE, PHILADELPHIA.

THE following case is reported to show the value of neural infiltration with cocaine in a case in which general anæsthesia would have been dangerous. The effects were no less gratifying to the patient than to the surgeon. The anæsthesia was absolute and lasted for nearly an hour:

Miss H. N. B., aged sixty-two years, Sugartown, Pa., entered the Jefferson Medical College Hospital May 20, 1903.

Her father died of enteric fever, her mother of old age; one sister is living and well, another died of tuberculosis of the lungs; seven other brothers and sisters are dead of unknown causes; one of her sisters has rheumatic gout.

For a number of years she has suffered with catarrhal gastroenteritis, but at no time has she been compelled to go to bed. She has also a troublesome chronic bronchitis. For the last twelve years she has had attacks of pain and stiffness involving the left shoulder, her knee, and finger-joints. She has a distinct cardiac murmur with the first sound of the heart, due to former attacks of rheumatism or gout, and she has gouty eczema. She is feeble far beyond her years, and very nervous about her heart and lungs.

About six years ago, without any known cause, a small lump formed on the palmar aspect of the left hand, involving the middle and ring fingers. After three or four years, contraction of the fingers began. Eight months ago the flexion extended to the second joints, and now the tips of these fingers are almost buried in the palm of the hand. Her little finger has been flexed for several years, but there is no cord in the palm. Corresponding to the middle and ring fingers are two marked cords in the palm.

Urine turbid, amber, 1.015, acid, a faint trace of albumin, no sugar, urea

[1] Read October 7, 1903.

1.6 per cent. By the microscope amorphous phosphates and urates, squamous epithelium, and a few leukocytes.

In view of the condition of her heart, her chronic bronchitis, and her general feeble health, I decided to use intraneural infiltration rather than a general anæsthetic.

Operation May 23, 1903. I first infiltrated the tissues over the median and ulnar nerves at the wrist, in a few minutes exposed these two nerves, and injected about twelve or fifteen drops of a 1 per cent. solution of cocaine into each one. In a few minutes I began the operation in the palm of the hand, making two incisions, one from the first interphalangeal joint beyond the knuckle of the middle finger nearly up to the wrist in the line of the cord. A similar incision was made corresponding to the ring finger and its cord. The two contractured cords of the palmar fascia were then exposed by dissection and excised. The extension of the contracted cords on to the second phalanx of each finger was also thoroughly severed. In spite of this, however, while the knuckle joints could be almost entirely extended, the second phalanges could not be placed entirely in a straight line, but were in nearly semiflexion. The incisions were then united by silk and the hand placed upon a straight splint which extended to the partially flexed fingers. The operation required a more than usually careful dissection, so that it lasted nearly fifty minutes. At no time did she suffer the slightest pain.

She had no rise of temperature after the operation, the sutures were removed in a week, and her fingers could be fully extended at the knuckles, but were still slightly contracted at the second joints.

MERCURIAL NEPHRITIS.*

By JOHN M. SWAN, M.D.,
DEMONSTRATOR OF OSTEOLOGY, UNIVERSITY OF PENNSYLVANIA; PATHOLOGIST TO ST. MARY'S HOSPITAL; INSTRUCTOR IN CLINICAL MEDICINE, PHILADELPHIA POLYCLINIC.

(From the Chemical Laboratory, Medical Department, University of Pennsylvania.)

In the concluding paragraph on the subject of mercury, H. C. Wood[6] says that "It appears to be established that certain disagreeable and, perchance, serious effects may be produced by mercurials when freely and continuously used in the treatment of syphilis, against which the practitioner must be on his guard. The most important of these is nephritis with its consequent albuminuria."

The case which serves as the basis of this study illustrates in a striking manner the serious results of the overadministration of mercury.

The patient is a widow, aged thirty-one years.

Family History. Her father is living, at the age of seventy-four years; he complains of symptoms that point to the disturbances due to the uric acid diathesis, and recently has shown the early indications of posterior spinal sclerosis; at the age of thirty years he had an attack of psoriasis. Her mother is living and suffers from chronic gastric disturbance. One brother died of cholera infantum. Two sisters are living and in good health. One of these sisters has four daughters, each of whom suffers from periodic attacks of psoriasis. Her paternal grandfather died at the age of forty-two years, of cerebral hemorrhage; her paternal grandmother died at the age of eighty-seven years, of an unknown cause. Her maternal grandfather died at the age of fifty-two years, of cerebral hemorrhage; her maternal grandmother died at the age of thirty-seven years, of enteritis.

In April, 1898, the patient noticed an eruption which first appeared on her arms and face, but which disappeared under treatment in about four months. In February, 1900, a similar eruption appeared, first on her face,

* Read November 4, 1903.

whence it spread until it involved her entire body. At that time the eruption was associated with gastric pain, and she was put on a restricted diet, so that in six months the eruption disappeared. A similar eruption appeared again in February, 1901. The eruption, at this date, first made its appearance on her face, and then spread until it involved her entire body. The eruption persisted until October, 1901, at which time she consulted a dermatologist in another city, who told her that it was due to syphilis. She was then put upon a mixture containing $\frac{1}{32}$ grain of mercury biniodide and 15 grains of potassium iodide, which she took three times a day. In addition to this she took $\frac{1}{4}$ grain of the yellow iodide of mercury four times a day, and 2 drachms of mercurial ointment by inunction daily. The first prescription she used during October and November; the others she used during October, November, December, and January. During the time she was on this treatment she complained of soreness of the teeth, salivation, running at the nose, pains in the legs and in the abdomen, nausea without vomiting, and occipital headaches. Her bowels were loose and she passed two semisolid, fetid stools daily. The pains in her legs were cramp-like and deep-seated; they were paroxysmal in character and worse at night. These symptoms came on about four weeks after treatment was begun, which was then stopped for a week. At the end of this time the symptoms had disappeared and she began to take the medicines again, and continued taking them for about three weeks longer, until the same symptoms reappeared. The administration of the medicines was again stopped until the symptoms disappeared, after which she was told to begin taking them a third time. On February 23, 1902, she began to complain of œdema of the feet, legs, and thighs, of occipital headache, and of pain in her eyes when they were exposed to the light. At that time she noticed that she was frequently passing a small quantity of urine at short intervals. About one week later she began to complain of dyspnœa and precordial pain. This pain was stationary, and was increased by movement and by deep inspiration. In January, 1902, she was confined to bed for a week on account of universal pains, suppression of urine, and vomiting.

On March 2, 1902, the patient returned to her home in Philadelphia on account of dyspnœa, pain in the precordium, œdema of the lower extremities, and partial suppression of urine. She then had an eruption of small, scaly patches, most marked on the back; but also visible on the thorax and abdomen, the arms, the legs, and the face. Her pulse was 96 per minute, small, weak, but regular. Her heart's action was rapid, the sounds were deficient in muscular quality, but no murmurs could be detected. Her urine was acid in reaction, had a specific gravity of 1014, and contained 1.4 per cent. of albumin by the Esbach method. Microscopically the urine was found to contain large numbers of hyaline casts, renal epithelium, and leukocytes. The examination of the other organs showed no evidences of disease.

On account of the fact that a dermatologist in another city had diagnosed the skin eruption of which the patient complained as syphilis, I thought that the renal condition was due to syphilis. Cases of syphilitic nephritis have been reported, particularly one recently by Hoffmann and Salkowski,[1] which were cured by mercurial inunctions; and one reported by Mülig[11] which was cured by hypodermic injections of mercuric chloride. Hoffmann and Salkowski have no doubt that the syphilis caused the nephritis in their patient, which was indicated by urine containing hyaline casts and 7 per cent. of albumin. They also believe that the mercury cured the kidney condition; in fact, their patient, five months later, had a return of his syphilitic eruption and albuminuria with casts, which was again apparently cured by mixed treatment. Waldvogel[3] has also recently reported a case of nephritis due to syphilis which was cured by mercurial inunctions. This author, however, points out the difficulties in demonstrating absolutely that nephritis is due to syphilis in a given case.

In 1901 Ferras[18] published a thesis entitled "Studies on the Nutrition in Syphilitics by the Chemical Analysis of the Urine." Out of nineteen cases studied in preparing this thesis, one patient presented a serious albuminuria complicating a malignant syphilis. This patient passed 3300 c.c. of urine in twenty-four hours, which contained 16 gm. of albumin. After an exclusive milk diet for eight days it was found that the albumin remained stationary, that the general condition of the patient was not ameliorated, and that the urine had diminished to 1500 c.c. The author, therefore, concluded that the nephritis was dependent upon the syphilis and not on some cause existing before the syphilis was acquired. In spite of mercurial treatment, the albumin excreted increased to 40 gm. in twenty-four hours, and the patient died of uræmia.

Believing that my patient was suffering from a nephritis due to the syphilitic poison, I put her upon treatment with ¼ grain of the yellow iodide of mercury three times a day, increasing 1 grain daily; in conjunction with 2 drachms of infusion of digitalis and 1 drop of spirits of glonoin every four hours. After taking the yellow iodide of mercury for twenty-four hours the patient began

to complain of sleeplessness and nausea without vomiting. At the time she was passing from 2000 to 2500 c.c. of urine in twenty-four hours, which had a specific gravity of 1021, and which contained hyaline and granular casts, renal epithelium, and leukocytes, and 0.7 per cent. of albumin by the Esbach method. The administration of digitalis was discontinued, but the mercury was continued until she had been taking it for five days. As the symptoms did not improve, but rather seemed to be aggravated, the administration of mercury was stopped. At that time she was taking 2 grains of the yellow iodide of mercury daily. After an interval of a week, treatment with mercurial inunctions was begun, 1 drachm daily, and after three days this was stopped because the patient complained of nausea, insomnia, occipital headache, foul breath, œdema of the feet, the legs, and the thighs. The eruption during this mercurial treatment showed no signs of improvement. The feet, the legs, and the thighs were painful as well as œdematous. There was a red line on the gums, and the tongue was thickly coated. It then appeared plain that the eruption was not due to syphilis, and, in consultation with Dr. Jay F. Schamberg, a diagnosis of psoriasis was made. During this time the patient passed from 1500 to 2750 c.c. of urine in twenty-four hours, which contained from 0.35 per cent. to 0.6 per cent. of albumin, as determined by the Esbach method, as well as hyaline and granular casts.

It now appeared as though the nephritis from which the patient was suffering was due to the large quantities of mercury that she had taken. Her urine was examined for mercury according to the method of Almén, as given by v. Jaksch.[2] To 300 c.c. of urine a little sodium hydroxide and some saccharose were added and the mixture boiled. After boiling, the precipitate was allowed to settle and the fluid was decanted. The precipitate was then dissolved in hydrochloric acid, and the resulting solution was diluted with six volumes of water. A small piece of thin, polished copper-foil was then placed in the fluid, which was maintained at a moderate heat for an hour and a half. The copper-foil was then removed, boiled in alkaline water, washed with alcohol and ether, dried and heated in a Reinsch tube to sublime the mercury. By this process mercury

was obtained as small globules, the finding being confirmed by Dr. John Marshall.

This process of detecting mercury in the urine is very tedious, requiring about three hours, and Dr. Marshall suggested the following method as being simpler and more rapid, requiring only about one hour to complete the process. To 600 c.c. of urine 100 c.c. of strong hydrochloric acid are added, together with 0.5 gm. of potassium chlorate. The mixture is heated to the boiling-point in a porcelain dish, and is then, while hot, transferred to a funnel provided with a cock in which a folded filter has previously been placed. The end of the funnel is placed in the wide portion of a thistle tube, the end of which has been fused so that it shall have a small outlet, into which at the outlet a piece of bright copper-foil, rolled in the shape of a spiral, has previously been placed. The rate of passage of the hot filtrate through the thistle tube is regulated by the stop-cock in the funnel so that about 100 c.c. pass over the copper-foil in about seventy seconds. The liquid which has passed through the thistle tube is collected in a suitable receptacle, kept hot, and while hot passed over the copper-foil repeatedly until the entire amount of the fluid has passed over the copper-foil six times. The copper-foil is then washed in water, alcohol, and ether, and, when dried in the air, is heated in a Reinsch tube to sublime the mercury. This method was first applied on April 2, 1902, mercury having been detected in the urine by the process of Almén on April 1, 1902, and the patient's urine since then has been examined at intervals, first of one month, and later of two weeks. Mercury was found in all the specimens examined until April 16, 1903. From April 2, 1903, until April 16, 1903, the amounts obtained by sublimation in the Reinsch tube were very small. The last dose of mercury, 1 drachm of mercurial ointment, was administered to the patient on March 18, 1902. The patient had been eliminating mercury, therefore, for one year and twenty-nine days since the last dose was administered.

The œdema from which the patient suffered was deep-seated and, over the internal surface of the tibia, appeared to be situated beneath the periosteum. On one occasion I examined the urine

for albumose, thinking some subacute inflammatory lesion of the bones might be present which would cause this substance to appear in the urine, but no albumose was found.

During the course of the treatment the patient was given hot salt-water baths, with the hope of increasing the elimination of mercury through the sweat glands. This produced a profuse red rash, somewhat similar to the rash of scarlet fever, and, as the lesions of psoriasis were also still present, the latter eruption formed circular, pale areas in the midst of the diffuse redness. As Hoffmann[12] reported two cases of mercurial dermatitis in which eosinophilia was present in the blood, a blood examination made during the persistence of this eruption gave the following result: Erythrocytes, 4,840,000; leukocytes, 11,200; hæmoglobin, 100 per cent. Differential count: polymorphonuclears, 65 per cent.; lymphocytes, 24 per cent.; transitionals, 6 per cent.; eosinophiles, 5 per cent. It will be noted that there was a slight eosinophilia. Further, the granular degeneration of the erythrocyte, described by White and Pepper[13] in chronic lead poisoning, was looked for, but not found.

During the progress of the case the patient had several acute exacerbations, which were characterized by a diminished excretion of urine, increase of œdema, nausea and vomiting, and headache. Rest in bed, hot baths, and liquid diet controlled these in a day or two.

On July 1, 1903, the patient's condition was as follows: She had been teaching school for seven months, part of the time both day and night school. She feels tired and complains of pains around her heart, particularly at night; she is a little short of breath at times, usually in the evening. Her vision is good. There is probably slight œdema of the ankles in the morning. She has headache occasionally, when she is unusually tired. Her appetite is good, her bowels are regular, and she sleeps fairly well; little noises keep her awake; but if she is not disturbed she sleeps all night. She passes about 1500 c.c. of urine daily; an examination of the morning specimen gave the following result: color, amber; reaction, acid; specific gravity, 1010; sediment, slight; microscopic examination—few granular casts, large quantities of epithelium; leukocytes; chemical examination—albumin, 0.025 per cent. by the Esbach method; no sugar. She does not complain of palpitation, of nausea or vomiting, nor of indigestion. Her psoriasis is worse than it has ever been.

Her eyes are prominent; the pupils react both to light and distance. The mucous membranes are of good color. The tongue is clean and moist. Pulse 90 per minute, regular, small volume, artery normal.

Heart. Apex neither visible nor palpable. Dulness third interspace, midsternal line, midclavicular line, fifth interspace. The sounds are heard most distinctly in the fifth interspace just outside the midclavicular line. There are no murmurs. The muscular quality of the systolic sound is deficient. The diastolic sound at the base is accentuated.

The lungs are normal except for cogwheel inspiration in the left axilla. The thyroid body is distinctly palpable.

Blood Examination. Erythrocytes, 4,500,000; leukocytes, 10,800; ratio, 1 to 416. Hæmoglobin, 82 per cent. Differential count: polymorphonuclears, 70.6 per cent.; lymphocytes, 24.6 per cent.; transitionals, 3.2 per cent.; eosinophiles, 1.6 per cent. There was no granular degeneration of the red cells.

She is taking ten drops of tincture of digitalis and one glass of lithia water daily. On account of having just gotten her system rid of one metallic poison, I did not feel warranted in giving her arsenic for the psoriasis, so put her upon 5-grain doses of potassium acetate three times a day.

Dr. Marshall's procedure for the detection of mercury in the urine is based on the theory that mercury is eliminated in the urine in some organic combination. The addition of hydrochloric acid and potassium chlorate to the urine breaks up the combination and converts the mercury into a soluble chloride. Metallic mercury is then deposited from the hot acid solution on the copper-foil by electrolysis, so that, by sublimation in the Reinsch tube, it redeposits on the walls of the glass tube and can be detected as small globules adhering to the walls of the capillary portion of the tube, with a low power of the microscope. When Dr. Marshall suggested the process he thought it was original, but subsequently he found essentially the same process described by Witz,[5] except that Witz used potassium permanganate instead of potassium chlorate to assist in the decomposition of the organic mercurial compound.

The accumulation of mercury in the tissues, its subsequent elimination, and its possible deleterious effects are subjects of considerable importance to the physician, particularly so to the genito-urinary specialist and the syphilographer. White and Martin[7] point out that lesions of the kidney particularly predispose to the

development of hydrargyrism and say that the drug should be used with caution in cases in which there are crippled kidneys.

V. Jaksch[20] says that when the diagnosis has been correctly made the administration of mercury in syphilis has never done permanent evil, although individuals who are afflicted with nephritis tolerate the drug badly. The urine in such cases contains albumin, casts, and renal epithelium. Cornil[21] says that mercury has a profound action on the kidneys. It is, in the first place, an irritant to these organs and causes a swelling with fatty degeneration of the epithelium of the tubules.

According to Wood,[6] mercury has been found in the blood, the urine, the serum of ulcers, the saliva, the feces, the pus from ulcers, the semen, the milk of nursing women, and in every conceivable secretion and in every tissue. It has been demonstrated that a single dose of mercury does not remain in the system, but when the drug is administered constantly for a length of time, elimination does not keep pace with absorption, so that the drug accumulates in the tissues. There appears to be no limit of time during which stored-up mercury may remain in the body. All the probabilities point to the possibility of mercury being deposited in the tissues in such form that it is practically inert and exerts no effect on the system; liable, however, under certain agencies to be set free and exert its power upon the general nutrition. Wood refers to Klemperer's conclusions* that the changes in the kidneys due to mercury are: excessive hyperæmia, parenchymatous nephritis, hemorrhagic nephritis, widespread degeneration of the epithelium, and deposits of chalky material. My patient has apparently reached the condition of parenchymatous nephritis with widespread degeneration of the renal epithelium, which, I fear, is permanent.

Hare[4] says that there are three theories concerning the absorption of mercury: 1. The theory of Miahl, that the mercurial preparations are transformed in the stomach and intestines into the bichloride, which, in turn, unites with the sodium chloride in the blood and circulates as a double chloride of mercury and

* Virchow's Archiv, cxviii., 1889.

sodium. 2. Henoch's theory that the metal forms an albuminate of mercury. 3. Voit's theory that a chloro-albuminate is formed. Hare also says that mercury is eliminated as an albuminate by every excretion of the body. A single dose is rapidly eliminated, but large doses frequently repeated show a cumulative action, and the mercury is so slowly eliminated as to remain for indefinite periods. He refers to the work of Balzer and Klumpke, which shows that mercury can be eliminated by the kidneys for many weeks when the body is saturated with the drug in doses of $\frac{1}{16}$ grain daily.

The literature, besides that referred to by Wood and Hare, contains a few reports of cases of nephritis due to the ingestion of mercury and of the finding of mercury in the urine. These cases are usually instances of poisoning by a single large dose of some preparation of the metal. For instance, Benham and Hendly[8] report the case of a girl, aged twenty years, who took ninety grains of red oxide of mercury and ammoniated mercury. After the symptoms of acute poisoning had passed off the urine became scanty and contained a large amount of albumin and casts. By the test with a piece of bright copper-foil, mercury was found in the urine, saliva, and the stools. The patient presented a vivid-red rash, like the rash of scarlet fever. The girl recovered after a miscarriage, but there is no note concerning the ultimate condition of the kidneys.

Axenfeld[9] reports the case of a man, who presented the symptoms of chronic mercurial poisoning from using acid nitrate of mercury in the preparation of rabbit skins. The urine of the patient was normal in quantity and did not contain albumin. A quantity of urine, evaporated to a small volume, was decolorized with a hypochlorite and a portion then treated with hydrogen sulphide; a black precipitate of mercuric sulphide was produced. Another portion of the liquid treated with potassium iodide gave a red precipitate of mercuric iodide. Mercury was also obtained as a whitish-gray deposit on a strip of gold wrapped around a layer of tin (Smithson's pile) from another portion of the liquid. Mercury was found in the saliva by the same reaction.

Seguin[10] reports the case of a boy who took red iodide of mer-

cury and potassium iodide for a cerebellar tumor. The symptoms of the disease improved under the treatment; but on examining the urine it was found to contain hyaline and epithelial casts, but no albumin. The administration of mercury was stopped and the renal condition improved. Then the symptoms of cerebellar tumor returned, and mercury and potassium iodide were again given. This time the urine contained albumin, hyaline and granular casts, and free renal epithelium. He also notes a case the particulars of which were given to him by Kinnicutt. The patient was taking mercury biniodide for secondary syphilis. He also had a urethritis. The urine contained albumin, leukocytes, and hyaline casts. The leukocytes and the albumin were due to the urethritis and disappeared with that lesion, but the casts persisted. The casts disappeared when the iodide was stopped, although the administration of mercury was continued.

Bouchard[11] reports the case of a man who was suffering from secondary syphilis, and who had had a previous attack of lead poisoning eight months before. When first seen he had no albumin in his urine. After he had been treated with mercurial inunctions for five days he began to complain of swelling of his gums, and in spite of stopping the use of the mercurial ointment a sharp attack of stomatitis developed. Under the influence of this intoxication, seven days after the beginning of the stomatitis, the urine showed marked changes. The total quantity in twenty-four hours was 150 c.c.; specific gravity, 1017; albumin and traces of sugar were present, and the urea content was 3.6 gm. per litre.

Holle[15] quotes a fatal case of nephritis, reported by Riegel, in which the patient died from injury to the kidneys and general poisoning after the prolonged administration of calomel. He also refers to a case reported by Pel in which the patient died soon after the administration of calomel, which had not produced diuresis, as had been hoped. In this case it was found that there were large deposits of mercury in the kidneys.

Chauffard[16] reports the case of a young woman who took 5 gm. of mercuric chloride followed by 10 c.c. of laudanum. Among the symptoms referable to the kidneys in this case were complete

anuria for five days, after which the patient began to pass 70 c.c. of albuminous urine in twenty-four hours containing an abundance of granulofatty casts and epithelial cells. The patient died from the effects of a complicating pericarditis twenty days after taking the poison. No mercury was found in the urine, and at the autopsy the kidneys were found to belong to the class of large white kidneys.

Chauffard and Gouraud[17] report a case of syphilitic nephritis in a man, aged forty-seven years, who had had scarlet fever at the age of six years. In spite of energetic mercurial treatment the patient died. At the autopsy it was found that both kidneys were swollen; the convoluted tubules were most affected, and the lumina were filled with albuminous coagula. The glomeruli were not congested, but were surrounded by the same albuminous exudate, which, in certain places, half-filled the capsules of Bowman. The authors hold that the large quantity of albumin found in their case, 55 grams to the litre, argues in favor of the syphilitic origin of the nephritis, and say that this condition is quite the contrary in cases of mercurial nephritis. It seems to me more probable that this was a case in which kidneys injured by scarlet fever were put into active inflammation by their efforts to eliminate the mercury administered for the treatment of the syphilitic infection than that it was one of syphilitic nephritis as claimed by the authors.

Cornil[19] reports the case of a hatmaker who had been under the toxic influence of mercurial vapor for seven years. He died soon after he was admitted to the hospital suffering from clonic convulsions. He had neither alcoholism nor syphilis. At the autopsy a fatty degeneration of nearly all the striped muscles of the body was found. Mercury was found in the brain. The liver and the kidneys showed a fatty degeneration analogous to that observed in intoxication.

References.

1. Erick Hoffmann and Salkowski. Berliner klin. Woch., February 10 and 24, 1902.
2 Rudolf v. Jaksch. Clinical Diagnosis, English translation of fourth German edition, 1897, p. 387.
3. Waldvogel. Deutsch. med. Woch., October 30, 1902.

4. Hobart Amory Hare. A Text-book of Practical Therapeutics, eighth edition, 1900.
5. Witz, quoted by Dragendorff. Die Gerichtliche-Chemische Ermittelung von Giften, fourth edition, 1895, p. 434.
6. Horatio C. Wood. Therapeutics: Its Principles and Practice, tenth edition, 1897.
7. J. William White and Edward Martin. Genito-urinary Surgery and Venereal Diseases, fifth edition, 1902.
8. R. F. Benham and H. Hendly. British Medical Journal, 1885, vol. i. p. 484.
9. Axenfeld. Gaz d. Hôp., March 1, 1870, p. 97.
10. E. C. Seguin. Arch. Med., N. Y., 1879, p. 332.
11. Bouchard. Comptes Rendus de la Soc. de Biol., vol. v., Series 5, p. 227.
12. Erick Hoffmann. Berliner klin. Woch., October 6, 1902.
13. C. Y. White and William Pepper. American Journal of the Medical Sciences, September, 1901.
14. F. Mühlig. Münch. med. Woch., March 24, 1903.
15. August Holle. Therapeutic Monthly, June, 1902.
16. A. Chauffard. Le bull. méd., 1899, No. 12, p. 129.
17. A. Chauffard and F. X. Gouraud. La presse méd., July 5, 1902.
18. Jean Ferras. Recherches sur la Nutrition chez les Syphilitiques par l'Analyse Chimique des Urines. Paris Thesis, 1901, No. 51.
19. V. Cornil. Jour. de l'anat. et de physiol., 1886, p. 214.
20. R. v. Jaksch. Nothnagel's Spec. Path. u. Ther., Wien, 1897, vol. i.
21. V. Cornil. Des Differentes Especes de Nephrites, Paris, 1869.

DISCUSSION.

Dr. John Marshall: One of the points of interest in Dr. Swan's case is the long period during which the mercury was eliminated by means of the kidneys. It is possibly the longest period on record. White and Martin refer to a case reported by Schuster in which mercury was eliminated during a period of about six months. I have not had access to the original paper of Schuster, but possibly he may have used the method of detecting mercury by precipitating it by means of hydrogen sulphide. This method is not as delicate as the electrolytic method used by Dr. Swan, the limit of delicacy of which is about the $\frac{1}{500,000}$ part of a grain, and, consequently, if the hydrogen sulphide method had been used in Schuster's case, the limit of detection might have been reached by that method after six months' elimination.

Mercury appears to enter into combination with organic matter of the tissues. Most probably the combination is with globulin; and while some consider that the combination is a very loose one, and, therefore, may be easily broken up, as a matter of fact, persons who have had experience in the separation of mercury from organic tissues in toxicological examinations find the greatest difficulty in decomposing the tissues sufficiently to separate the mercury from its combination. It is not as easily separated from the globulin combination as arsenic is from its combination in animal tissues, which is believed to be with nucleinic acid as a nucleinate of arsenic. Therefore, we can understand that the mercury which is absorbed

and in combination with the globulin would be eliminated very slowly and the elimination would extend over a considerable period of time.

Dr. Robert N. Willson: I had the opportunity of seeing a probable case of acute mercurial nephritis this morning in the wards in Blockley. By an error of some one of the attendants the man had been given two grains of calomel three times a day for fourteen days. Yesterday he developed what appeared to be a severe mercurial stomatitis, and this morning showed signs of uræmia, œdema, with mental symptoms, convulsive movements, contractions, etc. He was in collapse this morning. There had been no time to secure a report from the urine since these symptoms appeared, but there seems to be no doubt of the condition; also no doubt of the cause. I had also the privilege several years ago in Vienna of studying a large number of cases of mercurial nephritis, occurring in the course of administration of the inunction cure of syphilis. I had the opportunity at that time of examining the kidneys under the microscope, and in a large number of cases found serious lesions of the kidneys, and especially a marked sclerosis of the interstitial substance. It would seem that the mercury causes destructive lesions in the kidney substance, and that either acute or chronic nephritis may result from the direct administration of the drug.

Dr. Swan, closing: The majority of the cases of mercurial nephritis that I have found in literature are acute, and have been caused by large doses of mercury, usually taken with suicidal attempt. There are few in which mercury given for therapeutic purposes has produced mercurial nephritis. The authors who have written on syphilitic nephritis all claim that the mercurial treatment cures the nephritis. My patient's urine was examined for mercury on two successive days in September, 1903, but no mercury was found.

OBSERVATIONS ON THE MEDICAL TREATMENT OF GENERAL WASHINGTON IN HIS *ILLNESS*.[1]

By JOHN BRICKELL, M.D.,
OF SAVANNAH, GA.

With Introductory Remarks.

By WARD BRINTON, M.D.[2]

The two most important contemporary communications bearing upon General Washington's death are the account of Mr. Tobias Lear, Washington's secretary and superintendent of his private affairs, and the report of Drs. James Craik and Elisha C. Dick, his attending physicians.

Mr. Lear's communication may be found in the appendix to Sparks' *Life of Washington*. He was present during Washington's last illness, and wrote down at the time a narrative of the occurrences preceding his death, in which stress is laid upon the treatment by bleeding.

The report of Drs. Craik and Dick was published in the *Times*, a newspaper printed in Alexandria, Virginia, and dated December, 1799. This report may also be found in the third volume of the *Medical Repository*, published in New York, in 1800, which journal was one of the earliest, if not the earliest, of the American medical magazines. Drs. Craik and Dick in their report also attached

[1] The *italicized* words inserted by Dr. Brinton for words undecipherable in the original manuscript.

[2] Read November 4, 1903.

importance to the treatment by bleeding. Dr. Jackson's memoir, attached to Mr. Everett's *Life of Washington*, refers to these papers. Dr. S. Solis Cohen, on "Washington's Death and the Doctors," published in *Lippincott's Magazine* in 1899, gives probably the most elaborate and scientific explanation of the last illness which we have.

I do not know that Dr. Brickell's paper has ever been made public, although this is possible. It is interesting because it corroborates the earlier accounts and has a strong professional bearing.

The manuscript came into my hands somewhat by accident, having been sold at Davis & Harvey's auction rooms by Mr. Henkels, to whom it had been sent by a gentleman in the South.

Regarding its absolute authenticity I am not positively informed, and it appears to be, as you can see, an old manuscript, dated, and without history. The management of the case I do not attempt to discuss, but simply present the manuscript, which shows a contemporary dissenting medical opinion of the treatment then adopted.

The following information as to Dr. Brickell, the writer of this paper, has been furnished through the courtesy of Dr. I. Minis Hays, who obtained it from Mr. William Harden, the librarian of the Georgia Historical Society, dated Savannah, Georgia, November 5, 1903. Mr. Harden writes:

"Dr. John Brickell died in this city (Savannah) December 22, 1809, and left no descendants, as appears in his will, a very brief paper bequeathing all his estate in these words: 'To my brother, James Brickell (now with me).'"

The *Republican and Savannah Evening Ledger* of Saturday December 23, 1809, contains this sketch:

"Died on Friday evening, 22d instant, Dr. John Brickell, aged sixty years. Dr. Brickell was a native of the county of Louth (Ireland), and had been forty years in America, thirty of which he spent in Georgia. He was an excellent classic scholar, an ingenious naturalist, and a sincere patriot, having evinced a fervent attachment to the honor and welfare of the United States. In a

country peculiarly favorable to botanical studies (as this was among his favorite studies) he distinguished himself by unwearied application, and the many communications he received from the learned of various climes proved him to have been devoted to science and to have been successful in his pursuits.

"As a politician he always ranked among the firmest and most incorruptible adherents to the Whig administrations of this country, and he often mourned the misfortunes of that one he had left, and will long be regretted as a friend to the rights and liberties of the world, as an elegant and accomplished scholar, and as an honest man."

The following is the text of the manuscript, to which Dr. Brickell's signature is attached:

"The life of this illustrious personage has been so eminently beneficial *and instructive* to the world that every man who has a just value for virtue, talent, or an *attachment* to civil liberty must lament his death. The loss to his country at this particular period is incalculable; it is irreparable. We shall never look upon his like again! I have perused the account published by his physicians of their medical treatment, and differ from them so entirely in my opinion of its propriety that, with all due respect for their good intentions, I think it my duty to point out what appears to me a most fatal error in their plan; and although it is not in the power of science to restore his precious life, yet a discussion of this case may be productive of benefit to mankind. I suppose myself addressing men of science whose minds are so highly cultivated as to comprehend my reasoning on this subject, which I shall make as short and clear as possible. When we examine the human blood by optical glasses, by chemistry, and by experimental philosophy, we find it full of nourishment in young people, but effete and poor in the aged. When we examine by anatomical injections the state of the vascular system we find innumerable ramifications in the arteries through which the blood flows freely in young people; while many of their anastomoses are obliterated in the aged. The blood of old people, therefore, being poorer and the channels for conveying its nourishment

fewer is the reason that old people cannot bear bleeding as well as the young, *and likewise explains* (what every man of science and experience must know) *why* a small bleeding has the same effect on an aged person that a large bleeding has upon the young and robust. These observations, founded on well-established facts, demonstrate how guarded and circumspect we ought to be in the use of the lancet when our patient is far advanced in life, and how actively we ought to employ our thoughts in devising other methods than profuse bloodletting in such a case. From what the physicians have published and other documents we have data sufficient to ascertain how far the maxims derivable from science, experience, and judgment have governed in the present instance. The duration of this illness was twenty-four hours, from 3 A.M. until after 10 P.M. A bleeder being sent for at the unusual hour of 3 A.M., we suppose the operation was not performed until 4 o'clock; before eleven hours elapsed he was bled again twice profusely, which must have been about eighteen ounces each time, and soon after he was bled again to the amount of thirty-two ounces. Thus we see by their own statement that they drew from a man in the sixty-ninth year of his age the enormous quantity of eighty-two ounces, or above two quarts and a half of blood in about thirteen hours.

"Very few of the most robust young men in the world could survive such a loss of blood; but the body of an aged person must be so exhausted, and all his power *so* weakened by it as to make his death speedy and inevitable. There *the effect followed* the cause precisely; the physicians soon observed the powers of life yielding—a loss of speech; and that he expired without a struggle (the excessive bleeding left him no strength to struggle). After what has been said it may be *expected* that I shall point out my plan; I will speak generally without *discussion or try* to criticise on the minor points of the treatment which, however, I do not admire . . . to have attacked the disease as near its seat as possible the vein under the tongue *might* have been opened; the tonsils might have been scarified; the scarificator and cup might have been applied on or near the thyroid cartilage. One ounce of blood drawn in this way *would* relieve more than a quart

drawn from the arm, and would not exhaust and enfeeble *the* body, in the same manner that an ounce of blood drawn at the temple relieves an inflamed eye more than a quart drawn from the arm. The neck might have been rubbed with warm laudanum and camphor and a bag of warm fine salt laid on; but the unreasonable application of a blister would prevent this. He ought to have been put into one, two, or three flannels; and instead of calomel, it would have been better to give him small draughts of hot whey, with a little laudanum, camphor, spiritus volatilis aromaticus, or spiritus nitri dulcis occasionally to remove the spasm which caused the dyspnœa, and produce perspiration, which would relieve *swelling*, by turning the course of the fluids toward the skin.

"JOHN BRICKELL."

SAVANNAH, 23d January, 1800.

DISCUSSION.

THE PRESIDENT: I have no doubt the College would be glad to know how this manuscript came into Dr. Brinton's possession.

DR. JOHN H. BRINTON: In answer to the question by the President, I would say that I made some attempt to follow the course of this paper. I learned, as Dr. Ward Brinton has already said, that it with some other old papers was sent from Virginia, and was here sold under the hammer. The auctioneer assured me that it was not possible to give an accurate history, but that it undoubtedly was an old paper, which its appearance shows.

VOLVULUS OF THE OMENTUM.[1]

By FRANCIS T. STEWART, M.D.,
PROFESSOR OF SURGERY IN THE PHILADELPHIA POLYCLINIC; SURGEON TO THE GERMANTOWN HOSPITAL; ASSISTANT SURGEON TO THE JEFFERSON HOSPITAL; OUT-PATIENT SURGEON TO THE PENNSYLVANIA HOSPITAL.

Including my own case, there have been nine instances of volvulus of the omentum recorded in surgical literature. These cases are as follows:

Case I. (Oberst,[2] 1882).—Male, aged thirty-five years. Right inguinal hernia for twelve years. Symptoms of irreducible hernia for two days before operation. Diagnosis before operation, irreducible hernia. At operation the sac was found to contain incarcerated omentum due to torsion, the torsion being entirely within the hernial sac. Probable etiology, forcible attempts at reduction.

Case II. (Bayer, 1898).—Female, aged fifty-four years. Left inguinal hernia for fifteen years. Following an attack of coughing there were severe pain in the hernia and a feeling as if a round object were revolving inside it. On the following day a diagnosis of strangulated hernia was made and an operation undertaken. Pathological condition, omentum adherent to the mouth of the sac by a band forming one support, the other being the intra-abdominal pedicle of the omentum. Around these two points the omentum was revolved just as a triangular handkerchief that is held at two ends could be, the pedicle being twisted four or five times on itself. There was beginning gangrene of the omentum, the peripheral end of which was pushed back through the inner half of the hernial ring. Probable etiology, severe attack of coughing.

Case III. (Baracz, 1900). Male, aged forty-two years. Left inguinal hernia for several years. Symptoms were those of strangulated hernia, and a diagnosis was so made. The lower part of the omentum was thickened, dark in color, and turned several times round its axis. The hernial

[1] Read November 4, 1903.

[2] The first six cases are abstracted from Weiner's valuable paper on Intra-abdominal Torsion of the Omentum, in the Annals of Surgery, November, 1900.

sac was empty except for some clear fluid and a band which ran from the base of the sac up through the inguinal canal into the strangulated omentum. Probable etiology, lifting heavy trunks and attempts at taxis.

Case IV. (Peck, 1900).—Female, aged thirty-seven years. Right inguinal hernia for twelve years. Symptoms were abdominal pain, vomiting, and slight fever. A tumor could be felt in the abdomen, and a diagnosis of suppurating ovarian cyst was made. The tumor was made up of the entire omentum, a tightly twisted pedicle being found just below the transverse colon. There was no connection between the omentum and the hernia, but there were some old adhesions between the omental mass and the right ovary. The microscopic sections showed chronic inflammatory changes and the extravasation of beginning strangulation. Etiology unknown.

Case V. (Hochenegg, 1900).—Male, aged forty-one years. Right inguinal hernia for thirty years. Twenty-four hours before the onset of symptoms the hernia became larger, and could only be reduced with the greatest difficulty. The symptoms, which were present for two days before operation, were abdominal pain, distention, vomiting, fever, and a mass in the right iliac region. Diagnosis, appendicitis. The tumor consisted of strangulated omentum, was the size of a man's head, was nowhere adherent, and had a slender pedicle twisted upon itself three times from right to left. Probable etiology, attempts at reduction of the hernia.

Case VI. (Weiner, 1900).—Male, aged seventy-nine years. Right inguinal hernia for thirty years. The symptoms were pain in the right iliac region, which had come on suddenly four days before operation, slight fever, and a tumor in the right abdomen. A diagnosis of intraperitoneal abscess was made. A piece of omentum as large as the palm of the hand and dark blue in color was found. Its distal portion was adherent to an epiploic appendage on the ascending colon, and its proximal portion was continuous with the remainder of the omentum by a narrow pedicle, which was twisted upon itself five or six times, causing strangulation of the portion of omentum affected. Etiology unknown.

Case VII. (Baldwin,[1] 1902).—Male, aged forty-seven years. Hernia not present. Typical symptoms of appendicitis for three days. No tumor could be felt. Diagnosis, acute appendicitis. The omentum was rolled up so as to make a distinct tumor with a small pedicle, which was twisted upon itself six times, the entire mass being about the size of a large fig. Etiology unknown.

Case VIII. (Blake,[2] 1903).—Male, aged forty-five years. Right inguinal hernia for twenty years. Three days before admission he had pain in the right side of the abdomen and in the hernia. Attempts at reduction were unsuccessful and painful. The lower right quadrant of the abdomen was

[1] Annals of Surgery, December, 1902.

[2] Ibid., July, 1903, p. 99.

filled with a mass which reached to the middle line. A diagnosis of probable appendicitis with a peritonitis spreading into the hernial sac was made. The omentum was gangrenous and twisted through four and one-half turns at its attachment to the transverse colon, constricting it to a rope-like mass one and one-fourth inches in thickness and four inches long. The lower end of the omentum entered the hernial sac, and had been retained there by the thickness of its extremity. Probable etiology, attempts at reduction of the hernia.

Case IX.—My own case occurred in a male, aged thirty-five years, a patient of Dr. Alfred Allman, with whom I saw the case and for whom I operated. His father died of Bright's disease; his mother, his sister, and his six children are living and in good health. He had never suffered from any serious illness before. Four days before operation, while in the best of health, he was attacked by severe abdominal pain which began in the epigastrium, and which later settled in the right iliac region. He vomited at this time, and went to bed. The pain grew worse and the vomiting persisted. I saw the patient for the first time June 19, 1902, on the fourth day of disease. He was a large, well-nourished man, sweating freely, and evidently suffering severe pain. His temperature was 101° F., his pulse 120, and his respirations 20. There was no hernia. The right side of the abdomen was quite rigid, and the point of greatest tenderness was at the outer border of the right rectus muscle on a level with the umbilicus. The bowels had moved freely just before the time of examination. A diagnosis of acute appendicitis was made, and the abdomen opened through the right semilunar line. The appendix was removed, and found to be normal, except for three minute hemorrhagic spots beneath the mucous membrane. A further search of the abdomen was made, and a mass feeling like a gauze sponge was found well above the incision. It proved to be the right lower corner of the omentum, gangrenous, and twisted upon itself through 360°. After excision the mass measured six inches in length and three inches in breadth. The peritoneal cavity was flushed with salt solution and the abdomen closed without drainage. Recovery uneventful.

The following is a report of the microscopic study of the excised tissue by Dr. Randolph:

A large mass of omental tissue, dark in color, and showing an abundance of fatty tissue. The mass is twisted longitudinally upon itself at the point of amputation. Sections for microscopic examination were removed from the portion beyond the twist and embedded in paraffin and stained with hæmatoxylon and eosin. There is no necrosis of the adipose tissue. The bloodvessels are the seat of extensive thrombosis, especially the smaller veins. Much of the blood in the vessels is extensively disintegrated. In some places there is extravasation of the disintegrated blood and pigment, which infiltrates the neighboring connective tissue. The changes are those which would be brought about by interference with venous return.

Seven of the cases were males, two females. Age: two were thirty-five, one thirty-seven, one forty-one, one forty-two, one forty-five, one forty-seven, one fifty-four, and one seventy-nine years. The omentum was connected with the hernia in five of the seven cases in which a hernia was present. The symptoms were acute in all, and pointed toward some serious intraperitoneal lesion. The diagnosis was not made in any of the cases; two were diagnosed strangulated hernia, one irreducible hernia, four appendicitis, one intraperitoneal abscess, and one suppurating ovarian cyst. The tumor could be palpated in five, in four no tumor could be felt. There seems to be no way suggested by which a diagnosis may be reached. A movable doughy tumor coming on quickly after attempts to reduce a hernia should make one suspicious of omental torsion. A count of the leukocytes may contribute in differentiating this condition from an abscess. A blood count was not made in any of the above cases. In all of the cases the importance of immediate operation was recognized. The extent of omentum involved varied from a portion the size of a large fig to the entire omentum, forming a mass the size of a man's head. The tip of the omental mass was fixed in six cases, thus forming two supports between which the omentum might turn. The cause of torsion was forcible attempts at reduction of a hernia in four instances, severe coughing in one, and unknown in four.

It is easy to understand how a twist in the omentum may be produced by forcible taxis of an epiplocele, by cysts or tumors of the omentum which develop irregularly, by a careless operator who fails to smooth out the omentum after an abdominal operation, and by contraction of the abdominal walls or movements of the intestine in those cases in which the tip of the omentum is adherent; but the explanation is difficult in those cases in which an apparently normal omentum revolves on its own axis in an apparently normal abdomen, as in two of the reported cases. As the results of experiments on animals, Payr[1] is convinced that overdistention of the spirally disposed veins of the omentum would produce a twisting of that structure.

[1] Archiv f. klin. Chir., 1902, vol. lxviii., No. 2.

Weiner[1] emphasizes a practical point of some value in those cases of hernia in which there have been symptoms of strangulation and in which only a strand of omentum is found in the sac at the time of operation, by insisting on a thorough investigation of the intra-abdominal portion of the omentum for torsion.

A study of these cases impresses upon us an additional danger in employing forcible taxis, and serves to fortify the conviction already formed that strenuous efforts to reduce a hernia are exceedingly hazardous.

[1] Archiv f. klin. Chir., 1902, vol. lxviii., No. 2.

REPORT OF A CASE OF TUMOR OF THE BRAIN, AN ENDOTHELIOMA OF THE DURA; OPERATION; RECOVERY; DEATH IN ONE HUNDRED AND EIGHT DAYS FROM RECURRENCE OF THE DISEASE.[1]

By WILLIAM J. TAYLOR, M.D.,
PHILADELPHIA.

A BOY, aged fifteen years, born in America, of Russian-Jewish parentage, was seen first with Dr. Theodore Sprissler on January 25, 1903.

He had been perfectly well until ten weeks before, when he misbehaved at school, and his teacher, becoming angry, seized him by the neck and bumped the right side of his head against the wall. He came home, and immediately complained of headache.

Shortly after this, still complaining of headache, he was taken to see Dr. Theodore Sprissler, who examined his head carefully, and could find no evidence whatever upon the scalp of any violence, as there was no abrasion, no bruise, or swelling. He did, however, have some slight fever—a little over 100° F., and Dr. Sprissler sent him home and to bed, fearing that he might be getting typhoid fever, but he did not think that the knock on the head had anything to do with his condition.

He did not see him again for some little time, and then only for headache, which the boy always complained of as being localized in his right temporal region. Of late this headache had become more marked, and there had been some vomiting, but there were periods of entire freedom from pain.

Thinking that the headache might be due to some other defect, he was sent to Dr. F. M. Perkins, January 20, 1903, who made this record.

Examination. No external variation from normal appearances; vision normal; pupils respond to light, convergence, and accommodation. Neither eye goes out under covering hand; has full vision either eye, and reads 0.5 type. Instilled homatropine for ophthalmoscopic examination, with following results:

[1] Read November 4, 1903.

"Right eye, media clear, H. 2 D. veins and arteries slightly tortuous, but vessel contours nowhere blurred. No retinal or choroidal changes. Left eye, the same conditions exist as in the right eye.

"*January* 21, 1903. Atropine sulphate 0.01 gives in either eye H. 2 D.—headaches still persist. Ophthalmic examination gives same appearances as on January 20th.

"27*th*. Patient was seen at office January 22d and 25th, and no changes in eye-ground appearances of January 20th noted, but on this date at an examination made at the patient's home, the following was noted:

"Right eye, pressure neuritis; full, tortuous veins; lymph spaces full, and at places contours of vessels almost lost; edge of disk hazy. Left eye, same conditions as in other eye, except in less degree."

The boy would have periods of headache, at other times was perfectly free from it, and during the time of freedom from pain attended school for five or six days before Dr. Perkins saw him, and ran around and played like other children. These paroxysms of headaches were of such a character that at times he was thought to be shamming, but soon vomiting occurred, and of a cerebral type. In view of this condition, he suggested to Dr. Sprissler that I see the boy.

Now there was a very slight swelling over the squamous portion of the temporal bone, about at the point of the insertion of the temporal muscle, and this was the point at which he complained of his intense pain, and it was somewhat tender on pressure.

When I saw him, on the 25th, the boy had been losing flesh, but there were no palsies. His station was perfectly good, but he complained of intense and increasing headaches, which were now almost constant, with occasional vomiting. I advised that he be seen by Dr. C. W. Burr, and also to increase the dose of potassium iodide which he had been taking. The boy was evidently getting much worse, and on the 28th I saw him again in consultation with Drs. Burr and Sprissler. We now were fully convinced that we had to do with a cerebral growth rapidly progressing. The symptoms had all increased; he had the most typical cerebral vomiting I have ever seen, and this occurred repeatedly while we were examining him. The slight enlargement on the right side of his skull had increased very materially, and was extremely tender on pressure.

Medical Examination by Dr. Burr.

"I saw the boy for the first time on January 28, 1903. On the right side of the head above the ear was a swelling about as large as a 50-cent piece, and circular in outline. It was painful and sensitive on pressure. There was no palsy of either arm or leg, or of the face. He used the left arm a little awkwardly. Sensibility to touch was normal on the face, arms, and legs, and there was no astereognosis. The left knee-jerk was a little diminished; the right, normal. There was no muscular rigidity nor ankle

clonus. Stroking the sole on either side caused quick and rapid extension of the toes. He could walk a little, but staggered much, and attempts at walking caused vomiting. I was not sure whether the staggering was due to ataxia or to weakness and the violent head pain. Several times during the examination he had attacks of cerebral vomiting. Speech was normal. His mental state was good. He did not like to talk much on account of the violent headache, but there was no clouding of consciousness, nor was he mentally dull or silly. He answered all questions intelligently."

We believed it to be a growth of the skull, most likely a sarcoma, and that it was growing downward and producing pressure upon the brain, and not likely to be a growth of the brain itself.

As he was growing so much worse and so rapidly, we all advised that he should be taken to St. Agnes' Hospital at once, and that his skull be opened the next day.

On Thursday, January 29th, four days after he was first seen, I operated. His condition was growing rapidly worse; evidence of pressure had distinctly increased; the pulse was 56, the temperature was normal, and he complained of intense pain in his head. His head was shaved, washed, and the scalp thoroughly disinfected, and in the presence of Drs. Burr, Perkins, Sprissler, and a number of others connected with the hospital, I made a large flap over the temporal region and turned down the scalp. The flap, which was oval, was three and one-half inches at its widest point. I found that a growth had eroded the skull, and was attached to the temporal fascia and under portion of the scalp. This diseased portion I dissected away. I now with a chisel made a circular opening in the skull, and lifted out a button of bone, two inches in diameter, the centre of which was the perforated portion of the skull. This was very vascular, and evidently had undergone in almost its entire extent changes which from macroscopic appearances resembled sarcoma. In paring off the underlying growth I thought at first that I had opened into a large infiltrating growth of the brain. This was very dense, and contained numerous fibrous bands. I next took a Rongeur forceps, and cut away the bone in front, at the back, and particularly toward the zygoma, and at last reached the limit of the growth. In working around the edges of the growth I found it was outside of the dura. The circumference of the dura was intact, but in the centre it had a base of about one inch which was adherent. I now cut the dura completely around the growth, and found a large tumor growing from the dura and projecting into the tissue of the brain, but entirely free from attachments in every direction. This I shelled out without much hemorrhage. I used hot water to control the bleeding in the scalp and in the bone, as well as Horsley's putty, then packed lightly with iodoform gauze, and closed the scalp.

He reacted well from the shock of operation and loss of blood, and in forty-eight hours the packing was removed. His condition was now most

satisfactory; headache had ceased almost at once, his temperature had been good, but at the end of seventy-two hours there was evidence of a fungus cerebri. There had been comparatively little bleeding, but tremendous weeping of the cerebrospinal fluid, necessitating frequent dressing.

I did not believe at the time of operation that all of the diseased bone and dura had been removed, but all was taken away which had the appearance of disease. His condition was alarming, and I feared that he would die on the table from hemorrhage. I believed there would be a speedy recurrence of the growth.

Every other case of dural tumor that I have seen, with one exception, has died from hemorrhage either at the time of operation or within the first twelve hours. The exception that I mention was a fibroma of the dura, removed by Dr. Keen in 1887. I have seen a number of other cases, and all have died from hemorrhage.

February 3d, Dr. Perkins made this note: "Ophthalmoscopic examination (in bed with candle light) shows in each eye distinctly made out contours of all vessels—no neuritis present."

By February 13th, or in fifteen days, he was up and about the ward. The wound had healed throughout, except at one small place where there had been packing, and from this there was still a discharge of cerebrospinal fluid; but this was gradually diminishing each day, and ceased on the 15th. He had absolutely no pain or tenderness, nor any interference with his eyesight, nor any evidence whatever of trouble with his brain.

February 21st, Dr. Perkins made this note: "Examination with student-lamp at St. Agnes' Hospital, boy sitting in chair in the dark-room, where the conditions for examination were thoroughly satisfactory. Right Eye: No vessel tortuosities or dilatation. Macular region is the seat of fine silvery bands, otherwise fundus normal. Left Eye: Same ophthalmoscopic appearances as in other eye."

On March 6th, after an absolutely uninterrupted recovery, he returned to his home with the wound completely healed, except possibly at one place where there was a line of granulation about one-half inch long by one-eighth of an inch wide. The eye-grounds were normal, and he seemed to be perfectly well.

On March 12th he complained of a stiffness in the neck and inability to open the mouth wide, but this he had at the hospital, and was probably due to the irritation of the temporal muscles. He had no pain, headache, nor any symptoms of intracranial pressure, but there was certainly a greater amount of bulging at the site of the wound than before. The whole of the flap was pushed out, and there seemed to be a rather hard, nodular swelling beneath the scalp.

I believed the growth returning, and sent him to Dr. Burr for his examination, and then to Dr. Perkins, who made this note:

"*March 12th.* Boy seen at office. Pupils responsive to light, convergence, and accommodation. Neither eye out under cover, red Maddox rod with rotary prism with small electric light as object gives at 20 cm: Exophoria, 0 to 2°; hyperphoria, 0; and at six metres, esophoria, 1°; hyperphoria, 0. Right eye: V. 6/6. Left eye: V. 6/6—no lenses used. Instilled homatropine for ophthalmoscopic examination, which gives following findings: Either eye media clear, and no pathological fundus appearances. The silvery macular bands noted on February 21st have entirely disappeared."

On March 16th, as there was distinct recurrence, and no further operative measures could be undertaken, Dr. S. Mason McCollin began the use of the X-rays; but in two days there had been a rapid increase in the size of the growth, and he had slight headache, and his father noticed for the first time a slight discharge, which came from a small spot about one-quarter of an inch in diameter at the upper anterior angle of the wound, and here and there at several spots over the surface of the projection were small points which evidently would break down in the course of a few days.

I had never seen such a rapidly progressing growth.

By March 22d he had grown so much worse and his weakness had increased to such an extent that he was no longer able to go back and forth to Dr. McCollin's office, and he therefore entered St. Agnes' Hospital for further treatment by the X-rays. The growth had enlarged very much, and his general condition was weaker; he was pale, complained of pain in his head, and slept badly.

By March 31st the growth had increased somewhat in size, although this could only be estimated. He had no headache for a week, and this freedom must be attributed, I think, to the X-rays. He complained of a great deal of stiffness and pain in the neck and of some numbness in the thumb and forefinger of the left hand, and he stated that he could not move his thumb freely, although when his attention was directed to it it seemed to me that he could.

March 26th. Ophthalmoscopic examination made by Dr. Perkins showed in either eye slight vessel tortuosity, otherwise normal fundus. Red Maddox and rotary prism give no muscle imbalance. And on April 2d: "In either eye the presence of undoubted neuritis with swollen disks—the edges of the nerve entrance obscured, the vessel contour at places (even on general retinal level) being obscured for small areas. There was no evidence of *enormous* lymph extravasation or extensive hydraulic pressure, as was present at the commencement of the case (*i. e.*, before operation), but the eye-ground appearances were indicative of small encroachments on the calibres of the efferent vessels; presumably, therefore, commencing basilar interference. An examination made about four days before showed only tortuosity, but no nerve head up-lift above general retinal level. Abney

pellet test shows no central scotomata. There was no essential difference between the fundus appearance of either eye."

On April 13th he was taken to his home. He had now total paralysis of his left arm and hand, some paresis of his right hand; his speech was becoming impaired, he was very somnolent, sleeping all of the time, but he did not complain of much pain.

Shortly after this he was placed under the care of another surgeon, who ligated the external carotid artery, evidently attempting to produce starvation of the growth by cutting off the blood supply.

In this he was unsuccessful, as the boy died on May 17, 1903, one hundred and eight days from the date of the removal of the tumor from the brain.

No post-mortem examination was made by the physician then in attendance, and I did not learn of his death until some time after the funeral and too late to make an attempt to procure one.

Remarks by Dr. Burr.

I saw him again two days after operation. His condition was excellent. He was free from headache, bright and cheerful. There was neither anæsthesia nor palsy of either arm or leg. On March 12th he walked to my office, and still was in excellent condition except for a slight rheumatic wryneck, which passed away in a few days. The tumor had, however, already begun to grow again, and I advised against operating a second time. When I first saw him the diagnosis of tumor of the brain was not difficult, but I was in error as to its nature. I thought it was most probably an osteosarcoma; it was an endothelioma.

There is not the slightest doubt that Dr. Taylor's operation not only prolonged the boy's life, but gave him a period of entire relief from very serious symptoms. Had he not been operated on I am sure he would have died a few days after my first examination.

The tumor, of course, affected only the prefrontal lobe. It pushed aside, but did not penetrate the brain mass—was not an infiltrating growth. Whatever relation there may be between the prefrontal lobes and mental processes this case proves that there may be serious and rapidly increasing pressure on the right prefrontal lobe without any mental symptoms whatever.

Pathological Report by Dr. D. J. McCarthy.

Sections were cut from the tumor mass, the dura, and the bone.

Sections of the dura and its free edges showed the connective-tissue nuclei larger than normal, but there was no evidence of tumor-cell infiltration.

Sections of bone over the tumor showed a sclerated condition of the bone with absence of diploë, but there was no evidence of a malignant condition of the bone tissue.

The sections from the tumor, and also sections cut through both the tumor and the dura, showed a tumor formation evidently starting from the meninges. The cells were arranged in rows, following a racemose arrangement, and were in close contact with the interstitial tissue. Two types of cell were present. A large cell with small nucleus and relatively larger quantity of cell body, and a small round cell in the centre of the cell nests. The accumulations of cells in the dura between the bands of connective tissue gave somewhat the appearance of scirrhus, but the racemose type of infiltration following the lymph paths, and the arrangement and type of cell led us to make a diagnosis of endothelioma starting from the meninges.

DISCUSSION.

Dr. McCollin: The X-rays were used in this case twelve or fifteen times, but with practically no effect. They relieved the condition simply for a time.

Dr. William J. Taylor: I have not the pathologist's report here, but the examination was very carefully gone into by Dr. McCarthy, and shows that the condition is one of true endothelioma.

A REPORT OF FIVE CASES OF TUMOR OF THE BRAIN, WITH OPERATION.[1]

By WILLIAM G. SPILLER, M.D.,
ASSOCIATE PROFESSOR OF NEUROLOGY AND PROFESSOR OF NEUROPATHOLOGY IN THE UNIVERSITY OF PENNSYLVANIA,

AND

CHARLES H. FRAZIER, M.D.,
PROFESSOR OF CLINICAL SURGERY IN THE UNIVERSITY OF PENNSYLVANIA.

During my recent term of service at the University Hospital five cases of tumor, the growths being situated at different parts of the brain, were under my care, and in all operation was done by Dr. C. H. Frazier, who will speak on the surgical aspects of the cases.

The first case was one of multiple sarcomatosis, and has been reported already in the *American Journal of the Medical Sciences*, July, 1903. A tumor was believed to be in the cerebello-pontile angle, and it was found at this place. Multiple sarcomata of the central nervous system were not suspected before the operation, because they did not cause symptoms. I have already discussed this case and shown that symptoms of these numerous growths were absent because the tumors were so soft they caused no pressure and little or no destruction of tissue.

Case II. *Tumor of the motor area, correctly localized and operated upon, with much improvement in the patient's condition during a period of seven weeks; return of the growth, with fatal termination.*—G. K. was referred to me by Dr. B. Kohn, April 21, 1903, with the following notes:

The patient denied having contracted syphilis, but said he had had gonorrhœa. He had used alcohol formerly to excess. He had had headache for several years, but the pain had been growing worse since last summer, and had been especially severe during the previous two weeks. The pain was

[1] Read December 2, 1903.

more or less over the whole head, but was more on the left side, especially in the forehead, and was more severe at night, and was not constant. He had noticed weakness in the right arm and hand for about two months. Since December, 1902, he had had convulsions—at first once a week, but lately not so often, and had had none during the previous two weeks. He always knew when they were coming on by a twitching in the right eye for about five minutes before the spasms developed. The attack began with a peculiar sound in the throat, the eyeballs then rolled about, and the right arm and hand became implicated in the convulsive movements. Sometimes the right lower limb was affected, but never the left side. Consciousness was not lost, and the man did not fall into sleep after the convulsions. The attacks occurred usually when the man was awake, but several times while he was asleep. The convulsions lasted about three minutes; sometimes longer. The patient had noticed for about a month that he had difficulty in speech, but his family had observed the indistinctness of speech only for about five to seven days. The disturbance of speech was purely motor in type.

The right eye had been weeping for three weeks. He had noticed dimness of vision, especially in the right eye, for some time. Mentality was sluggish and memory was poor. He had no delusions, no nausea, no vomiting, no incontinence of urine, no paræsthesia, and no pain except in the head.

A partial paralysis of the right side of the face had not been noticed by the family. The nasolabial groove was less distinct on the right side. He could not whistle well, and could not draw up the right corner of the mouth so well as the left. He was able to wrinkle the forehead and close the eyelids perfectly. The tongue when protruded deviated to the right. The pupils were equal, and the light response was preserved, but was slow on the right side. Local tenderness of the scalp to percussion was not obtained. The patellar reflexes were increased. Station was very poor, and the man was not able to stand without support. The right arm and hand were very weak and the grasp was poor.

Dr. Kohn said that he had noticed an appreciable increase in the aphasia and loss of power since he first saw the patient, one week previous. He could then stand and walk without support.

My notes, made April 25th, were as follows:

The patient is unable to give his history because of partial motor aphasia. He can speak some words and gives his name. When asked his age he says fifty-two. He is unable to speak an entire sentence correctly, and has paraphasia. He understands all that is said to him. He says that he has severe headache, that it is constant, and places his hands over the forehead and over the occipital region. He seems to be unable to read at all. He wrinkles his forehead equally well on the two sides; shuts his eyes tightly and equally well on both sides. The right side of the face in the lower

distribution of the seventh nerve is paretic. The tongue when protruded deviates a little to the right. No tenderness is felt on percussion of the scalp.

The right upper limb is very paretic. The grasp of the right hand is very feeble. The biceps tendon reflex on each side is about normal; the triceps tendon reflex is not obtained on either side. Sensation for touch and pain is preserved in the right upper limb. The muscles of the right forearm and hand are more wasted than are those of the left.

The right lower limb is very paretic. He is able to flex the limb at the hip and knee. The patellar reflex is prompter on the left side than on the right, and yet it is a little below normal on the left side. Ankle clonus is not present on either side. The Achilles jerk also is weaker on the right side and about normal on the left side. The Babinski reflex is not obtained on either side, the toes being flexed on irritation of the sole of the foot. Sensation for touch and pain is normal in the lower limbs. In walking he drags the right lower limb and allows the right upper limb to hang at the side of his body.

April 27th. Percussion of the head does not give positive results. He has no loss of stereognostic perception. He denies positively a syphilitic infection, and says he has not had dizziness.

The report of the ophthalmologic examination, April 25th, in Dr. de Schweinitz's service, by Dr. E. A. Shumway, is as follows: Vision, R. E., 6/150; L. E., 3/150. Pupils: reaction very prompt. Muscle balance: rotation of eyeballs seems unlimited in all directions. Eye-grounds: the left eye shows some fulness of central lymph sheaths; the lower inner margins of the nerve are slightly veiled, but there is no other lesion. The right eye has entirely normal eye-ground. Hypermetropia of about 5 D. in each eye. Impossible to obtain fields on account of mental condition. Visual acuity, for the same reason, very uncertain.

The report of the urinary examination, made April 29th, was: cloudy; alkaline; specific gravity, 1024; albumin, a trace; sugar negative; phosphates; few epithelial cells and leukocytes.

My notes, made April 30th, were as follows: The man's account of himself is reliable, and he says positively that his convulsions have been confined to the right side of his face and right upper limb, and that the right lower limb has not been affected. The motor aphasia to-day is much greater than at any time since he has been in the hospital. The right patellar reflex is a little below normal, and the left is about normal. Babinski's reflex is absent on each side, as on each side the toes are distinctly flexed.

On May 1st I noted that the motor aphasia seemed to be more pronounced. The right patellar reflex was about normal, and there seemed to be a slight indication of the Babinski reflex on the right side—*i. e.*, the smaller toes on the right side were extended two or three times in repeated attempts to obtain this reflex, but the big toe was not moved. When a

board containing movable letters was shown to the patient he was able to pick out six or seven letters correctly on command, and he, therefore, was not letter-blind. He said that he had had very little headache in the right side of the head, and that his headache had been especially severe in the left frontal region.

Dr. de Schweinitz examined the eyes on this date, and reported that the condition in the left eye-ground could not be considered positively a beginning choked disk, but that it was suggestive, and within six months choked disk might be pronounced.

The patient was agraphic.

A diagnosis of tumor of the lower left motor area was made. It was supposed to affect Broca's area by pressure, or to invade it slightly, inasmuch as the motor aphasia was incomplete. An operation was done May 2, 1903, and a tumor was found in the opening of the skull, and was removed. Microscopic examination showed it to be a small spindle-cell sarcoma.

On May 5th, three days after the operation, my notes were as follows: The man can reply to questions, but still has much motor aphasia, and more than he had before the operation. The paresis in the lower distribution of the right seventh nerve and in the right upper and lower limbs is nearly the same as before the operation. He has no word-deafness. His general health is good, and he is very cheerful. The patellar reflex on each side is a little below normal. Ankle clonus is not present on either side. Achilles-tendon reflex is about normal on each side. Babinski's reflex is not present on either side, and the toes are distinctly flexed. The biceps tendon, triceps tendon, and wrist reflexes are much diminished on each side. Stereognostic perception in the right hand is much impaired; but this may be the result of motor weakness.

By the end of May the man was able to be out of bed, and walked about the ward without assistance. He improved steadily, the right hemiparesis almost disappeared, his speech improved, his headache ceased, his cheerfulness was very marked, and he seemed to be almost entirely well. On June 20th he had a severe convulsion, involving the whole right side of the body, and he became paralyzed on the right side, but he soon regained some power in the paralyzed limbs. About July 7th signs of right-sided pneumonia developed. By July 16th the right upper and lower limbs had become completely paralyzed and speech was much affected.

July 25th. He has great difficulty in swallowing, and is completely paralyzed in the right upper and lower limbs. He can say only a few words, and these indistinctly. The biceps and triceps tendon jerks on the right side are a little prompter than normal. The patellar reflex is about normal on the left side, but a little diminished on the right side. Ankle clonus and Babinski's reflex are not present on either side. Stereognostic perception and sense of position cannot be determined, because of the

difficulty in getting the man to respond. Sensation for pain is present in all parts of the body. The face is very slightly affected on the right side, and the tongue is protruded straight.

The man's general condition did not permit a second operation. He died July 26th with signs of pneumonia; but, as the lungs could not be examined at the necropsy, we were in doubt whether he had pneumonia or a tumor of the lung.

A necropsy was obtained, but permission was given for removal of only the brain and spinal cord. A tumor was found in the posterior part of the left second frontal convolution, extending into the middle of the precentral convolution and the upper part of Broca's area. The growth was infiltrating and at no part sharply defined from the surrounding tissue. It was, as already said, a small spindle-cell sarcoma. A small tumor about the size of a pea was found also on the right sixth cervical anterior root.

This case was seen in consultation by Dr. Mills, and he was also present at the operation.

Case III. *Subcortical tumor, outer edge of tumor* 1.5 *cm. below the surface of the brain and within the white matter. Correctly localized as regards the portion of the brain affected, but not found at the operation because of its deep situation within the substance of the brain.*—T. S., a male, aged forty-seven years, was referred to me by Dr. L. J. Burns, April 27, 1903.

The man said he had contracted syphilis twenty-eight years previous. He had had a chancre, followed by sore throat and alopecia. He was married and had eight children living. His wife said that most of them were unhealthy and were anæmic. The wife had had four miscarriages. The man had had constant general headache during many years, but had had what he called "painful headache," confined to the left side of his face and head, during the past five years. He had paralysis of the right internal rectus; but this, he said, had been present for eight years. Since February 22, 1903, he had had convulsions, confined to the left side of the face and left upper limb. The convulsions always began in the lower part of the face, with a drawing sensation; then the jaws became locked, and the spasm extended to the upper distribution of the left seventh nerve. After the spasm in the face had reached its height, twitching of the left thumb was observed, and sometimes the left hand was forcibly rotated inward at the wrist. The left lower limb was never implicated in the convulsion. He had not lost consciousness more than once. The attacks lasted about three minutes. He had had as many as three or five in one day. When the attacks occurred he was unable to speak. He had attacks in which the speech became thick and convulsions did not occur. The warning was always a creeping sensation in the left lower jaw. He did not have nausea, vomiting, or dizziness. He complained of general weakness, but there was no objective weakness detectable except in the lower part of the left side of the face. The biceps tendon and triceps tendon and wrist reflexes

of the upper limbs were about normal. The patellar reflex was almost normal on each side. The Achilles jerk was prompt on each side, but a little more so on the left side. Ankle clonus and the Babinski reflex were not obtained on either side. The stereognostic perception was good in each hand. He had complained of a sensation of itching for years. His speech had been getting thicker during the previous two weeks. He had no tenderness on percussion of the scalp.

An examination of the eyes by Dr. W. C. Posey, April 28, 1903, gave the following results:

O. D. inward motion abolished beyond the median line. Downward motion extremely limited, even down and out. External motion fully preserved. Upward motion lost. O. D. does not react to light or in accommodation. O. S. does not react to light, but slowly in accommodation. Disks somewhat gray in their deeper layers. Vision O. D. 5/12 ? ?; O. S. 5/5 ? ?.

The man was admitted to the University Hospital, and while there a convulsive attack was seen by Dr. Willetts. It began with a creeping sensation in the left lower jaw; this was followed by twitching of the left platysma and of the left angle of the mouth. The entire left side of the face was drawn up, and the spasm was tonic. Flexion of the left thumb also was observed.

The report of the ophthalmic examination by Dr. E. A. Shumway, May 26, 1903, was as follows:

Ophthalmic diagnosis: Paralysis of third nerve O. D.; paresis of fourth nerve. Partial retention of motion of eyelid; gray degeneration of optic nerves; sheaths full.

Vision: R. E., 6/12 ? ?; L. E., 6/7.5 ? A. R. E. 2 D. p. p. 18 cm.; A. L. E., 0.75 p. p. 22 cm.

Pupils: O. D. pupil dilates to 7 mm. No response of iris to light or in accommodation. O. S. pupil responds sluggishly to both light and accommodation. O. D. lid droops slightly; movement inward entirely abolished; secondary contracture of external rectus, so that eye can hardly be brought to median line. Downward and upward motion lost, except slight down and out (fourth). O. S. movement good.

Eye-grounds: Media transparent; nerves show decided fulness of perivascular lymph sheaths; gray atrophy of nerve.

Dr. Harland reported that there was no involvement of the larynx, but the soft palate and pharyngeal constrictors (right side) seemed partially paralyzed.

On June 5, 1903, another examination was made. The tongue was protruded straight, and showed no tremor and no atrophy. The nasolabial fold on the right side was more distinct than on the left side. When the mouth was opened the teeth were not shown as distinctly on the left side as on the right. The patient could not draw up the left corner of the mouth alone at all, but could draw up the right corner.

Resistance to passive movements in the left upper limb was possibly not so good as in the right. The grip of the left hand was weaker than that of the right, and the left thumb was especially weak. The biceps tendon, triceps tendon, and wrist reflexes were about normal in each upper limb.

Resistance to passive movements in the lower limbs was about equal on the two sides. The patellar reflex was prompt on each side and equal on the two sides. The Achilles jerks were present and normal. Flexion of the toes occurred on irritation of the sole of the foot.

The left thumb felt numb, and the sense of position in the left thumb was much impaired, and the thumb was distinctly weak in resisting passive movements. Tactile and pain sensations were impaired in the left upper limb, and stereognostic perception was affected in the left hand. He called a dollar fifty cents, a twenty-five-cent piece a nickel. No impairment of stereognostic perception was detected in the right hand. Sensation for touch, pain, and temperature was not so distinct in the lower part of the left side of the face as in the right side. He called a pinprick sometimes a touch. The sensation of the upper part of the left side of the face was normal. He felt a pinprick less on the left side of the tongue, left side of mouth and nose, and complained of a numb sensation in the lower part of the left side of the face like that in the left thumb.

Gait and station were normal, even with eyes shut.

A note was made that until the last two or three weeks his convulsions had always commenced in the lower left side of the face, and from here had extended to the neck, forehead, and eyeballs. Within the past two or three weeks, in five or six attacks the convulsions had commenced in the thumb of the left hand, and had not extended further than the wrist.

While under my care he had received mercurial inunctions and iodide of potassium until gastric symptoms developed.

A diagnosis of tumor of the right lower parietal and motor areas was made, because of the impairment of sensation in the lower left side of the face and in the left upper limb, and because of the impairment of stereognostic perception and sense of position in the left hand. The left lower limb was so little affected that the lesion was not believed to be high in the cerebral hemisphere nor to implicate the motor fibres of the lower limb in their passage to the internal capsule. Because of the convulsive movements of the left side of the face and of the left hand the tumor was believed to be cortical. An operation was performed by Dr. Frazier June 5, 1903; but, although a large opening was made, no lesion sufficiently intense to explain the symptoms was found.

An examination made June 23d, eighteen days after the operation, showed that the left upper limb was almost completely paralyzed. He could raise the left hand a little from the trunk while in bed. The grasp of this hand was very feeble. He could flex the left forearm slightly on the arm. The left upper limb was very flaccid. The biceps tendon and

triceps tendon reflexes on the left side were a little exaggerated. The left lower limb was moved voluntarily and freely. The lower distribution of the left facial nerve was completely paralyzed, but the upper distribution was only slightly affected. The intelligence was good. The right side of the body was not affected. The man had convulsions after the operation, and one of these was witnessed by Dr. C. K. Mills and myself, but the dictated notes were lost. My recollection is that they were typically Jacksonian in type and were on the left side.

Dr. de Schweinitz examined the eyes July 6th, and reported: O. D. oculomotor palsy; gray disk, with distention of the central lymph sheath; no neuritis. O. S. external muscles apparently normal; no neuritis.

He was examined on July 8th by Dr. Frazier and myself. The mental condition was bad. He did not recognize anyone. He did not reply intelligently to questions. The right pupil was much larger than the left. He had become emaciated since the operation. The left upper and lower limbs were completely paralyzed. When the left limbs were stuck with a pin they were not moved; but the movements of the right limbs when the left limbs were irritated showed that the pain sensation was preserved in the latter. The left side of the face was only partially paralyzed. We could not determine by sticking the face with a pin whether the upper distribution of the left seventh nerve was affected or not. The left limbs were flaccid. The patellar and Achilles tendon reflexes were diminished on each side equally, but were not lost. The biceps tendon and triceps tendon reflexes were also much impaired.

On July 9th Cheyne-Stokes breathing was observed, and the man was unconscious. He died on the afternoon of July 9th.

We had hoped to have a second operation. I felt sure that a lesion must be present in the area previously exposed, but the man's general condition was such that we could not feel justified in attempting another operation, especially as a very careful examination of the brain had been made at the first examination.

At the necropsy a tumor was found beneath the cortex, its central portion being below the right middle motor area. Its outer border was 1.5 cm. below the cortex. The lower portion of the tumor was softened. The growth extended downward only as far as the upper level of the caudate nucleus, and at no place did it extend to the cortex. A line drawn across the brain from the fissure of Rolando would pass directly through the centre of the tumor. In transverse direction the tumor measured 4 cm., and from before backward 5 cm. Microscopic examination showed it to be a mixed sarcoma, consisting of round and small spindle cells.

Case IV. *Multiple tuberculous tumors (méningite en plaque) of the parietal lobe, correctly localized and exposed at operation; removal of growths impossible.* —F. F. was referred to me May 26, 1903, by Dr. Theodore B. Appel, of Lancaster, Pa., with the following notes:

The patient, a white man, aged thirty-one years, had been married some years, and had no children. The family history was obscure. The mother was alive and well. F. was splendidly developed physically, and had never been sick before the summer of 1898, when he was taken ill in Florida while serving as a volunteer, and was sent North. He was confined for six weeks in a Philadelphia hospital with typhoid fever and malaria. He recovered completely, and became a barkeeper in Lancaster. He acquired the reputation of being able to drink more and mix his drinks more than any man of his age. About July 1, 1902, he was taken ill with what his physician diagnosed as typhoid fever. He had a low fever for twelve weeks, never reaching 101° F., not accompanied by headache, intestinal disturbance, nor a great amount of depression. He was never the same man after this attack, though he went back to his work and returned to his habits as regards alcohol. He had been free sexually, but denied having contracted any venereal disease. After working for four weeks he was confined to his bed for five days with an attack of influenza. This was followed by recurrent headaches, becoming more and more severe, and were frontal and occipital. These headaches occurred every two or three days and lasted about twelve hours. The day following he usually felt well. About December 1st, while asleep, he had a rather severe left-sided convulsion, lasting about ten minutes. He came out of it somewhat dazed, but after a few minutes dressed and went to work. The next evening he had another convulsion, involving the entire left side, and after this he remained in a stupor about three hours. These convulsions, as well as all he has had, came without warning. He was still able to attend to his work, and about January 3d, while coming out of a saloon, he slipped and fell, cutting his head over the external angle of the left eye. He was unconscious about two hours, and he may have had a third convulsion, as the next morning he had partial loss of power in the left arm. The following week he had a very severe convulsion of a similar character, lasting about half an hour, and followed by still more loss of power in the left arm. On March 2d he had a peculiar staring look and rather slow monotonous speech. His patellar reflexes were very much exaggerated and the tonicity of the muscles on the left side was increased. After walking a short distance he had a tendency to bend backward, and he would prop himself against a convenient pole or wall until he had rested. He had decided loss of motion in the arm, but he could use it better than he had done a month previous. He showed no signs of syphilis.

On March 25th he had a fourth severe convulsion, limited to the left side, and followed by loss of power in the leg and left side of the face. Examination showed chronic inflammation of the optic nerves—more on the left side. He had some paralysis in the left side of the palate and throat muscles. He then was confined to bed. About April 10th he had another convulsion, which left him with the left side of his thorax abso-

lutely paralyzed and an increased spasticity of arm and leg. His mental powers had steadily deteriorated, and occasionally he had visual hallucinations, and usually was like a child. His appetite was excessive. He had not had vomiting or fever. Occasionally he had involuntary evacuations of the bladder, and he complained frequently of cramp-like pains in the spastic muscles of the leg and arm. The movement of the left thorax was very limited. Sensation for touch and pain was normal. The muscles of the left hand were slightly atrophied.

While under the charge of Dr. Appel he was treated with iodide and mercury until he developed coryza, sore throat, etc.

I first saw F. F. June 6, 1903. He had then just arrived from Lancaster. He had a staring expression, suggestive of brain tumor; his intellect was much clouded, but he understood simple questions, and replied to them correctly. 3 + 2 he said = 6. 8 — 2 = 6; 8 — 4 = 4. His speech was thick and somewhat difficult to understand His breath was offensive. He could move his head freely from side to side. The masseter muscle contracted firmly on each side. It was difficult to get him to draw up either corner of the mouth, and it was difficult to say whether or not the muscles about the corner of the mouth were weak, as he would not separate his lips. The tongue was protruded straight; it was not atrophied and showed no fibrillary tremor. The movements of the eyeballs were normal. Hearing was not determined, on account of the patient's stupor. He did not appear to be word-deaf.

The grasp of the left hand was fair, but not normal, and a little better than that of the right hand. Resistance to passive movement in both upper limbs was fair but not normal. The muscles on the extensor surface of each forearm were somewhat atrophied. The biceps and triceps tendon reflexes and wrist reflexes were a little exaggerated on each side, but distinctly more so on the right side than on the left. His answers regarding sensation were not reliable, and yet when the upper limbs were stuck with a pin he made an effort to remove them. The left upper limb was somewhat spastic; the right was not.

The left side of the thorax was flat and moved very little in respiration. Dulness on percussion was obtained over the upper part of the left thorax. A cardiac pulsation and thrill were felt in the left second intercostal space. A murmur also was heard at this place, and was presystolic in time. Pulse was rapid, 112, and regular.

The movements of the lower limbs were very weak; those of the left lower limb more so than those of the right. The lower limbs appeared to be weaker than the upper. He could draw up the right lower limb with difficulty, but could not draw up the left at all, and merely raised this limb from the bed. He was able to put both upper limbs above his head. The lower limbs were emaciated, and the left was very spastic and distinctly more so than the left upper limb. The right lower limb was a little spastic,

but not nearly so much so as the left. The patellar reflex was exaggerated on each side. The Achilles jerk was exaggerated on the left side. The Babinski reflex was not obtained on the left side; the big toe did not move at all, and the other toes were flexed. The Babinski reflex was obtained on the right side, and the big toe was moved slowly and distinctly upward. The man was unable to stand even with support, as his legs were flexed on the thighs and the thighs on the abdomen. A bedsore was present over the sacrum.

I was informed by Dr. Appel that the man had lost power first in his left upper limb. Each convulsion began in the left upper limb; the eyes were turned to the left, and the face was contracted on the left side. The left lower limb was never involved in the spasm until after the upper limb.

June 9th. Dr. Shumway reported as follows: Beginning optic neuritis; more decided in the left eye, in which the nerve shows some swelling. Nerve edges are obscured. Moderate tortuosity of veins.

Stereognostic perception is lost in the left hand and is normal in the right hand. He is unable to recognize a knife, pencil, or key with the left hand, but did so easily with the right hand. Sense of position is also lost in the left hand, and is normal in the right hand. He is unable to place the first finger of the right hand on the end of the first finger of the left hand if the eyes are closed. Pinprick is felt in both hands and forearms.

The left lower limb, except the toes, is almost entirely paralyzed. Any movement of this limb causes pain in the knee, and the knee is swollen; this possibly may explain why the weakness is greater than it was a few days ago. The patient is able to say correctly and without hesitation whether the big toe of either side is bent up or down; therefore, the sense of position in these toes is preserved.

11th. The mental condition is much better; he replies promptly to questions and understands better what is said to him. He does not draw up either corner of the mouth very far, but he seems to draw up the left corner a little farther than the right. When he closes his eyelids he has a peculiar fluttering of the upper lids, so that he is unable to keep the lids closed. He hears a low ticking watch in each ear at the distance of about four inches. The grasp of each hand is feeble and about equal in the two hands. The interossei muscles in each hand are somewhat atrophied and about equally so. The biceps and triceps tendon reflexes and wrist reflexes appear to be a little prompter in the right upper limb than in the left. Sensation for touch is much impaired, but not lost in the entire left upper limb, including a part of the left shoulder. Sensation for pain is almost normal in these parts, and both forms of sensation are normal in the right upper limb. The left upper limb is still somewhat spastic as compared with the right. He complains of tenderness on percussion in a spot about four inches directly above the external auditory meatus (probably the right side was

meant). It is impossible to detect any change in the note in auscultation percussion of the head.

The left lower limb is very weak—much weaker than the left upper limb —and is very spastic. The right lower limb is apparently normal. The patellar reflex is much exaggerated on each side. The Achilles reflex is prompt on each side. The Babinski reflex is present on the right side, but feeble, and is not present on the left side. The lower limbs are emaciated and equally so. Stereognostic perception in the feet is uncertain. Sensation for touch and pain seems to be about normal in the lower limbs and feet. Ankle clonus is not obtained on either side. The patient is unable to stand even with assistance.

14*th*. Dr. de Schweinitz reported as follows: Double optic neuritis; 4 D; right slight, and more extended in O. S. Paresis of right external rectus, with lateral diplopia in right field and nystagmic movement on right outer rotation. Visual fields normal with hand. Convergence near point poor. O. D. diverges first.

15*th*. When he is told to place the first finger of the right hand upon the first finger of the left hand with eyes closed he seems to have no idea of the position of the left hand, and can touch his fingers only by feeling his way along the hand. If the hand of the examiner be placed near the patient's left hand he may touch the former and think it is his own hand. His mental condition has greatly improved. He has no hemianopsia. The left lower limb he can move with more power than he could a few days ago.

19*th*. The weakness of the left upper limb is greater to-day than it has been for several days, and the mental condition is not so good.

22*d*. The grasp of the left hand is more feeble than it has been since the first few days after he came to the hospital. The movements of the left fingers are awkward. The left lower and upper limbs are spastic. The right upper limb is a little spastic. The biceps and triceps tendon reflexes and wrist reflexes are exaggerated on both sides. Diarrhœa is severe to-day. Mercury and iodide are discontinued.

Because of the greater weakness in the left lower limb as compared with the left upper limb, the loss of stereognostic perception and of the sense of position in the left hand, the impairment of tactile sensation with preservation of pain sensation in the left upper limb, the ataxia of the left hand, and the convulsive movements of the left side, a diagnosis of tumor of the right parietal lobe, encroaching especially upon the centre for the lower limb, was made. An operation was done by Dr. Frazier on July 23, 1903, and numerous small plaques were found in the right parietal region, extending into the area for the lower limb. They were too numerous to permit of removal.

An examination made July 25th, two days after the operation, showed that the man's mental condition was poor. He did not move his left upper limb when asked to do so. The left side of the face and the left upper and

lower limbs were paralyzed, but he could move the left lower limb a little. He was said to move the right limbs freely. The right lower limb was rigid.

He died a few days after the operation, and the necropsy showed that these plaques were almost confined to the parietal lobe, but extended onto the median side of the lobe and the upper part of the postcentral and precentral convolutions. One or two small plaques were found elsewhere. None were found within the white matter of the brain, except where they had grown inward from the pia. They varied in size, but some were about a half-inch in one diameter and were flat against the brain. The microscope showed that they were tuberculous.

CASE V. *Tumor of the right cerebellar lobe at its union with the pons, correctly localized, and operation attempted but abandoned before the dura was opened, because of the patient's serious condition.*—W. C. B. was referred to me July 3, 1903, by Dr. W. F. Randall, of Dushore, Pa. The patient was a man past middle life. About Christmas, 1902, he began to complain of dull headache, not severe, and not occurring daily. During the past month or six weeks the headache had been severe. It had been frontal or occipital, and sometimes general; it came at any time, and usually lasted only a short time. The patient began to vomit about April, 1903; at first he vomited only in the morning, but now vomits at any time. Dizziness does not appear to have been present. He has not had convulsions. His sight has been poor for two months; his intelligence is good. He has been growing weak during the past three weeks, and the weakness is general—not greater on one side than on the other. The grasp of the hand is good on each side. The movement of the lower part of the right side of the face is not so good as that of the left side. The forehead is moved voluntarily and equally well on each side. He closes the eyes firmly on each side. The tongue is protruded straight, and not atrophied. Voluntary movements of the upper limbs are free, and the grasp of each hand is good. The biceps tendon and triceps tendon jerks and wrist reflexes are about normal on each side. Touch and pain sensations are normal in the face and upper and lower limbs. The patellar reflex is prompt on the right side but diminished on the left side. Ankle clonus is not present on either side; Babinski's reflex is not present on either side.

He has dizziness when he sits up, and in walking staggers and always toward the right. He is unable to stand erect with feet together, and his wife says that his tendency to fall is always toward the right. His memory has been failing during the past month.

July 16th. The patellar reflex is diminished on each side—a little more so on the left. Ankle clonus and Babinski's reflex are not present on either side. Achilles jerk is present but diminished, and more so on the left side. Hemiasynergy is very pronounced in the right lower limb, and is not present in the left. When the right leg is flexed on the thigh and the thigh on

the abdomen as far as possible, and then an attempt is made to extend the right lower limb, he extends first the right thigh, and later, when the limb is almost ready to be placed upon the bed, he extends the leg on the thigh.

The patient's wife said that before he came to the hospital he yawned much in the daytime.

He has no tremor in movement of the upper limbs. He places the first finger of either hand on the end of the nose well.

The report of the ophthalmic examination by Dr. de Schweinitz is as follows: Double optic neuritis (choked disks); swelling about 5 D.; many hemorrhages; paresis apparently of right external rectus; pupils prompt; right halves of visual fields contracted, but line does not run quite to fixation point left and only half-way right. They seem somewhat uncertain.

The report from Dr. B. A. Randall is as follows: The right ear hears all tones less distinctly than the left, but distinguishes from 200–20,000 d. v. s. Bone-conduction preponderates over air, but is slightly subnormal where it should be exaggerated if trouble were tympanic only. Drumheads fair in appearance. No acoustic defect of left noted. There seems to be nerve lesion combined with tympanic on the right.

Examination of the blood showed: hæmoglobin, 75 per cent.; red blood cells, 5,312,000; white blood cells, 9840.

23*d*. During the past three days the patient has had very severe attacks of headache, usually frontal, but occasionally occipital, and during these attacks he has been very restless. He has had some morning vomiting. His wife says that his mental condition is worse than it has been, and he does not understand what is said to him. Stereognostic perception is normal in each hand. Right hemiasynergy is distinct. Resistance to passive movements is normal in the upper and lower limbs. Some nystagmoid movement is present on looking to the right or left. Sense of position is normal in the hands, but the tests for the toes give uncertain results.

25*th*. The right side of the forehead is not wrinkled as well as the left, nor does he draw up the right corner of the mouth as well as the left. He yawns frequently. No tenderness of scalp is found on percussion. The patellar reflex is much diminished on the right side, and not obtained on the left side. The patient has had fine twitching movements of the right extremities, although at times the movements have been on both sides of the body.

This case was seen by Dr. Mills in consultation.

An operation for the removal of a tumor believed to be in the right cerebello-pontile angle was done by Dr. Frazier July 23, 1903. The patient's condition was so serious that further operation had to be postponed after the bone was cut through. He died July 24th.

At the necropsy a cyst was found in the right cerebellar lobe. Its inner wall extended to the union of the right cerebellar lobe with the pons. Its outer wall extended to the surface of the cerebellar lobe, but not beyond.

Small tumor masses were found in the upper and inner wall of the cyst, and these, under the microscope, had the structure of a spindle-cell sarcoma. The cyst, with the tumor masses in its walls, could be easily enucleated. It measured 3.3 cm. from without inward and 2.4 cm. from above downward.

The vessels of the brain had been torn away, and it was impossible to say whether thrombosis occurred or not.

Photograph of the cerebellum from Case V. The right lobe of the cerebellum has been cut in half. The cyst, with a small tumor in its wall, is shown at the lower part of the cerebellar lobe. The upper part of the photograph represents the medulla oblongata.

A brief summary of the last four cases is as follows :

Case II.—The symptoms were paresis of the right side of the face and of the right upper and lower limbs, some motor aphasia, diminution of each patellar reflex, frontal and occipital headache, and convulsive movements of the right upper limb, but not of the lower. The patient did not have nausea, vomiting, vertigo, Babinski's sign, disturbance of sensation, loss of stereognostic perception, nor optic neuritis.

An infiltrating spindle-cell sarcoma was found in the second left frontal convolution, extending into the middle of the precentral and postcentral convolutions and the upper part of Broca's area.

Case III.—Syphilitic infection was acknowledged. The symptoms were severe headache on the right side during five years, convulsive movements of the left side of the face and of the left upper limb, but not of the left lower limb, a little weakness of the left side of the face, and nowhere else, gray degeneration of the optic nerves, paralysis of one third nerve and paresis of one fourth nerve, and loss of the iritic response to light and in accommodation. The patient did not have nausea, vomiting, dizziness, optic neuritis, alteration of tendon reflexes, Babinski's sign, nor loss of stereognostic perception. Later, some weakness of the left upper limb was noticed, and sensation became impaired in the left upper limb and in the left side of the face, and stereognostic perception and sense of position became impaired in the left hand. Still later, the left upper and lower limbs became completely paralyzed, and motion in the left side of face became imperfect. A subcortical mixed sarcoma (round and small spindle cells) was found in the right cerebral hemisphere. Its central portion was beneath the middle part of the motor area. Its outer border was 1.5 cm. below the surface of the brain.

Case IV.—The symptoms were frontal and occipital headache, convulsive movements of the left side of the body, impaired mentality, some weakness of upper and lower limbs, greater on the left side than on the right, spasticity of the lower limbs, exaggeration of tendon reflexes, Babinski's sign on the right side, but not on the left; optic neuritis greater in the left eye, loss of stereognosis and of the sense of position in the left hand, impairment of tactile sensation, but not of pain sensation, in the left upper limb, and awkwardness of the movements of the left fingers. Numerous tuberculous plaques were found, almost confined to the right parietal lobe, except where they extended into the upper part of the postcentral and precentral convolutions.

Case V.—The symptoms were occipital, frontal, or general headache, vomiting, general weakness, paresis of the lower part of the right side of the face, dizziness, staggering toward the right, diminished patellar reflexes, right hemiasynergy, frequent yawning, double optic neuritis, paresis of right external rectus, central deafness on the right side, some nystagmus on lateral

movement, and impaired mentality. A cyst with small sarcomatous masses in its walls was found in the right cerebellar lobe at its union with the pons.

In Case II. the convulsions in the right side of the face and in the right upper limb, the weakness of the right side of the face and of the right upper and lower limbs, the partial motor aphasia, were indicative of a focal lesion, probably a tumor, in the left side of the brain, and chiefly in or near the centre for the upper limb. As the convulsions probably had not implicated the right lower limb, it seemed more likely that the tumor had grown inward and involved the fibres coming from the centre for the lower limb in their course from this centre to the internal capsule. The absence of convulsions in the right lower limb seemed to indicate that the cortical centre for this limb was not irritated or else irritated after the fibres from this area had been cut. It was not surprising, therefore, to find a tumor within the brain in the area indicated. Especially noteworthy in this case was the absence of optic neuritis, nausea, vomiting, and dizziness.

The tumor was entirely removed, so far as we could determine, and was one of the smallest I have ever seen taken out at an operation. It was not very much larger than an English walnut. Our desire should always be to remove a tumor while it is still very small, but we are usually unable to accomplish this, as the symptoms are not sufficiently indicative of the position of the new-growth in its early development.

We felt very much pleased on account of the great improvement and, indeed, almost complete recovery following the operation for a period of about seven weeks. If the tumor had been well defined from the surrounding tissue a return might not have occurred. The necropsy showed a tumor that could at no point be outlined from the surrounding brain tissue.

We were very desirous of making another attempt to remove the growth, but the man's general condition was not such as to warrant this on account of signs of pneumonia.

Restoration to health for a period of seven weeks is by no means to be despised, and if, at the operation, we had removed more of what seemed to be healthy cerebral tissue surrounding

the tumor the recurrence might have been prevented or delayed much longer. In every case in which a tumor is infiltrating and has the appearance of a sarcoma I would recommend that surrounding brain tissue should be removed, even though it appears to the naked eye to be healthy, and even though paralysis is likely to be increased by this removal.

In Case III. syphilis was acknowledged, and the headache existing many years, the paralysis of the right internal rectus extending over a period of eight years, and the loss of the iritic response to light and in accommodation made the case appear as one of syphilitic meningitis. Antisyphilitic treatment was thoroughly employed, without distinct benefit, but this did not prove that the case was not one of syphilitic meningitis. I have seen vigorous administration of mercury and iodides have little effect on advanced cerebral syphilis where many symptoms suggested the existence of brain tumor. These cases should be regarded, at least clinically, as cases of brain tumor, and so treated—*i. e.*, by operation, where operation is permissible.

The convulsions involving the left side of the face and the left upper limb were indicative of a lesion in the corresponding cortical centres for these parts. At first there was weakness only in the lower part of the left side of the face, but later the left handgrasp became weak. The stereognostic perception became impaired in the left hand, the sense of position became impaired in the left thumb, and tactile and pain sensations became impaired in the left upper limb. Sensations of touch, pain, and temperature also became a little impaired in the left side of the face. The lesion seemed to be in the face and upper limb centres and the adjoining part of the parietal lobe, and it was believed to be cortical or very near the cortex, because of the typical Jacksonian epilepsy.

The area mentioned was exposed, but a distinct tumor could not be found. I regret that the brain was not punctured more freely in the exposed area. I have seen punctures made so often at operations for brain tumors without any effect, except an increase in the paralysis after the operation, that I had grown a little lukewarm toward this procedure. In Case III. the tumor was softened and partly fluid in its lower portion, and repeated

punctures might have caused the escape of some of the fluid and the detection of the tumor. It was so far below the cortex that its complete removal might have been uncertain, and, probably, would have been impossible. A few punctures were made at the operation.

In this case, as well as in Case II., optic neuritis did not exist, and this sign was, therefore, absent in two of the five cases, and yet in each of the two cases the diagnosis of tumor of the brain was made. One was a tumor of the middle motor area, and the other a subcortical tumor of the lower parietal and lower motor area. Choked disk is one of the most common signs of brain tumor, but is not always present. Oppenheim,[1] in his monograph on brain tumors, in regard to this subject says that he has found typical choked disk in fourteen and optic neuritis in five of twenty-three cases—*i. e.*, in 82 per cent.; that Gowers found it in four-fifths of his cases, and Knapp in two-thirds of his cases. Oppenheim expresses the opinion that, as in recent years the diagnosis of brain tumor has been made earlier and confirmed by operation, choked disk is not so frequently seen. Although papillitis does not entirely depend on the location of the tumor, he thinks it is almost a constant and early sign of tumor of the cerebellum. It is relatively often absent when the tumor grows from the meninges and presses against the brain, also in cases of cortical tumors that do not penetrate far into the white matter, and of tumors of the pons, medulla oblongata, and corpus callosum. Tumors of the occipital lobe, he thinks, cause optic neuritis late.

Mills,[2] in his text-book, remarks that optic neuritis is probably present on both sides in from 60 to 80 per cent. of all the cases of brain tumor, but that statistics on the subject are somewhat conflicting. It has been noted, he says, in only about 50 per cent. in tumors of the motor cortex.

Starr[3] says unhesitatingly that optic neuritis is present in 80 per cent. of the cases of brain tumor.

[1] Die Geschwülste des Gehirns. Second edition, p. 63.
[2] The Nervous System and Its Diseases, p. 510.
[3] Organic Nervous Diseases, p. 600.

The occurrence of Jacksonian epilepsy in Case III., in which a tumor existed 1.5 cm. below the cortex, was somewhat misleading in making a diagnosis.

In the third edition of his text-book Oppenheim[1] says that unilateral convulsions may occur from lesions of the subcortical substance, especially when they implicate the fibres from the motor zone. The convulsions are not exactly like those of Jacksonian epilepsy, and when they resemble them more closely they are caused by lesions that affect the cortex by pressure, etc.

Dejerine,[2] in speaking on the same subject, remarks that typical attacks of Jacksonian epilepsy rarely may occur from limited subcortical lesions. He observed a case in which the convulsive movements began in the hand, and a tubercle was found in the white matter of the brain 1 cm. beneath the cortex.

In Case III. typical Jacksonian epilepsy was observed when the tumor was so far as 1.5 cm. below the cerebral cortex, and as the growth was 4 cm. in transverse diameter it must have been still further below the cortex when it first developed. This is probably the first case in which a subcortical tumor so deeply situated caused typical Jacksonian epilepsy.

In Case IV. paralysis of the left side of the thorax was said to have occurred during a convulsion. The necropsy showed that the left lung was entirely atelectatic. It seemed to me impossible that the left side of the thorax could be completely paralyzed as a result of a unilateral cerebral lesion. I have never observed such a condition, and I am not aware that others have. Muscles on the two sides of the body that contract synchronously are not paralyzed by a unilateral cerebral lesion.

Especially interesting in this case, and of great diagnostic value, were the loss of stereognostic perception and of the sense of position in the left hand, the awkward movement of the left fingers, and the impairment of sensation for touch, but not for pain, in the left upper limb. These signs were indicative of a lesion of the parietal lobe. Absence of hemianopsia made an implication of the sensory fibres in the internal capsule, and, there-

[1] Lehrbuch der Nervenkrankheiten. Third edition, p. 605.
[2] Sémiologie du Système Nerveux, p. 523.

fore, a lesion near the visual fibres, improbable, and the typical Jacksonian epilepsy pointed to a cortical lesion.

The loss of the sense of position was so marked in this case that the patient was unable to find his left hand with his right hand when his eyes were closed, and he frequently took hold of my hand believing it was his own.

Although I fully believe that a lesion of the parietal lobe may cause ataxia, loss of stereognostic perception, and loss of the sense of position and some disturbance of tactile, and, possibly, of pain sensation in the limbs of the opposite side, I have not been convinced that a lesion of the motor area will give none of these symptoms.

In a recent paper Marinesco[1] remarks that Jonesco removed a part of the cortical centre for the left upper limb in a man. After the operation the patient could move his shoulder and elbow very well, but not his hand. Nine months later the movements of the left hand were very imperfect, and tactile sensation, the sense of position, and stereognostic perception were diminished in the left hand. In another case Jonesco removed the centres of the face and upper and lower limbs of the right cerebral cortex. A year after the operation there was much weakness of the left side of the body, and the sense of position, stereognostic perception, and tactile sensation were affected in the left upper limb. Thermal and painful sensations were preserved. These operations were done for epilepsy, and in one case, at least, and probably in both, the cortical motor areas were determined by the electrical current.

I have observed loss of stereognostic perception caused by lesions much below the cortex of the brain, viz., in a case of tumor of the pons (Potts and Spiller) and in a case of tumor compressing the medulla oblongata (case of Dercum); but where the symptoms indicate a tumor of the cerebrum that probably is cortical, I believe the loss of stereognostic perception and of the sense of position and ataxia of the upper limb of the side opposite to that in which is the lesion indicate much implication of the parietal lobe.

[1] Semaine Médicale, October 7, 1903, p. 325.

In 1898, at a meeting of the Philadelphia Neurological Society, I[1] referred to a case that I had seen in the service of Dr. Lloyd, at the Philadelphia Hospital, which seemed to show that the cortical representation of the sense of position is in the parietal lobe. A man complained, during the night preceding his attack, of fatigue, headache, and inability to sleep. The following morning he fell on the floor on attempting to rise from his bed, but was not unconscious. When he was found he had paresis of the left limbs and of the left side of the face and tongue. Later the patient could raise his left upper limb above his head, but every movement of this limb was ataxic in an extreme degree, though the limb was not paralyzed. The mental condition of the patient prevented an examination of the condition of sensation. At the necropsy a hemorrhage was found in the right parietal lobe. The hemorrhagic area was about 2 cm. in diameter, and extended inward in the form of a cone to the lateral ventricle, having its base in the cortex. It was situated about 4 cm. from the longitudinal fissure and about 2 cm. or 3 cm. behind the Rolandic fissure. The brain had been cut into frontal sections about 1 cm. apart, when we had an opportunity to examine it, and, although the injury to the cerebral tissue prevented an exact determination of the location of the hemorrhage, it was evidently in or very close to the supramarginal gyrus. The ataxia was probably caused by a loss of the sense of position.

This was probably one of the first cases reported in this country, showing that ataxia from a loss of the sense of position may be caused by a lesion of the parietal lobe. The case of Starr and McCosh preceded it.

A case that Dr. C. K. Mills and I saw together, June 3, 1901, in consultation, the case being under the charge of Dr. Ida Richardson, affords evidence also of the localization of the stereognostic perception and of the sense of position in the parietal lobe. The patient's left upper limb was decidedly ataxic, paretic, and astereognostic, and the head was retracted and rigid. The necropsy was made by Dr. W. F. Hendrickson. An area of depression,

[1] Journal of Nervous and Mental Disease, January, 1899, p. 43.

indefinite in outline, but about 6 cm. in diameter, was found in the parietal lobe of the right cerebral hemisphere just posterior to the fissure of Rolando. Palpation revealed less resistance at this point than over the surrounding tissue. On section this area was found to be the seat of extensive softening. The process implicated practically the entire right parietal lobe.

The case reported by C. K. Mills,[1] which was seen by me and others in consultation, was one of the first to establish the localization of the stereognostic perception in the parietal lobe. A diagnosis of tumor of this lobe was made because of the loss of the sense of position, the impaired cutaneous sensibility, astereognosis, and ataxia. The case has been so fully reported by Dr. Mills and is so well known that I need not refer to it further.

Oppenheim,[1] after giving a description of his case of parietal tumor with operation, remarks that lesions of the parietal lobe cause ataxia of one or both limbs of one side. Irritative or paralytic motor symptoms are absent, or when they occur they are the result of pressure. The sensory disturbance is always a partial hemianæsthesia, in that pain and temperature sensations are preserved, while tactile sensation, and, especially, the sense of position and the stereognostic perception are impaired or lost. Such a symptom-complex occurs when the lesion does not extend far into the white matter of the parietal lobe. He says, also, that the cases in which tumor of the parietal lobe has been so accurately diagnosed that a radical operation was possible are very few.

This case of Oppenheim was reported by him February 12, 1900, and published in the third number of the sixth volume (1900) of the *Mitteilungen*.

In his monograph[3] on tumors of the brain he says that in the majority of cases of tumor of the parietal lobe sensory irritative and paralytic phenomena were observed. He refers to Mills' case, but adds that the cases are not sufficient to permit us to regard the above-mentioned phenomena as positive evidence of

[1] Mills, Keen, and Spiller. Journal of Nervous and Mental Disease, May, 1900, p. 244.

[2] Mitteilungen aus den Grenzgebieten der Medizin und Chirurgie, 1900, vol. vi. pp. 382, 383.

[3] Oppenheim. Die Geschwülste des Gehirns. Second edition, p. 116.

lesions of the parietal lobe. The evidences of the localization value of these symptoms are, however, rapidly accumulating.

In March, 1901, C. W. Burr[1] reported a case in which there were slight hemiplegia, slight tactile anæsthesia, astereognosis, mind blindness, loss of the temperature sense on one side, sensory aphasia, varying in intensity, and mental dulness. In this case a tumor was found in the parietal lobe, pressing against but not invading the ascending parietal convolution, partially destroying the angular gyrus, and involving almost the entire posterior parietal lobule.

The meningitis in plaques that occurred in Case IV. is of a very unusual character. The best paper on the subject that I know of is by Combe. He says that the meningitis in plaques (méningite en plaque of the French writers) is an unusual form of tuberculosis, and yet one that should be recognized. Tuberculosis of the central nervous system may appear as one or more tumors of different size, some small and some large; or it may appear as numerous minute tubercles scattered along the blood-vessels; or it may appear in plaques. Combe described the last form in 1898, although it was known to Landouzy, Dupré, and Chantemesse. The meningitis in plaques, as described by Combe, predominates on the convexity of the brain, and scarcely implicates the base at all. The inflammation is circumscribed and causes little exudation; it is almost always situated about and in front of the fissure of Rolando—*i. e.*, in the motor zone. It occurs as one or several plaques of different size and thickness and consisting of agglomerated granulations and fibrinous deposits. The pia is thickened about the plaques and contains miliary tubercles. The pia is normal over the rest of the brain, or else hyperæmic and thickened. The base of the brain, the interpeduncular space, the bulb, and the cranial nerves are not affected.

This form of meningitis does not cause basal symptoms; usually there is no vomiting, no constipation, no slowness, and no irregularity of the pulse, no strabismus, no intense headache no choked disk. The localization in the motor area explains the Jacksonian

[1] American Journal of the Medical Sciences, March, 1901, p. 306.

epilepsy and paralysis of the opposite side of the body. It is not surprising, therefore, that most of the cases mentioned by Chantemesse had not been correctly diagnosed from the clinical symptoms.

The common form of tuberculous meningitis occurs more frequently in children, while the meningitis in plaques is found more frequently in adults.

Combe[1] says that in every case in which the meningitis in plaques appeared to be primary, miliary tuberculosis or local tuberculosis not causing any symptoms has been found.

The dura is usually normal, but sometimes adherences with the plaques are found. The paracentral lobule is the part usually affected.

According to F. Raymond[2] these plaques are really tubercles, and are caused by an infection conveyed by means of the cerebrospinal fluid.

E. F. Trevelyan[3] says that he has seen nine cases of the meningitis in plaques.

In my case (IV.) the plaques were situated behind the fissure of Rolando in the parietal lobe, and not in front of the fissure, where Combe says they are more commonly found. The dura was adherent to a few of these plaques. The optic chiasm examined by microscopic sections showed no evidence of meningitis, and yet this part is usually a favorite location for meningitis.

In Case V. the movement of the lower part of the right side of the face was not so good as that of the left side. The patient always staggered toward the right in walking, and hemiasynergy of the right lower limb as described by Babinski was found on two or three occasions—*i. e.*, when the right leg was fully flexed on the thigh, and the thigh fully flexed on the abdomen, and the patient then attempted to extend the limb and place it on the bed, the movements of the lower limb were not synergic; the leg was not extended simultaneously with the thigh. Babinski thinks that this hemiasynergy is present on the side on which the

[1] Revue médicale de la suisse romande, 1898.
[2] Leçons sur les maladies du système nerveux. Fourth series, 1900, p. 24.
[3] Lancet, November 7, 1903, p. 1276.

cerebellar tumor exists. I have observed the sign in four cases of supposed cerebellar tumor, but only in this case (V.) have I been able to establish its reliability by necropsy. In Case V. the patellar reflexes were diminished on each side. Deafness of central origin in the right ear was reported by Dr. B. A. Randall. Nystagmoid movements were present when the patient looked to either side. These were the chief signs that led me to diagnose a tumor of the right cerebello-pontile angle, and the diagnosis was correct.

Repeated yawning was observed in Case V. I have seen this when the symptoms indicated a lesion somewhere at the base of the brain, and I look upon it as a sign of a lesion at this part and not in the cerebral cortex. Oppenheim thinks it is not a rare sign of cerebellar tumor, but I believe it may be seen in cases of tumor elsewhere at the base.

I was unable to observe that the nystagmus was greater in deviation of the eyes to the right, the side of the lesion, than in deviation toward the left. In a case of cerebellar abscess that I saw in consultation with Dr. B. A. Randall the nystagmus was much greater when the eyes were turned toward the side of the lesion than when they were turned away from it. I have not been able to make this observation in any other case, but I speak of it in the hope that it may prove to be of clinical value.

Oppenheim describes involuntary movements, tremor, occurring in cases of cerebellar tumor, and such movements were present in Case V.

Résumé of the Operative Records of Four Craniotomies and a Discussion of the Surgery of Tumors of the Brain.

Case II.—*G. K., operation May* 2, 1903; *osteoplastic resection of the skull; exposure and removal of cortical sarcoma; recovery from immediate effects of operation; marked improvement in patient's condition during a period of several weeks; return of the growth, with fatal termination.*

Upon reflection of the osteoplastic flap and dura an area was exposed to view which, to the touch and sight, was unquestionably pathologic, and proved to be the tumor. Before proceeding to remove the tumor, consideration was taken of the patient's condition, and more particularly of his

circulation. If from the effect of the preliminary procedures the patient's circulation had been depressed, further manipulation would have been postponed for twenty-four to forty-eight hours, or until the circulation was re-established. In the absence of any alarming evidence of depression, the operation was continued and the tumor removed. There were no technical difficulties nor hemorrhage attending this step of the operation.

The tumor was not situated in the centre of the area, which was exposed, but quite near the margin of the opening, so that, if the opening in the skull had been a small one, it is quite possible that the tumor might have escaped the eye of the operator.

At the end of the operation the patient's temperature was 96°, his pulse 92, and his respirations 28. The patient reacted quite promptly, and at no time did we entertain doubt as to his recovery from the immediate effects of the operation. On the evening of the operation there was complete paralysis of the right arm and leg, and aphasia; but the following morning the function of both limbs was partially restored and the patient could speak, but very indistinctly. On the fifth day a very decided improvement was observed, both in the size of his vocabulary and in the rapidity with which he could give expression to his thoughts. Generally speaking, there was a decided improvement over his condition before the operation. The headache of which he had complained so bitterly was almost entirely relieved. Occasionally he complained of a soreness in his head, but the constant distressing headache so characteristic of brain tumor had disappeared. Two weeks after the operation the patient had left his bed, and would have been discharged from the hospital had it not been thought desirable to keep him under observation for a longer period.

CASE III.—*Thomas S., aged forty-seven years; operation June 5, 1903; osteoplastic resection of the skull; subcortical tumor below the surface of the brain within the white matter; not found because of its deep situation within the substance of the brain; operative recovery; death thirty-four days after the operation.*

After preliminary closure of the carotids the osteoplastic flap and its dura were reflected and the brain exposed. When the dura was divided the brain did not protrude, as it so often does. Its surface was inspected and several gross lesions were noted in the field exposed. These lesions were quite superficial and were not sufficiently intense to explain the symptoms. Several incisions were made into the cortex of the brain about a centimetre in depth, with a view toward exposing a subcortical growth, but the incisions were not deep enough to have revealed the tumor which was discovered at the autopsy. The flaps were replaced and the wound closed. In this, as in the former case, the patient reacted promptly from the operation, and after a slight febrile reaction, running over a period of eight days, the temperature returned to normal. During the convalescent period the patient had some convulsions, Jacksonian in type, and his left upper

limb became almost completely paralyzed. He was, however, almost entirely relieved of the headache from which he had been suffering. He was transferred to Dr. Spiller's ward three weeks after the operation.

CASE IV.—*F. F.; operation June 23, 1903; osteoplastic resection of the skull; exposure of multiple tubercular tumors (méningitis en plaque) of the parietal lobe; removal of growths impossible.*

Several observations upon the blood pressure were made prior to the operation, and, as is now my practice, these observations were continued at intervals of not less than five minutes throughout the operation. Anticipatory of hemorrhage, both common carotids were closed temporarily. A horseshoe-shaped flap composed of the scalp was fashioned with the knife of the Stellwagen instrument and the bony flap with the drill and dental engine. Upon attempting to reflect the dura numerous adhesions were discovered between it and the cortex, but these were separated without much difficulty. Upon reflection of the dura numerous lesions, some isolated, some confluent, were revealed distributed over the entire area of the cortex which had been exposed to view. Upon introducing my index finger between the dura and exploring the cortex in all directions, I discovered more adhesions. The discovery of the latter was sufficient to warrant the assumption that the process was too diffuse and of such a nature as to render it positively inoperable. Although the manipulations had up to this time been neither prolonged nor of such a character as to inflict serious traumatism upon the cerebral tissue, yet the brain had bulged to such an extent that it became quite evident that I would not be able to bring the edges of the dura into apposition. In order to guard against the development of a hernia or a fungus cerebri, a section of pericranium was removed of a size sufficient to fill in the gap in the dural wound. Within a few minutes of the time the brain was exposed, although nothing more than a careful inspection and exploration with the finger had been resorted to, the circulation began to fail, becoming more and more depressed until the termination of the operation, when the pulse was rapid and weak and the blood pressure alarmingly low (75). His condition for the first forty-eight hours was critical, but in the third day improved to such an extent that I began to feel more hopeful of his recovery from the operation. This reaction was only temporary, however, as œdema of the lungs rapidly developed, and on the fourth day after the operation the patient died.

CASE V.—*W. C. H.; tumor of right cerebellar lobe at its union with the pons; operation July 23, 1903; craniotomy of the cerebellar fossa; second stage of operation (opening of dura and exploration for tumor) postponed because of patient's serious condition.*

Realizing the difficulty with which all the surfaces of the cerebellum are exposed through a small unilateral opening and anticipating very free hemorrhage, not only from the scalp but from the diploic sinuses, I decided before the operation to secure a better opportuuity to examine the suspected

hemisphere by making a very liberal opening in the skull, one extending from one side to the other, and to control at least some of the hemorrhage by preliminary but temporary closure of the carotids. Proceeding along these lines, after the Crile clamps had been applied to the carotids I fashioned a horseshoe-shaped flap by making an incision from one mastoid process to another parallel to and 1 cm. above the superior curved line. After clamping the bleeding points in the flap, an opening in the skull was made with chisel and mallet 2 cm. below and 2 cm. from the median line. This opening was enlarged with the rongeur forceps equally in all directions until it extended above to the superior curved line and almost to the median line. A similar opening was made in the opposite side. By means of a Gigli saw the intervening bridge of bone was divided above and below and removed. With this the first stage of the operation was completed. The patient's condition at this time was such as to make it unwise to attempt even to complete the operation. From the beginning of the operation there was some evidence of impairment of the respiratory or circulatory function, perhaps both. This may or may not have been due to the anæsthesia (ether), to the loss of blood, to the fact that the position of the patient may have embarrassed respiration. At all events, he was more or less cyanosed throughout, and when the first stage of the operation was completed his pulse was very rapid (170 to 180), although his blood pressure was high (158). Immediately after his recovery from ether it was noted that he was hemiplegic. During the night his respirations were of the Cheyne-Stokes type, and there were some twitchings of the left side of the face. On the following morning, at 9 o'clock, his pulse reached its lowest rate (120), but from that time on until the patient's death, thirteen hours later, the pulse and temperature began to rise. The last registration was: "pulse, 180; respiration, 24; temperature, 103.8°; blood pressure, 90."

Discussion.

Of those points to which I would draw especial attention the first is the method of making the osteoplastic or Wagner flap. The instrument which, in our experience at the University Hospital, seems to meet every indication is the so-called dental engine armed with a trephine and drill. Given an area of brain to expose, an osteoplastic flap of corresponding size can be made with much less traumatism and in a much shorter time with this instrument than with any other. Objection to other instruments may readily be found. In fashioning the flap with chisel and mallet a degree of traumatism must be inflicted upon the nervous structures within the skull, which is, to say the least, undesirable, and in the opinion of some surgeons the hammering increases the

shock, and thereby adds to the risk of the operation. As compared with any of the other methods this is by all odds the crudest. The Gigli saw may be used, but a good deal of time is consumed in making the necessary number of trephine openings, and passage of the saw from one opening to another is neither an easy nor in all cases a safe procedure. The Stellwagen trephine, which was placed on the market a little over a year ago, is an ingenious instrument, but, from the mechanical point of view, is not to be compared with the dental engine. The efficacy of the Stellwagen trephine depends upon the ability to fix the central plate—this can only be accomplished by screwing the plate to the skull; but even after the central plate has been secured in place it requires a good deal of practice and force to be able to saw through the entire thickness of the skull in a reasonably short time. But there is still another and what I consider a very serious objection to this instrument, namely, the loss of a considerable amount of blood before the flap is reflected and the hemorrhage controllable. The greatest amount of bleeding comes from the venous channels in the diploë; with the Stellwagen trephine one begins to saw through the skull, layer by layer, from without inward until one reaches the diploë; upon reaching the inner table of the skull, one must proceed more slowly and with greater caution, because of the danger of penetrating the dura and injuring the brain. Meanwhile, hemorrhage from the diploic vessels is very free, and, of course, uncontrollable until the bone is entirely divided and the flap reflected. The drill of the dental engine divides the entire thickness of bone as it proceeds; furthermore, it seems to crush and occlude the openings of the diploic sinuses, and in that way spontaneously controls hemorrhage. Including the series of cases recorded in this paper, I have performed in the last six months some ten craniotomies with the dental engine, and I believe that with this instrument a given area of the brain can be exposed with the minimum degree of traumatism and in the minimum amount of time. The element of time plays a most important part in the outcome of operations for brain tumor. Mills,[1] in a paper pre-

[1] Philadelphia Medical Journal, September 27, 1902.

sented to the College of Physicians in 1902 said: "I am satisfied that the present dangers to life in operations for brain tumor are from hemorrhage and prolonged operation." Therefore, the addition to our armamentarium of an instrument which economizes time will tend toward lowering the mortality. In the absence of complications it is quite possible without undue haste to completely divide and reflect the bony flap in eight minutes. It requires but very little practice to become proficient in the use of this instrument. After the incision has been made in the scalp, corresponding to the size and shape of the flap, an opening in the skull at one extremity of the incision is made with a small trephine operated by the engine. This will consume but a fraction of a minute. A small dural separator is inserted in the opening in order to make sure that the dura is free from the bone before the bone-drill is introduced. This can be attached to the engine without any risk of the operator's hand coming in contact with any portion of the engine that may not be sterile. The drill is now introduced and the bone divided from one extremity of the incision to the other. To guard against the possibility of the wound becoming infected from particles of dust that may be cast off from the arm or pulleys of the electrical motor, an assistant plays a stream of sterile water or normal salt solution over the field of operation while the machine is in motion. But two objections to this method of performing craniotomies suggest themselves: one, the possibility of infection, the other, the possibility of dividing the dura and lacerating the brain substance should the dura be adherent.

I have already referred to the manner in which infection may be guarded against. The danger of dividing the dura and lacerating the brain substance in those cases in which the dura is adherent is not incurred by this method more than by any other. No matter what the instrument selected for dividing the bone, if the dura be firmly adherent to the skull it will be exposed to the possibility of laceration. One of the advantages of making the flap of liberal dimensions is that there will be a margin of normal tissue between the lesion and the edges of the osseous opening. The possibility of the line of the bone-flap traversing the affected area is more remote.

McCosh, of New York, makes use of the electrical engine in his craniotomies. A small bulb of the shape of a pear, about one-quarter of an inch in diameter, is attached to the engine, and with this bulb four or five holes are bored through the skull, the cone shape of the bulb allows the point to penetrate through the skull as it is revolved, and yet prevents the shaft from entering the skull or penetrating the dura. When the holes have been made the bulb is removed, and there is substituted a small circular saw, and the bone between the holes made by the burr sawed through. A small projecting and protecting flange is screwed to the side of the circular saw, so that the blade of the saw is exposed only for the depth of the skull as measured through the holes, and in this way the danger of sawing through the dura is wholly obviated.[1] This instrument would, it seems to me, require much more practice in order to enable one to operate it with safety. If one depends, in the adjustment of the flange, upon the depth of the skull measured at any one of the holes the danger of sawing through the dura cannot, as it is claimed, be wholly obviated. The depth or thickness of the skull varies, so that there would always be the possibility of the saw penetrating the dura if the skull were thicker at one of the holes than elsewhere, or what is also an objection, though not such a serious one, the saw would not penetrate the entire thickness of the skull if the skull was thinner at the point measured than it was at some other point along the projected incision.

Most of the improvements or modifications of the technique in operations upon the brain have in view a common object—the prevention of shock. Operating as we are upon such a highly sensitive organ as the brain, and upon the organ which presides over functions so essential to the maintenance of life, additional precautions must be taken. The precautions which one ordinarily takes to prevent shock in operations upon other organs must be observed in brain operations the more stringently: the avoidance of unnecessary exposure, the avoidance of unnecessarily prolonged operation, the prevention of excessive hemorrhage, the avoidance of unnecessarily rough manipulations of the tissue, the administra-

[1] Starr, Journal of Nervous and Mental Disease, July, 1903.

tion of the anæsthetic by an experienced man, careful observation of the patient's condition, more particularly of the circulatory function, throughout the operation at frequent intervals; these are all the points to which the greatest importance should be attached.

Control of Hemorrhage. Exceptional precautions should be adopted to control hemorrhage from the very outstart. The amount of blood which will be lost from an extensive incision of the scalp might be considerable. The loss of blood will be reduced to a minimum by the application of a tourniquet around the head. I have been in the habit of using for this purpose rubber tubing. Dr. Cushing showed me the other day an appliance for this purpose which seemed to me very superior. It consists of an inflatable tube, which fits snugly the head of the patient, and with a small bicycle pump can be distended sufficiently to exert the necessary degree of pressure. If no tourniquet is used, it is a good plan to make the incision section by section, stopping to control the hemorrhage from one section before proceeding to the next. Hemorrhage from the diploic sinuses is satisfactorily controlled by Horsley's wax. When we come to the question of the control of hemorrhage from the brain and tumor itself, we are confronted with a more difficult problem. But two courses are open: one to pack gauze firmly into the wound, the other to close one or both carotids temporarily. The latter course would seem to be the ideal course were the practice of it unattended with risk. Crile, to whom we are indebted for this suggestion, performed this preliminary operation in a series of cases without any serious after-effects. It seemed to me that, if as in Crile's hand this operation were free from danger, a very important contribution had been made to the technique of brain surgery. My personal experience, however, has not confirmed these views. In the first place, temporary closure of the carotids does not altogether control hemorrhage; it controls arterial hemorrhage, but upon the venous hemorrhage, which is the much more troublesome, it has little effect. But in addition to the control being ineffectual, it is not unattended by risk, at least it has not been in my hands. I have practised temporary closure of the carotid but five times in all, including two of the cases in this report, and

from this limited experience I am firmly of the opinion that Crile's method should be reserved for the extreme cases, and in these should be confined to one side.

The posture of the patient during the operation should, of course, not be overlooked. Hemorrhage will be less free if the patient's head and body are well elevated. Unless the patient is in a state of shock I am in the habit of continuing elevation of the head and shoulders after the patient is transferred from the operating-table to his bed.

Observations upon the Blood Pressure. One of the signs of increased intracranial tension of whatever origin is elevation of the blood pressure. It is present in depressed fractures of the skull, in intracranial hemorrhage, in cerebral contusion and concussion, as well as in brain tumor. In a very exhaustive work on concussion and cerebral compression by Kocher and his students, the effects of intracranial tension upon the circulation of the brain were studied. It was observed that when the compression was of a very moderate degree there developed primarily a venous stasis or disdiamyrrhosis. This was due to the obstruction of the venous circulation by the increased intracranial pressure. If this pressure continues or increases the circulation of the brain becomes re-established; this phenomena is attributed to a stimulation of the vasomotor centre, which, acting through the peripheral vessels, causes such an increase in the arterial pressure as will compensate for the increased cranial tension. And so it is that in the presence of a brain tumor we often find the blood pressure elevated above normal. In all operations for the removal of brain tumors I have made it a practice to make an observation of the blood pressure before the operation and to have the observations upon the blood pressure continued throughout the operation. These observations are recorded on a chart designed for this especial purpose; on it are recorded by an assistant a tracing of the pulse and blood pressure in such a way that the operator can see at a glance what the pulse rate and degree of blood pressure may be. The sphygmograph,[1] which is used in my clinic, is very

[1] It is a modification of the Riva-Rocci instrument that was worked out by Dr. Stanton, instructor in medicine at the University of Pennsylvania.

simple in its construction, and can be operated without any difficulty by an untrained assistant.

The object in having this record made throughout the operation is twofold. In the first place, generally speaking, the condition of the blood pressure is the most reliable index of the patient's condition; when the normal blood pressure is sustained throughout the operation we are assured that the operative procedures have not been of sufficient gravity to induce shock. This applies, of course, to operative procedures generally, and is not confined to those upon the brain; but in operations for the removal of tumors of the brain the blood pressure index is of much greater significance, in that it assists us in determining whether the operation should be performed in one or two stages.

Indications for Two-stage Operation. It has been said that 25 per cent. would be considered a conservative estimate of patients who died immediately from the effects of operation. In some cases death is attributed to shock, in some to concussion, and in some to "unknown causes." In a discussion on the subject of brain tumors at the October meeting of the College of Physicians I said that I was inclined to believe that in the latter class of cases death was due to the sudden withdrawal of intracranial pressure. In the investigations of Kocher, that have already been referred to, it was demonstrated that the sudden withdrawal of intracranial pressure, after the blood pressure had been forced to a considerable height, may be followed by paralysis or break-down of the vasomotor mechanism. If we are correct in assuming that this theory will explain many of the fatal terminations in a given number of cases, we should give more serious consideration to the advisability of dividing the operation into two stages. Horsley recommends the adoption of this procedure in every case without exception, and von Bergmann, though not going so far as Horsley, recommended the two-stage operation in cases in which the patient's general condition was below par, or in which the tumor was a particularly large one. Horsley's recommendation seems to me unnecessarily radical, and that of von Bergmann too indefinite. It seems to me a rule may be formulated which is based upon a much more scientific basis,

namely, that when after the relief of pressure, such as would follow the removal of the osteoplastic flap and the reflection of the dura, there is a very decided fall in the blood pressure, an attempt should not be made at that sitting to remove the tumor. The completion of the operation should be postponed until the circulatory equilibrium has been restored, that is, until the circulation of the brain has become adjusted to the newly instituted physical conditions. This may mean a delay of a week or a delay of but forty-eight hours. [In order to determine in more exact terms the effect of the sudden removal from the brain of such pressure as would be exerted by a tumor, I am conducting a series of experiments upon dogs, in which an inflated rubber bag is introduced beneath the dura and distended so gradually as to simulate the growth of a tumor; when the bag is distended to a considerable size the fluid will be withdrawn suddenly, and the effect of the collapse of the bag upon the blood pressure will be recorded.]

In Case III. of this series such a course was adopted. The patient had a large subcortical tumor. Soon after the dural flap was reflected there was such a fall of blood pressure that I decided to postpone for the time being further operative intervention. The patient soon recovered from the effects of the preliminary step, but I feel quite sure that if I had continued with the operation and attempted to remove the tumor the circulatory disturbance would have been aggravated, and the patient would have died. In Case II. it will be noted in the chart that after the completion of the first stage of the operation the patient was not suffering from depression of the circulation. Accordingly, I proceeded and removed the tumor. The tumor proved to be a small one, so small that its presence had not caused enough increased tension to disturb the circulation, and the removal was effected, therefore, without affecting the blood pressure.

Sommer[1] reports his experience in an operation for sarcoma of the brain. Death ensued a few hours afterward for no demonstrable reason. The author says that in this as in many other

[1] Beiträge zur Psychiatric klinik, 1902, i. p. 5.

cases death is due to sudden change in the circulation. His views coincide with mine. As a means of relieving pressure he recommends lumbar puncture in addition to the reflection of the osteoplastic flap as a preliminary measure, postponing for a few days any attempt to remove the growth. Lumbar puncture would no doubt relieve pressure temporarily, but whether its effects would be enduring enough to be of any practical value I am not prepared to say. Furthermore, lumbar puncture is in itself a dangerous procedure, and especially so in brain tumors. A number of sudden deaths have been reported as having been caused by this procedure.

As to the Question of Bulging of the Brain. If the most alarming feature of brain operation is hemorrhage, the most troublesome is the bulging of the brain that follows reflection of the dura. In the course of our operations Dr. Spiller and I have made certain observations bearing upon this subject. As a preface to these observations it should be stated that a distinction is made between the bulging which occurs immediately after the dura is reflected, which will for convenience sake be termed "initial" bulging, and that which manifests itself during the subsequent exploratory manœuvres, or "consecutive" bulging.

First, when a tumor is present there may be little or no initial bulging, but there is not likely to be any consecutive bulging. By this we mean that, given a case in which the tumor has been localized accurately and occupies the field bounded by the opening in the skull, there may be little or no bulging, even though the tumor be one of very considerable dimensions. In Cases II. and III. of this report there were present a small and a very large tumor respectively, and yet in neither case was there any initial or consecutive bulging. No doubt the character of the tumor would have some effect—thus a very vascular sarcoma would be more likely to bulge through the opening than a gumma. The release of pressure from a growth abounding in large vascular channels would result in a reactionary dilatation, more particularly of the venous channels, and this in turn might be followed by such circulatory disturbances as would readily lead to cerebral œdema. What we want to call particular attention to is this:

that in the absence of bulging one must not be led to believe that there can be no tumor present.

Secondly, that when the tumor was not found, and if present was not situated at or beneath the area exposed, "consecutive" bulging is a very conspicuous feature, and the degree of bulging far exceeded the initial bulging observed when tumors were present. This at first thought seems as it were paradoxical, but upon further consideration is readily explained. It is due to the fact that normal brain tissue being the more sensitive reacts more rapidly to the insult of traumatism. When the looked-for lesion does not present itself on the surface of the brain at the site of exposure certain exploratory measures are instituted: the brain is palpated to determine its consistency, exploratory incisions are made into the cortex to determine whether the growth is subcortical, and the exploratory needle is introduced in the search for deep-seated collections of fluid. Meantime the brain surface is subjected to the injurious influence of a comparatively low temperature. Each one of these exploratory measures inflicts a traumatism of greater or less degree, and, as a result of their combined effects, the brain swells with amazing rapidity, so that within a few moments it protrudes so beyond the dura that it becomes a physical impossibility to replace it sufficiently to unite the edges of the dural wound. The actual cause of the swelling is no doubt the development of œdema. As pointed out by Cannon, who conducted a series of experiments in order to explain the secondary increase of intracranial pressure in head injuries, the swelling and pressure are wholly independent of any increase of blood pressure whatever, and are the result of certain chemical changes in the brain substance itself, whereby the osmotic pressure is so increased that the brain rapidly becomes œdematous.

The practical lessons to be learned from these observations are easily foreseen. In the first place, have we not in this rapid and consecutive œdema a sign that the tissue presenting in the opening is chiefly normal brain tissue, and that if there be a tumor present in the region exposed it is in all likelihood a very small one? Secondly, these observations should teach us the importance

of carrying out the exploratory measures in an expeditious manner. To be sure, we should not proceed with undue haste, but once the dura is exposed the various methods of exploration should be carried out in a methodical and unhesitating manner. A definite plan of procedure should be outlined before the operation begins, the instruments for exploration should be at hand, and once the dura is reflected the operator should, without a moment's delay, proceed with his investigation, and in the following order: 1. A careful inspection of the exposed cortex, noting whether pulsation is visible, whether the brain is of normal color, and noting the condition of the bloodvessels. Inspection should precede all the other forms of examination, because soon after exposure of the brain to the traumatism inflicted by the examining finger the brain begins to bulge. The operator should palpate, gently of course, the cortex, both the part exposed and, if nothing abnormal be found there, the parts immediately surrounding. By palpation one can discover variations in consistency and in tension. Von Bergmann recommends in those cases in which the tumor cannot be felt that the patient be raised to a sitting posture, "whereupon the tumor may become visible or palpable, the area exposed sinking in somewhat from the atmospheric pressure in connection with the lessened blood pressure."[1] 2. If by palpation one discovers an increase in the consistency, and inspection fails to reveal a growth involving the cortex, an incision of from 1 to 3 cm. should be made in the direction of the suspected lesion. The importance of making more than a nick in the surface of the brain needs no explanation. In Case III., although the tumor would not have been removed at the first operation, it was not discovered, simply because the incision was not deep enough to expose it. 3. Failing to reveal the lesion, an exploratory needle, constructed especially for this purpose, should be introduced in two or three directions, but always through the same opening. The instrument best adapted to this purpose is a small cannula armed with a blunt obturator. The instrument should be introduced to the maximum depth, the obturator removed, and the instrument

[1] Woolsey, American Journal of the Medical Sciences, December, 1903.

gradually withdrawn. The ordinary exploratory needle is useless, because upon its introduction the orifice becomes plugged with cerebral tissue, and the communication between a cyst or an abscess is thereby cut off.

Given a case in which the brain has bulged to a very considerable degree, how should this complication be treated? Three courses are open to the operator; the first to attempt to restore the brain to its normal confines and to close the dural wound; the second, to disregard absolutely the dura and to terminate the operation by closing the wound in the scalp; and, the third, to make no attempt to replace the brain, but to repair the defect between the dural edges with a graft dissected from the pericranium. The adoption of one or the other of these three courses should depend upon existing conditions. For purposes of illustration, imagine a case in which the tumor has not been found and in which there is an element of uncertainty in the diagnosis as to the existence of tumor. Under these conditions, if the dural edges cannot be approximated without such pressure upon the bulging brain as would lead inevitably to an undesirable amount of laceration of the brain substance, such a plan as that suggested by Keen should be carried out, namely, to dissect from the pericranium a graft large enough to fill the gap between the edges of the dura. This plan was adopted in Case IV. of this series. A diagnosis of tumor of the brain had been made, but instead of a tumor a tubercular meningitis almost confined to the parietal lobe was found. Shortly after the dura was reflected and the field explored the brain began to bulge in an amazingly and alarmingly rapid manner; to have attempted to suture the dura without removing a large section of the brain would have been a physical impossibility, and, inasmuch as there was no indication for the relief of pressure, the gap in the wound was closed in the manner as above described. As illustrating another phase of the question, picture a case in which a tumor was undoubtedly present, but had been localized inaccurately—a case in which headache was one of the conspicuous and most distressing symptoms. A radical operation in such a case is, for the time being at least, out of the question; but we have every reason to believe that in relieving pressure

the patient will enjoy a temporary period of relief. If, then, the indication is clearly to relieve pressure, it would be the height of folly to attempt to sew up the dura, as by so doing the intracranial pressure would be as great as it was before the operation. Under these circumstances the dura should be disregarded absolutely, the bone of the flap should be removed, and the wound in the scalp closed with great precision. When the hemorrhage is so great as to require drainage a small opening may be made in the scalp a centimetre or two from the margins of the wound, and a strip of rubber tissue introduced beneath the scalp to the field of operation.

Palliative Operation. In every operator's experience there will be a certain number of cases which for one reason or another are not suitable for the radical operation, either because the tumor is inaccessible, or because it may be too large, or because accurate localization is impossible. Under any of these circumstances when the patient is suffering, evidently from the effects of increased intracranial tension—*e. g.*, headache or choked disk—the palliative operation should be performed. I say "should be," because I believe an operation under these circumstances is more than a question of propriety, it should be regarded as imperative. Were it not for the headache the patient might enjoy for the rest of his days freedom from pain, if pressure is relieved. I have under my care now a patient that was referred to me by Dr. Hermance and Dr. Spiller, a patient who has unquestionably a tumor, but no symptoms sufficiently pronounced to make localization possible. He suffered from attacks of such violent headache that his reason became impaired, his suffering was intense and only to be compared with that attending the paroxysms of tic douloureux. Opiates did not relieve him. A section of bone was removed from the skull, and with but two exceptions, when the attacks were not severe and of very short duration, he has enjoyed absolute relief from pain, and is as contented and placid as one could be under the circumstances. The same gratifying effects may be obtained in cases of choked disk. When this condition has not existed so long as to have caused complete atrophy of the optic nerve an early operation for the relief

of pressure will be followed by marked subsidence of or disappearance of the choked disk and by a corresponding improvement of vision. We are thus enabled to restore to a greater or less degree the patient's vision for the remainder of his life. In a case recently operated upon the effect of craniotomy and consequent relief of pressure was very strikingly illustrated. The choked disk, which was present to a very marked degree, subsided at least one-half within three weeks of the date of the operation. Unfortunately in this case, the operation was not performed soon enough to save the patient's vision, as very marked atrophy of the optic nerve had already occurred. For the relief of these two conditions, namely, headache and impairment of vision, I lay stress upon the importance of the palliative operation. In performing this operation a section of bone representing about three square inches should be removed and a dural flap fashioned and reflected, and the wound in the scalp closed. This will afford the desired relief of tension.

Results. There is no question but that the statistics of the last five years give us every reason to take a more hopeful view of the surgery of this field. It will be admitted without question that the greater attainments of more recent years are to be attributed to earlier recognition of the tumor, to correspondingly earlier resort to operation, to more accurate localization, and to improvements in the technique. These may be said to include a speedier method of opening the skull, the exposure of a much larger area of the brain than was possible before the introduction of the osteoplastic flap, the adoption of the two-stage operation in those cases in which the blood pressure is materially depressed by the preliminary procedures, together with the observance in detail of all those measures which are prophylactic of shock.

As to the more recent statistics upon the results of surgical intervention for cerebral tumor, Woolsey[1] has collected 101 cases of cerebral tumors which have been operated upon during the past five years. Of this series he says: "Twelve cases, 11.8 per cent., died within twenty-four hours, and twenty-six, or 25.7 per

[1] American Journal of the Medical Sciences, December, 1903.

cent., within three weeks." Here at once we see a very marked reduction in the immediate mortality. Von Bergmann regards 25 per cent. as a very conservative estimate of the number dying as the direct result of the operation. Of the eighty-eight cases of Woolsey's series, of which an exact localization was made, the mortality was but 22.7 per cent., as against 46 per cent. among those not exactly localized. In Gussenbauer's series of twelve cases there was but one death, and that due to pneumonia. "As to the more remote results, six died within three weeks and three months; nine between three months and one year, and three between one year and two years. As almost all of these died from the effect of the tumor the mortality within two years is 43.5 per cent." This high mortality, both immediate and remote, Woolsey says is not greater than that following radical operations for malignant growths in some other situations, and that considering "the otherwise hopeless condition of these cases, the difficulties of exact diagnosis, the inaccessibility of the tumors, and the marked relief of symptoms in almost all cases not dying at once, we may take courage and feel some degree of satisfaction." Woolsey says "that we should feel still more encouraged when we consider the length of time during which some cases remain free of recurrences. Cases of sarcoma are reported four years, four years and one month, five and one-half years, and eleven years after operation. A case of fibroma was reported well eight years, cases of gummata two and one-half years, a case of glioma three and one-half years, and one case, in which the variety of tumor was not given, nine years after the operation. Seven cases of sarcomata are reported to have recurred at periods ranging from three months to eleven years, and averaging two years and four months, or, exclusive of the latter case, nine and one-third months."

It is needless to say that the prognosis in the case of benign tumors and cysts and in cases of well-encapsulated sarcomata is much better than in operations when the growths are of malignant and infiltrating type.

Résumé. 1. All measures recognized as prophylactic of shock should be observed stringently. In these we have the most effectual means of reducing the mortality. The most important

of them are (*a*) the avodiance of prolonged operation; (*b*) the prevention of excessive hemorrhage, and (*c*) the avoidance of unnecessarily rough manipulation of the brain substance.

2. A given area of brain can be exposed with the least minimum degree of traumatism and greatest economy of time by the electric engine.

3. Temporary closure of the carotids in operations upon the brain is ineffectual and not unattended by danger. It should be reserved for extreme cases, and practised on one side only.

4. Observations should be made upon the blood pressure immediately before and at frequent intervals during the operation. Object of same twofold; (*a*) as the most reliable index of patient's condition; (*b*) as the only exact method of determining whether operation should or should not be carried out in two stages.

5. Two-stage operation is indicated when there has been a decided fall in blood pressure after the relief from intracranial tension, such as follows reflection of the Wagner flap and dura.

6. Lumbar puncture as a means of relieving pressure is a temporary, not to say dangerous, procedure.

7. Bulging of the brain is one of the most embarrassing features of cerebral operations. A distinction may be made between that which occurs immediately after reflecting the dura, "initial" bulging, and that which follows as a result of subsequent exploratory manipulation, "consecutive" bulging.

8. "Initial" bulging is due to the increased tension exerted by a tumor. It is not always present, is often not excessive, and is not likely to be followed by "consecutive" bulging.

9. "Consecutive" bulging is due to the cerebral œdema set up in normal brain tissue by trauma inflicted by the exploratory manipulations. "Consecutive" bulging far exceeds in magnitude initial bulging, and suggests the absence of a tumor of considerable size at the seat of operation.

10. In order to avoid this "consecutive" bulging, which is a most embarrassing feature of these operations, exploration should be carried out in the most expeditious manner.

11. When the edges of the dural wound cannot be approximated without undue tension or without great laceration of brain sub-

stance, the gap should be closed by a graft taken from the pericranium, providing the tumor has not been found and there is reason to question the accuracy of the diagnosis.

12. When there is every assurance of a tumor being present, but it proves to be inoperable or was imperfectly localized, no attempt should be made to close the dura, as in so doing the possible palliative effects of the operation would be counteracted.

13. Palliative operations should be regarded not merely as operations of propriety, but should be considered imperative whenever the tumor cannot be found or cannot be removed.

14. A statistical study of the results of the last five years is encouraging. The mortality, both immediate and subsequent, has been reduced materially. Recurrence after operations for malignant growths of the brain is no greater than after operations for malignant growths of other structures.

EXHIBITION OF A SPECIMEN OF INTESTINAL SAND.[1]

EXHIBITED BY JOHN K. MITCHELL, M.D.

THERE are two kinds of intestinal sand—the true, which is composed of calcium salts, especially the phosphate and carbonate, and false intestinal sand, which, while having very much the same gross appearance, has, upon closer examination or chemical study, none of the qualities of the true sand, but seems to be composed either of small biliary and fecal concretions or of the tiny hard woody particles found in some vegetables and fruits, such as, particularly, the pear.

The patient from whom the specimen which I show was taken had both these varieties of sand, and passed at times also the peculiar, massed, dark-colored, muddy stools, which seem to be the result of a sort of granulation of bile retained in the intestine.

The patient was a highly neurotic person, aged forty-two years. He had suffered a general peritonitis twenty years ago, probably as the result of a perforation of the appendix. He also had typhoid fever a year or two later than this, and had for several years before I saw him frequents attacks of mucous enteritis.

His repeated bilious attacks caused me to place him upon a modified Carlsbad treatment, and not only were the Carlsbad salts used regularly, but high enemata were employed for the purpose of washing out the irritating mucus from the bowel, so that the intestines were kept very thoroughly free from any retained fecal matter.

Milk diet proved to agree with him, and at the same time that the intestinal lavage was begun he was placed upon milk. Shortly after sand was first observed in the passages. Sand was passed with every stool in small amounts for several days together, then none was found for some days, and again it appeared. The emptying of the bowel by high enemata did not seem to have any effect upon its production; it ceased when the patient was placed upon a mixed diet, although the biliary "mud" continued to show from time to time.

The patient's intestinal difficulties became so great, and he presented so many evidences of adhesions paralyzing or obstructing the bowel in parts

[1] Read December 2, 1903.

that, after consultation, we decided to operate, and Dr. Edward Martin having opened the abdomen, discovered exactly the condition that had been predicted—an old adhering appendix and several other adhesions. These being freed, the patient made a steady though not a rapid recovery, and has continued to improve in health and strength ever since.

The interesting feature in the case is the sand, true intestinal sand being very uncommon. Sir Dyce Duckworth and Delèpine, in England; Dieulafoy, in Paris, and others have reported a few of these cases. In the one or two previous cases that have come under my observation the same condition precedent existed as in this case—namely, exclusive milk diet—and this was also true in Duckworth's cases. There is enough lime in milk—even without the addition of lime-water to it, so often made when patients are on an exclusive milk diet—to supply a source for the manufacture of a phosphate or a carbonate of lime, but what other conditions are necessary for the production of these salts in the intestine no one seems to know. This specimen has proved, like those examined by Duckworth and others, to be composed of the two lime-salts mentioned chiefly. No bile-salts or bile coloring matter enter into it, though these substances were plentiful in the mud-like material passed at other times. Its color is a pale brownish-yellow.

DISCUSSION.

Dr. George Erety Shoemaker: One point of interest in these cases of intestinal sand is that they occur not only in neurotic cases, but in cases with acute peritoneal symptoms. They require care in the discrimination from appendicitis, from inflammation of the gall-bladder and other inflammatory lesions of the abdomen. I saw a case in consultation some years ago in which the question of the existence of appendicitis was carefully discussed between two consultants. It was decided against appendicitis, and the symptoms, which were acute, all disappeared on passing a quantity of perfectly black sand. It would seem that these collections must occupy a sacculated portion of the intestine. I doubt their being due to milk.

A CASE OF SEBORRHŒA NIGRICANS (BLACK MASK OF THE FACE).[1]

By ARTHUR VAN HARLINGEN, M.D.

I AM obliged to my friend Dr. Bethune, of Baddeck, C. B., for the opportunity of seeing this extraordinary affection of the skin and also for some notes of the history of the case, which I saw during my summer vacation last September.

Maggie McL., aged twenty-three years, comes of a neurotic family. Some members of the family are said to have suffered from mental alienation, and her father is a man of marked peculiarity of temper and disposition. Until her nineteenth year the patient enjoyed fair average health. She was brought up in the salubrious atmosphere of Cape Breton, and had lived as a domestic, in Boston, I think, for a short time.

About four years ago she began to fail in health, although an exact statement of the symptoms could not be obtained. She was obliged to relinquish domestic service, returned home, took to her bed, and had remained there up to the time of my examination. This scanty history was all that I could obtain of the patient's previous condition. It was also stated that soon after she took to bed a discoloration began to appear upon the face, which gradually spread and grew deeper in color until the entire visage was covered with a thick black mask.

Within the past few months the area of discoloration had diminished until it had shrunken to the dimensions about to be noted. When I first saw her the patient was lying in bed in a small one-room cottage within a few feet of the cook-stove. She had been bedridden for several years, but, although somewhat emaciated, did not seem particularly ill. The limbs could be moved without much difficulty, though each movement and even touching her excited complaints of pain. She usually lay with her eyes shut, the lids twitching, and seemed to be suffering from photophobia. The face was flushed and mottled, the skin dry and scaly. The lips were dry and covered with a yellowish sordes or crust, seborrhœic in character, which sur-

[1] Read December 2, 1903.

rounded the whole mouth. Her tongue was parched, red, and slightly fissured. It was said that this peculiar eruption about the lips usually ran a course of several weeks, turning black and falling off, to be succeeded by a fresh eruption. The forehead and nose were covered with a most extraordinary mask or crust near a quarter of an inch thick, resembling a rind of ham—soft, greasy, sharply defined about the edges, and rounded. It could be easily broken off, and the forceps could be thrust into it at any point as if the crust were comprised of soft fat. The color of the mask or crust was exteriorly of an inky blackness and tolerably smooth. The appearance of the face was as if a mask or vizard were worn over the upper part.

The patient's general condition was that of an hysterical person. The shrinking from light, the groans and complaints on the slightest attempt at

moving her, or even touching any part of the body, were highly characteristic. Trials at various points of the surface with a sharp object failed to disclose any areas of insensibility; in fact, the tactile sense appeared normal. Exception should be made of the scalp, which was certainly hyperæsthetic.

She had complained for some weeks of extreme sore throat, but seemed able to swallow without much difficulty. It was said she had taken nothing in the way of food for some weeks, excepting an occasional drink of water. Her comparative lack of emaciation and the fact that the evacuations by the bladder and rectum were regular seemed to militate against the accuracy of this statement.

The attendants were supplied with a solution of green soap in water and directed to endeavor to loosen the mask by daily washings. At the end of a week, however, when I saw her for the second time, the mask had not been at all cleaned off. It was loosened, however, and I had no difficulty

in stripping off the entire coating. It came away like a thick crust of fat, tearing here and there, where undue traction was made. The outer surface was smooth, rather dry, and black, with bits of wool, hair, etc., matted in it. The internal surface was of a whitish color, soft and very greasy, showing numerous conical elevations, corresponding to the openings of the glands. The skin underneath was washed clean of the mask-coating, and then appeared moist and oily, the epidermis rather sodden and in places slightly abraded. The process of removal was in no way painful. The parts affected were ordered to be washed daily with a watery solution of green soap and powdered with a mixture of aristol and boric acid. A week after this I saw the patient again. The skin of the face was dry, red, and slightly scaly, the powder having dried it off. The washing having been very imperfectly performed, some greasy patches were still left of the mask. Also along one side of the nose there was a greenish crust, evidently seborrhœic in character. The skin being abnormally dry, it was decided that while continuing the daily washing with soap and water a dilute oxide of zinc ointment should also be employed. This was the last occasion on which I saw the patient. I preserved a portion of the greasy mask-like crust, which dried up gradually and shrunk, but retained a rather offensive odor. Treated with ether a portion of the crust separated into various and heterogeneous components; there were fragments of wool and hair, granular débris; probably dust and grime, and whitish soft bits of tissue, which, picked out, treated with a solution of caustic potash and glycerin and examined under the microscope, were found to be composed of epithelial scales, with fine granular oil globules. The epithelial scales seemed dry and were not in a state of fatty degeneration. There were some few lanugo hairs.

The conclusion reached was that we had to deal in this case with a severe case of oily seborrhœa, giving rise to a dusky secretion upon the surface, which had been allowed to accumulate for several years, and which had, perhaps, been added to by the inunction or application of ointments and dressings of various kinds, together with accretions from the surrounding apartment, dust, flakes of soot, the sweepings of the carpet, etc. Most patients we see are cleansed more or less frequently, and it is only by long-continued neglect that such extraordinary results are reached.

We have become familiar of late years with that form of chromidrosis which occurs in a black circle about the orbit or in rarer cases upon the forehead of certain hysterical women. In these cases the oily secretion from the coil glands is changed in color and consistency, and forms a discolored coating to the skin. In some cases,

however, as the present one, the sebaceous glands seem to play the most important part.

For this reason I have called the case one of "seborrhœa nigricans" rather than "black chromidrosis." There is no other case on record, I believe, which exactly parallels the present one, and for that reason I make no reference to the severer cases of black chromidrosis which have been published.

A complete account of the latter affection is given in my article in the *Twentieth Century Practice of Medicine*, vol. v. p. 539, where the symptoms are fully described.

A letter recently received from Dr. Bethune states that no return of the seborrhœic crust has taken place since I saw her, although the skin has an unhealthy look.

DISCUSSION.

Dr. M. B. Hartzell: Cases like this illustrate the need of increased knowledge of diseases of the skin, since there is a multiplicity of names for such affections, showing that we are not at all certain what the exact lesion is. While it has been described as seborrhœa, it has been described as chromidrosis, indicating that some regard it as a disease of the sebaceous glands and others as a disease of the sweat glands. Unna, as is well known, maintains that the sweat glands have a double function, excreting both a watery and an oily fluid; the coil excreting the oil, the duct of the gland excreting the sweat, the water. If that is so, all these cases may be really an affection of the sweat glands. It is a very curious and suggestive fact that fully 75 per cent. of these cases have occurred in young unmarried women with stigmata of hysteria. True, it has been reported in men. It is very evident that our knowledge of this affection is almost entirely confined to its clinical features.

SARCOMA OF THE ABDOMINAL WALL AND PROBABLY OF THE PELVIC VISCERA, WHICH HAS DISAPPEARED UNDER THE USE OF THE X-RAYS.[1]

By GEORGE ERETY SHOEMAKER, M.D.,
GYNECOLOGIST TO THE PRESBYTERIAN HOSPITAL, PHILADELPHIA.

Our knowledge of the influence of the *x*-rays on malignant growths is still in its infancy. Any report of a decided curative action must be tentative. Nearly all the favorable reports have been on superficial growths, and, therefore, a special interest attaches to the present case, because the disease was apparently deeply seated as well as superficial. The unusual location, the microscopic examination of the tissue, the opportunity for examination afforded by abdominal section, and the absence of any other cause than the *x*-rays for the improvement which has occurred, are features which give to this case a certain importance.

The patient who is exhibited this evening is thirty-six years old, married twenty years, and has had three children, the youngest seventeen years old. There have been three miscarriages, the last three months ago, and a stillbirth five years ago. There was no specific history and no enlargement of the glands in groin or occiput. She was referred to me by Dr. M. B. Hartzell on account of a growth in the lower abdomen. There was a history of irregular hemorrhage from June to August, 1902, followed by enlargement of the abdomen and an inflammatory attack, which began August 7th with a chill, followed by temperature of 104° and perspiration. There was no vomiting and no diarrhœa. The soreness, which had continued more or less ever since, was worse in the left ovarian region. When first seen, November 19, 1902, examination showed a swelling in the median line just above the pubic bone and apparently continuous with it. This first appeared three months before, during the illness pre-

[1] Read December 2, 1903.

viously referred to. It had been extremely sensitive, so that ordinary clothing could not be worn, and pain had been so severe as to require a large amount of opium for its relief.

The mass was about two and a half inches in diameter, prominent, dark reddish in color, smooth, rounded, and immovable, appearing to infiltrate the tissues at the insertion of the recti muscles into the pubic bone. There was some tenderness. The skin was unbroken. There was almost constant severe pain in the lower abdomen, bearing down in the bladder, and frequent urination, with pain at the end of the act.

As a pelvic mass was detected to the left of the uterus, she was admitted to the Presbyterian Hospital, and an abdominal section was performed November 26, 1902, above the limits of the superficial tumor, but below the umbilicus. After tying off and removing thickened and adherent omentum, it was found that the appendix, right tube, and ovary were free from adhesion and were not diseased. The rectum, the uterus, and the left tube and ovary were inseparably united by an apparent infiltration, but had a certain range of motion, considered as one mass. The tumor in the lower abdominal wall was united to this mass by a process of thickened tissue a little to the left of the median line. The finger tips could be inserted part way between the pelvic mass and the tumor in the abdominal wall. The whole appearance of the structures suggested a new growth, which it was considered unwise to attempt to remove, owing to the involvement of bowel and bladder in the mass, and because it would have been impossible to close the wound if the portion of the abdominal wall involved were taken out. The abdominal incision was, therefore, closed, and a cut made directly into the suprapubic growth. This was found to be gristle-like, pale yellow, rigid, and non-vascular. There was a deep-seated point of degeneration, where there was about one half a drachm of grayish material undergoing liquefaction. No sinus existed, and there was no pus. A generous piece was removed for microscopic examination, leaving a pit with a firm wall, which was drained with gauze. The upper wound healed promptly, without suppuration, leaving a granulating pit in the tumor. The patient was now referred to the *x*-ray laboratory, under the charge of Dr. William S. Newcomet, for treatment, which was begun January 25, 1903, and continued first twice a week, then once a week, until the end of September, or in all about nine months. The total number of exposures was forty-nine.

The tube was so placed as to cause the rays to strike the abdominal wall just above the pubis and enter the pelvis at an angle of 45 degrees, thus avoiding, as far as possible, the pelvic bones. The first three exposures produced a marked change in the pit, from which tissue had been cut out. It healed in four weeks from beginning treatment, or in eight weeks after the operation.

The tube used was from Queen's establishment. The spark gap was from three to four and a half inches. The current was from a six-cell storage bat-

tery, with a fifteen-inch coil. The distance from the skin surface was ten inches. There was no burn. I examined the patient on February 23d. The pit in the tumor had healed and the mass above the pubis was almost entirely gone, leaving a small depressed scar in the centre. The uterine and tubal mass was smaller and very movable. A very great improvement continued and the pelvic enlargement rapidly disappeared. July and August menstrual periods were missed in 1903, and a miscarriage occurred at about two and a half months, under the care of Dr. C. B. Longnecker. November 30, 1903, one year after coming under observation, my examination showed a depressed scar in the abdomen, with a brownish area of discoloration about it. The infiltration of the abdominal wall was entirely gone, and no pain or soreness was present. The uterus was forward in normal position, freely movable, enlarged to the size of a two months' pregnancy, and symmetrical. Its canal measured three and three-quarters inches. No tubal or ovarian enlargement could be felt, and no pelvic abnormality except the increased size of the uterus referred to. The patient's weight had increased sixteen pounds during the past five months, from 137 to 153 pounds. She was sleeping and eating well, had a florid color, and was feeling better, as she stated, than for five years. The patient deserves some credit for patient continuance of *x*-ray treatment against the advice of her friends.

The question arises in connection with this case as to whether the pelvic mass and the tumor in the abdominal wall were of the same character. The only tissue examined microscopically was from the latter. If not sarcomatous, the pelvic mass could only have been inflammatory. Constant familiarity with the appearance of intra-abdominal inflammation leads me to the conclusion that the condition was not the result of inflammation. Moreover, well-marked inflammatory disease of the pelvis, not of puerperal origin, does not ordinarily undergo complete resolution, and such masses do not disappear completely in a few months without operative removal or drainage. The mere opening of the abdomen and release of omental adhesions is not sufficient to account for the disappearance of the pelvic mass. There can be no question of the action of the *x*-ray on the external portion of the disease, and the inference is a fair one that the entire result is due to the action of the rays.

The microscopic diagnosis was made by Dr. J. Dutton Steele, in charge of the Clinical Laboratory of the Presbyterian Hospital. He writes as follows:

"The section was stained with hæmatoxylin and eosin. The tumor consists of fibrous tissue fat and areas of closely packed spindle and round cells. These cells have oval and round, deeply staining nuclei, and lie closely packed in a delicate intracellular tissue. In the sections examined about one-fourth of the tissue is made up of these areas of closely packed cells. The bloodvessels are not numerous and there are no blood channels

without true walls typical of sarcoma. However, this lack of blood channels would be consistent with a sarcoma developing in dense fibrous tissue. A diagnosis is given of fibrosarcoma.

J. D. STEELE."

The result in this case is more favorable so far than those usually reported. Unfortunately the usual history of deep-seated growths is that, while there is some early improvement, recurrences takes place, or else the disease continues its onward stride. There is nothing in the present situation to make it justifiable to use the *x*-ray instead of removing the growth surgically where such removal is physically possible. After such removal the *x*-ray may be used with advantage to avoid recurrence. During the past year two other cases of malignant disease of pelvic viscera have presented themselves. One was sarcoma of the right ovary and involved omentum, bowel, and bladder, as well as the sac of an inguinal hernia. Extirpation was abandoned, and the *x*-ray is now being used. The other was a large carcinomatous growth of the right ovary, with cystic portions. Its complete removal, while difficult, was successfully accomplished. It had reached a diameter of nine inches in not more than seven months, during which time there had also been four attacks of peritonitis, with vomiting, pain, distention, and fever. This illustrates the fact that these growths are often accompanied by inflammation, and that the occurrence of secondary inflammation must not be allowed to obscure the original diagnosis. The growth of sarcoma is often very rapid, and a single month may make a difference in size which is astonishing. No time, therefore, should be lost in *x*-ray treatment. When such growths are first seen they should be removed immediately, before the rapid infiltration of intestine and other organs makes removal useless, dangerous, or impossible. The reports of partial or temporary improvement of surface growths by the *x*-ray are even now leading the profession into the pitfall of treating growths by the *x*-ray *first*. Would that the evidence at hand justified it, but it does not.

PRESENTATION OF A CASE OF UNILATERAL PULSATING EXOPHTHALMOS.[1]

By CHARLES H. FRAZIER, M.D.

In November, 1899, the patient, a fifteen-year-old schoolboy, was shot in the back of the right ear. The patient vomited some blood, which was supposed to have been due to hemorrhage from the right tonsil, through which the bullet passed. Careful but futile search was made for the bullet. Almost immediately after the accident the patient complained of a thumping noise behind the right ear, and noticed a gradual forward protrusion of the right eyeball. He presented himself at Wills Eye Hospital in March, 1900, when an examination was made by Dr. Charles A. Oliver, who reports as follows: "At the time of the first examination the right eye was found to be proptosed some five millimetres in advance of its fellow, with an external deviation of twenty-two and one-half degrees. There was not any vertical deviation. There was engorgement of both the ciliary and scleral vessels. The cornea was clear. The pupil was three millimetres in diameter. The iris reacted well to light, accommodation, and convergence. The action of the exterior ocular muscles was good except to the nasal side, the inner limbus of the cornea being rotated to about five millimetres away from the temporal side of the internal canthus. Intraocular tension was normal. No pulsation could be heard over the orbit, although a marked thrill, which ceased upon pressure on the corresponding carotid artery, could be felt when the eye was forced back into the orbital cavity. Both direct and indirect vision for form and color were normal in each eye. Range and power of accommodation were good for age and refractive condition. Just below the right mastoid region there was a scar, showing the point of entrance of the bullet. A pulsatory thrill, more marked than the orbital one, could be felt in this situation."

In April, 1900, Dr. Oliver referred the patient to me, and on the 17th of that month I ligated the right common carotid artery. Immediately after the operation the pulsation in the orbit ceased; but this, together with the bruit, soon returned—neither, however, to a degree quite so marked as before the operation. The exophthalmos and the pulsation of the retinal

[1] Read March 4, 1903

vessels were somewhat reduced, perhaps, but in general the operation may have been said to have been unproductive of results.

The next observation was made January 24, 1901, fifteen months after the injury and nine months after the ligation of the right common carotid artery. At this time the bruit and thrill were quite as loud as before, and the dilatation of the retinal vessels had increased, and there was in addition an internal strabismus. The patient was put to bed upon a Tuffnell diet as preparatory treatment to ligation of the left internal carotid artery. This operation was performed February 2, 1901. While the ligature was being applied an assistant who was appointed to listen to the bruit with the stethoscope reported that no change in the intensity of the bruit could be detected after the ligature was tied. In the twenty-five days during which the patient was in the hospital after the second operation there was no striking modification in the subjective or objective phenomena, save that on the eleventh day after the operation, for a period of seventeen hours, the bruit and thrill disappeared. For a period of two months after his discharge from the hospital the patient reports that no change was noted, but that from that time on the exophthalmos gradually became less conspicuous and the bruit less audible.

October 14, 1903, three years after the original accident and twenty-one months after the second operation, the patient collided with one of his playmates. During that day he observed a marked diminution of the bruit and exophthalmos, and on the following morning the bruit had disappeared, and has never recurred. Three months later (January, 1903) the patient reported at the hospital for a final examination. There was no pulsation of the orbit, no thrill, and no bruit; the exophthalmos had entirely disappeared, his general condition was perfect, and there were no cerebral phenomena.

Dr. de Schweinitz reported that the vision and accommodation were normal; that there was no failure of rotation of the eyeballs in any direction; that while there is no exophthalmos, both eyes seem slightly prominent. There is no abnormality of movement of brow or lids; the pulsation of retinal veins is more marked in the left (unaffected) than in the right eye.

In the subcutaneous tissue beneath the jaw just above and to the left of the hyoid bone can be felt a small hard object, which is unquestionably the bullet.

THE BLOOD IN EPILEPSY: EXPERIMENTS ON ANIMALS.[1]

(Preliminary Report.)

By F. SAVARY PEARCE, M.D.,

and

L. NAPOLEON BOSTON, A.M., M.D.

The difficulties of the study of diseases lie chiefly in the determination of pathogenesis and etiology. In many nervous affections the causes are legion. What may be the primary or initial exciting factor in the production of one of the most enigmatic of all diseases—the so-called idiopathic epilepsy—has never been made out. The object of this experimental study is to determine if changes in the blood may be a possible cause, in part at least, of this terrible disease, in which there must exist unstable neuron function and irritability of the motor cortex.

We have excluded every case of epilepsy in the experimentation where there was known organic disease resident in the brain or its membranes; in the kidneys, heart, or other organs; and have, therefore, limited the cases studied to those of essential epilepsy as we understand it to-day in the light of the meagre scientific data upon this subject. The cases were all selected with great care as to the above outline from the nervous wards of the Philadelphia Hospital. Dr. S. R. Seifert assisted us in the blood counts made upon the patients and the animals. We desire to thank this gentleman for his aid in the work.

[1] Read April 1, 1903.

The plan of such a study must be broad, lest false deductions be easily made. Appreciating such a desideratum, the writers in this necessarily preliminary contribution are well aware of its limitations. We hope to pursue the study further as new light may present to guide in the future. Attempt has been made here, as indicated, to exclude organic cases of epilepsy, such as those following trauma, fracture of the skull, meningitis; also congenital cases, believing that such intrinsic known causes for the then symptomatic attacks are explained by direct irritation to the motor cortex, epileptic seizures following.

But what causes the more subtle attacks designated to-day as essential is the more difficult problem. We do know that complicating diseases, as the acute infectious disorders, will frequently stay "attacks" for more or less long periods of time; that pregnancy will do the same thing in some cases, but you *never* know in which case. Theories come fast enough as to the *why* of it all. Can antitoxins or incompatible poisons of other diseases counteract a poison which is occasionally accumulating and ordinarily exciting attacks, etc.? Can a sudden fright produce such a restored competence of the chemistry of the body in rare cases that no such toxins are further developed and the epilepsy is cured? Dr. Weir Mitchell has told us (Pearce) of a case where the excitement of battle in the period of our Civil War seemed to be *the* curative agent.

Since no definite histological change has been found in acquired idiopathic epilepsy, inherent irritability of the cortical cells remains as an only explanation for the existence of the disease, if we do not think of disturbed metabolism being, perhaps, the exciting cause, or of some other poison circulating in the blood. We know very well clinically that constipation will precipitate attacks in most patients the subject of epilepsy. It is not definitely known whether this is a simple reflex or due to absorption of toxins.

Hence it is that blood studies are most desirable in epileptics, as is also the careful observation of the urine and other bodily excretions and secretions. But as the bloodvessels ultimately must carry any abnormal substance to the brain to act as exciting

causes of attacks, the poison *must* at times be resident, therefore, in the blood serum or in the corpuscles.

For this reason we made observations on *seven* cases of idiopathic epilepsy as to the number of red and white blood cells present per c.mm.; the percentage of hæmoglobin; differential leukocyte counts in the patients before and after epileptic seizures; and in animals, both before and after inoculation with defibrinated blood of epileptics, with a view of ascertaining the degree of toxicity common to epileptic bloods. The accompanying experiments will elucidate our findings:

Blood Count Series of Seven Cases of Idiopathic Epilepsy.

CASE I.—June 16. E. McL., aged sixteen years; subject to convulsions for the last ten years about twice a week, becoming dizzy, then falling; never bit tongue nor sustained personal injury in falling. Does not void urine during attacks. His general appearance is good; heart, lungs, and reflexes appear normal. Hæmoglobin, 74 per cent.; red blood corpuscles, 5,190,000; white blood corpuscles, 10,600. Differential leukocyte count: polymorphonuclears, 68 per cent.; large lymphocytes, 2 per cent.; small lymphocytes, 18 per cent.; large mononuclears, 5 per cent.; eosinophiles, 0.5 per cent.; broken eosinophiles, 0.5 per cent.; myelocytes, 3.5 per cent.; transitionals, 2.5 per cent.

CASE II.—July 28, 1902. H. R., aged twenty years. Family presents no epileptic history; had attacks since six years of age; occasionally has spells of melancholia, never has an aura; attacks most frequent at night, irregular in time. General appearance good; general condition good. Hæmoglobin, 73 per cent.; red blood corpuscles, 5,490,000; white blood corpuscles, 18,000. Differential leukocyte count: polymorphonuclears, 72 per cent.; large lymphocytes, 4 per cent.; small lymphocytes, 15 per cent.; large mononuclears, 9 per cent.

CASE III.—J. R., aged thirty-five years, has been subject to convulsions all his life; major convulsion every two or three weeks, with an occasional interval of four weeks. General con-

dition good; heart and lungs normal. Hæmoglobin, 85 per cent.; red blood corpuscles, 5,520,000; white blood corpuscles, 13,000. Differential leukocyte count: polymorphonuclears, 62.5 per cent.; large lymphocytes, 2.5 per cent.; small lymphocytes, 20.5 per cent.; eosinophiles, 0.5 per cent.; broken eosinophiles, 2 per cent.; transitionals, 3.5 per cent.; large mononuclears, 8 per cent.; polymorphonuclears and eosin granules, 0.5 per cent.

Case IV.—July 31, 1902. J. F., aged forty-seven years, has been subject to convulsions at irregular intervals since his eighth year, at present about seven per month. General appearance good; general condition good. Blood count: hæmoglobin, 76 per cent.; red blood corpuscles, 4,610,000; white blood corpuscles, 7400. Differential leukocyte count: polymorphonuclears, 29 per cent.; large lymphocytes, 17 per cent.; small lymphocytes, 13 per cent.; eosinophiles, 1 per cent.; broken eosinophiles, 1 per cent.; large mononuclears, 37 per cent.; transitionals, 2 per cent.

There were in this case also a few megalocytes, few shadow cells, few poikilocytes, and several of some that appear to be broken polymorphonuclear cells.

Case V.—August 6, 1902. L. F., aged fifty-three years, had convulsions every week or two for the last fifteen years, occurring sometimes once a month. General appearance and physical condition is good. Blood count: hæmoglobin, 86 per cent.; red blood corpuscles, 5,060,000; white blood corpuscles, 11,500. Differential leukocyte count: polymorphonuclears, 42.5 per cent.; large lymphocytes, 12.5 per cent.; small lymphocytes, 16.5 per cent.; eosinophiles, 1 per cent.; broken eosinophiles, 2 per cent.; large mononuclears, 19 per cent.; transitionals, 4.5 per cent.; myelocytes, 2 per cent.

Case VI.—August 8, 1902. J. Y., aged thirteen years, had convulsions of irregular occurrence for about the last five years, getting dizzy and falling, froths at the mouth, does not bite the tongue. General appearance good; general condition good. Blood count: hæmoglobin, 63 per cent.; red blood corpuscles, 5,620,000; white blood corpuscles, 11,400. Differential leuko-

cyte count: polymorphonuclears, 43.5 per cent.; large lymphocytes, 3 per cent.; small lymphocytes, 30 per cent.; eosinophiles, 3 per cent.; large mononuclears, 15 per cent.; myelocytes, 2.5 per cent.; transitionals, 3 per cent.

Case VII.—P. C., aged fifty-eight years, has had convulsions since birth; very nervous, bites the tongue, grits the teeth; has convulsions about four to six times per month, irregular in time. General physical condition good; general appearance fair. Blood count: hæmoglobin, 76 per cent.; red blood corpuscles, 4,890,000; white blood corpuscles, 21,200. Differential leukocyte count: polymorphonuclears, 69.5 per cent.; large lymphocytes, 3.5 per cent.; small lymphocytes, 9.5 per cent.; eosinophiles, 3.5 per cent.; broken eosinophiles, 1 per cent.; large mononuclears, 9.5 per cent.; transitionals, 3.5 per cent. Slight poikilocytosis and moderate number of broken and irregular polymorphonuclear leukocytes.

Conclusions. From these seven blood estimations from as many cases it would seem that there is in idiopathic epilepsy a fairly well-marked chlorotic type of anæmia. There was a leukocytosis, too, in all but one of the seven cases where the estimation showed 7400 white cells per c.mm. In one the count was 18,000; in another 10,000; in another 13,000 cells per c.mm. These counts were made three to four hours after a limited meal in all cases.

The findings by differential leukocyte counts cannot be said to be of striking interest; yet worthy of mention are the facts that the polymorphonuclear cells were reduced in three instances equally in 29, 42, and 43 per cent., respectively. This decided reduction in the polynuclear cells was not associated with an increase in the lymphocytes, as is the case where this change be induced by malnutrition, starvation, etc. Myelocytes were found in three instances reaching a maximum of 3.5 per cent. The red cells were approximately normal in numbers. In all the bloods there was a moderate degree of poikilocytosis, and this finding was especially marked in those where the hæmoglobin was greatly reduced, the degree of distortion bearing a direct correlation to the loss in hæmoglobin.

There was to be seen here and there red cells showing unstained punctate areas scattered throughout their protoplasm. Punctate basophilia was present in the blood from three of these cases.

The above examinations, therefore, reveal no conclusive evidence of change *per se* in the cells themselves in the epileptic. But it still is possible that a toxin may be circulating, being held in suspension in the blood serum, and which may excite attacks.

Apropos of this at a time four or five years ago, from a case of idiopathic epilepsy, one of us injected 20 c.c. of defibrinated blood into the vein in a case of pernicious anæmia. About seven days later the patient had two epileptic seizures, and was followed by one or more attacks daily for a period of four or five days, when he died from the exhaustion of the anæmia. Dr. F. P. Henry has performed a similar inoculation in the presence of one of us (Boston), and here, too, the case of anæmia developed true epilepsy.

As control test the blood of two healthy students was studied, as was that of epilepsy. The blood from each student was injected into the peritoneal cavities of two healthy rabbits, and the blood of these animals examined daily for one week, finding no alteration whatever in the hæmoglobin, red cells or leukocytes.

We also took typical cases of idiopathic epilepsy with the intent to make experimental study on healthy rabbits, counting the rabbits' blood before and after the injection of defibrinated blood antiseptically drawn from the epileptic patient. We found blood changes in rabbits injected with the blood of idiopathic epilepsy (Cases VIII. and IX.) given below.

We will leave the experiments now to be recited to speak for themselves, believing that suggestions from this work will be manifest, and that, presumably, some hæmolytic enzyme is a part, at least, of the pathogenesis of essential epilepsy.

In order to obtain an average blood count for the healthy rabbit when kept in captivity, and subjected to the environments characteristic of the laboratory, we found the hæmoglobin between 65 and 75 per cent., 68 to 70 being the percentage for most

animals; yet at times animals apparently well nourished showed blood which gave a much lower reading. Examination of the average number of erythrocytes in twenty animals, examined at the laboratory, showed these cells to vary in numbers between 4,500,000 and 5,100,000 per c.mm. The leukocyte count taken from the same records were found most often between 5000 and 6000; and in but a few instances did these cells exceed 8000 per c.mm. Differential leukocyte counts were far less constant, and, in fact, were seen to vary greatly in the same animal at different days, independent of inoculation.

Blood counts of two idiopathic cases of epilepsy were made on June 7, 1902.

Case VIII.—The first case, W. H., male, aged thirty-five years: blood examined after last of four severe seizures in twenty-four hours, which were on June 1, 1902. Blood count normal; exact count mislaid. The differential leukocyte count was: polymorphonuclears, 78 per cent.: large lymphocytes, 6 per cent.: small lymphocytes, 7 per cent.; myelocytes, 7 per cent.; transitional myelocytes, 2 per cent.

June 13th. W. H. was bled to-day. He has had no attack in the interval. The blood was drawn by hypodermic syringe from the median cephalic vein, and 10 mm. were injected subcutaneously into a small rabbit. The count of this rabbit before injection was normal.

Results in rabbit from above two injections: June 17th. Four days after first injection, and twenty-four hours after second. Rabbit (A)—small rabbit: hæmoglobin, 46 per cent.; red blood corpuscles, 4,490,000; white blood corpuscles, 8000. Differential leukocyte count: polymorphonuclears, 35 per cent.; large lymphocytes, 21 per cent. (*i. e.*, cells which corresponded to the large lymphocytes in man).

Small lymphocytes, 10.5 per cent.; eosinophiles (very irregular as to size of granules), 29 per cent.; myelocytes, 3.5 per cent.; normoblasts, 1 per cent.; poikilocytosis marked.

June 19th. W. H. No attacks since June 7th. Bled again to-day, and 20 mm. injected for the third time into a rabbit.

Rabbit showed marked trembling shortly after inoculation, lasting about half a minute, but no true convulsion.

June 20th. Count of small rabbit (A) seven days after first injection, four days after second, and twenty-four hours after the third: hæmoglobin, 55 per cent.; red blood corpuscles, 4,680,000; white blood corpuscles, 5600. Differential leukocyte count: polymorphonuclears, 15 per cent., all showing some eosinophilic granules; large lymphocytes, 14 per cent.; small lymphocytes, 25 per cent.; eosinophiles, 40 per cent.; myelocytes, 6 per cent.

June 25th. Count of gray rabbit (B), W. H's non-defibrinated blood, six days after inoculation: hæmoglobin, 48 per cent.; red blood corpuscles, 3,960,000; white blood corpuscles, 7200. Differential leukocyte count: polymorphonuclears, 18 per cent.; large lymphocytes, 24 per cent.; small lymphocytes, 18 per cent.; eosinophiles, 2 per cent.; polymorphonuclears showing eosinophile granules, 36 per cent.; myelocytes, 2 per cent.

Normal count of rabbit (B) before defibrinated blood injection experiments.

June 26th. Count of gray rabbit (B) before inoculation with defibrinated blood of W. H.

Differential count: polymorphonuclears, 3 per cent.; polymorphonuclears with fine eosinophile granules, 16 per cent.; large lymphocytes, 35 per cent.; small lymphocytes, 15 per cent.; myelocytes, 5 per cent.; myelocytes with eosinophile granules, 1 per cent.; eosinophiles, 24 per cent.

Defibrinated Blood Experiments.

June 26th. W. H. (same, Case VIII.); no convulsions. Bled this afternoon and 45 mm. of defibrinated blood injected into peritoneal cavity of small gray rabbit (C).

June 27th. Twenty-four hours after rabbit was injected with 45 mm. of defibrinated blood from W. H.: hæmoglobin, 79 per cent.; red blood corpuscles, 6,870,000; white blood corpuscles, 8600. Differential leukocyte count: polymorpho-

nuclears, 1 per cent.; polymorphonuclears with eosinophile granules, 55 per cent.; large lymphocytes, 13 per cent.; small lymphocytes, 9 per cent.; eosinophiles, 9 per cent.

June 30th. Patient had no attacks; bled, and 45 mm. of defibrinated blood injected into gray rabbit (B), peritoneal cavity.

June 30th. Same rabbit. Hæmoglobin, 84 per cent., a slight rise (5 per cent.); red blood corpuscles, 6,980,000; white blood corpuscles, 12,400 (a rise of 3800 cells). Differential count: polymorphonuclears, 8 per cent.; polymorphonuclears with fine eosinophile granules, 41 per cent.; large lymphocytes, 8.5 per cent.; large lymphocytes with eosinophile granules, 1 per cent.; small lymphocytes, 28.5 per cent.; eosinophiles, 11.5 per cent.; large mononuclears, 1 per cent. After above count 45 mm. of defibrinated blood injected into peritoneal cavity of the rabbit (B).

July 1st. Twenty-four hours after injection, as above, rabbit showed some indisposition to eat. Lay crouched in corner. Hæmoglobin, 77 per cent., a slight fall (7 per cent.); red blood corpuscles, 6,370,000, no marked change; white blood corpuscles, 17,000, a rise of 4600 cells. Differential leukocyte count: polymorphonuclears, 4 per cent.; polymorphonuclears with fine eosinophile granules, 25 per cent.; large lymphocytes, 9 per cent.; small lymphocytes, 41 per cent.; large mononuclears, 9 per cent.; eosinophiles, 8 per cent.; transitional leukocytes, 2 per cent.; myelocytes, 2 per cent.; moderate poikilocytosis present.

July 2d. Forty-eight hours after above injection: hæmoglobin, 78 per cent.; red blood corpuscles, 6,610,000; white blood corpuscles, 17,500. Differential leukocyte count: polymorphonuclears with eosinophile granules, 29 per cent.; large lymphocytes, 4 per cent., a fall; small lymphocytes, 9 per cent., fall of 37 per cent. in twenty-four hours; large mononuclears, 3 per cent.; eosinophiles, 54 per cent., a rise; transitional leukocytes, 1 per cent.; moderate poikilocytosis, few shadow cells.

July 3d. Seventy-two hours after injection this rabbit showed indisposition to move about; also coughed some and had some

mucous discharge from nose. Hæmoglobin, 44 per cent., a loss of 35 per cent. from normal; red blood corpuscles, 6,570,000; white blood corpuscles, 16,000. Differential count: polymorphonuclears with fine eosinophile granules, 51 per cent.; small lymphocytes, 15 per cent.; large lymphocytes, 3 per cent.; eosinophiles, 2 per cent.; eosinophiles irregular and broken, 13 per cent.; large mononuclears, 12 per cent.; large mononuclears with eosinophile granules (?), 1 per cent.; transitionals, 1 per cent.; transitionals and eosinophile granules, 2 per cent.

July 5th. W. H. has had no attacks, but complains of general weakness and shows questionable physical signs of phthisis. Was bled again, and 60 mm. of defibrinated blood injected into gray rabbit (B), peritoneal cavity.

July 5th. Rabbit to-day injected with 60 mm. of defibrinated blood from W. H.

July 6th. Rabbit showed tremors and rigidity over entire body for about one hour this morning; still coughs some, and at times sonorous respiration. Differential count: polymorphonuclears, 1.5 per cent.; polymorphonuclears with fine eosinophile granules, 30 per cent.; large lymphocytes, 5.5 per cent.; small lymphocytes, 37 per cent.; large mononuclears, 5 per cent.; eosinophiles, 9 per cent.; broken eosinophiles, 12 per cent.

July 8th. W. H. has had no attacks. Complains of continuous cough. Anorexia. Very weak.

July 9th. Sputum examination for tubercle bacilli negative.

July 10th. Five days after last injection of rabbit: white blood corpuscles, 10,600. Differential count: polymorphonuclears, 3 per cent.; polymorphonuclears with fine eosinophile granules, 26 per cent.; large lymphocytes, 14 per cent., an increase; small lymphocytes, 20 per cent.; eosinophiles, 5 per cent.; eosinophiles broken and irregular, 11 per cent.; myelocytes, 10 per cent.; large mononuclears, 9 per cent.; transitionals, 2 per cent.

July 11th. W. H. has had no attacks. Bled, and 80 mm. of defibrinated blood injected into gray rabbit (B), peritoneal cavity.

July 14th. No attacks; 90 mm. injected into peritoneal cavity of gray rabbit (B).

July 14th. Gray rabbit (B) inoculated with 90 mm. (*twice the usual dose*) blood of W. H. into peritoneal cavity. Rabbit showed marked tremors of both forelegs all day; also appeared stupid. Blood count twenty-four hours later: white blood corpuscles, 162,800—*enormous rise in leukocytes.* Differential leukocyte count: polymorphonuclears, 2.5 per cent.; polymorphonuclears with fine eosinophile granules, 38 per cent.; large leukocytes, 10.5 per cent.; small leukocytes, 21.5 per cent.; large mononuclears, 8.5 per cent.; eosinophiles, 3.5 per cent.; eosinophiles broken, 8.5 per cent.; myelocytes, 1 per cent.; transitional leukocytes, 5 per cent.; marked poikilocytosis.

July 17th. Count of gray rabbit (B) three days after last injection: leukocytes, 11,000, a decided drop, but still above normal. Differential leukocyte count: polymorphonuclears, 2 per cent.; polymorphonuclears with fine eosinophile granules, 53 per cent., a rise toward normal; large lymphocytes, 6 per cent.; small lymphocytes, 15 per cent.; eosinophiles, 9 per cent.; broken eosinophiles, 7 per cent.; large mononuclears, 6 per cent.; myelocytes, 1 per cent.; transitionals, 1 per cent.

An analysis of the results of these two sets of careful experiments with the blood of epilepsy (one with blood as it was drawn from the patient, and again where it was defibrinated) were about the same.

The defibrinated blood results can be stated in one case as follows: It will thus be seen that the hæmoglobin rose from 65 per cent. to 79 per cent. and later to 84 per cent.; then, finally, to 44 per cent. seven days after last injection. The leukocytes in twenty-four hours rose from 8000 to 12,000 after first injection; and after second injection from 12,000 to 17,000. In both of these injections 45 mm. of defibrinated blood was used. On July 11, 1902, 80 mm. more of defibrinated blood was injected into the peritoneal cavity of the same rabbit; on July 14th the injection was again repeated, giving 90 mm. of defibrinated blood (about twice the dose usually given). All day long the rabbit was very ill (was rigid and tremulous), and twenty-four hours later

its white blood cells reached the enormous number of 162,800 per cm., which then rapidly fell to 11,800 two days later. This must show some extreme toxic condition of the blood in the epileptic man at this time, from whom the blood was taken. It was capable of producing a profound leukocytosis, which very soon disappeared in the rabbit.

The eosinophiles fell after injection of the rabbit from 24 per cent. to 9 per cent., but on the sixth day after first large injection (twenty-four hours after last large dose) rose again to 54 per cent. Eighteen days after injection, when the leukocytes were highest, too, the animal showed that he was very ill, with especial tremor of the front legs, etc. At this date the eosinophiles were 13 per cent. (about normal). The polynuclears rose from 18 per cent. to 36 per cent. twenty-four hours after injection, with marked reduction in the mononuclear cells; also when the large mononuclear cells went up the lymphocytes went down, and *vice versa*. The red blood cells also showed marked changes, poikilocytosis, etc.

It would seem from the experiments in this case that there was a profound toxæmia set up in the rabbit, as shown by the definite blood changes seen in the animal. There was no corpuscular change noted in the patient; therefore, if the blood changes in the rabbit were due to alteration in the blood it was principally in the serum—a toxic process. That the patient's cells were not disturbed in the differential count does not imply that such marked changes as we find in this rabbit are not due to a toxin of some sort from his blood, whose own cells may have become immune.

Case IX.—J. D., male. Second case bled June 8, 1903. Blood count after five attacks in five days was mislaid. Hæmoglobin, 63 per cent. Differential count in this patient: polymorphonuclear cells, 70 per cent.; large lymphocytes, 13 per cent.; small lymphocytes, 11 per cent.; eosinophiles, 1 per cent.; myelocytes, 4 per cent.; transitionals, 1 per cent. There was present a degree of moderate poikilocytosis, and many of the red cells were pale and showed punctate areas of pallor.

June 13, 1902. J. D., since bled, has had following attacks: June 9th, 4; June 10th, 2; June 11th, 3; June 12th, 1; June 13th, 4, up to 5 P.M., at which time he appeared quite stupid and averse to answering questions. His knee reflexes were much reduced. Following an attack blood was drawn, and 20 minims were injected intraperitoneally into a large rabbit.

June 16th. J. D., very stupid for last two weeks, has had following attacks: June 14th, 6; June 16th, 2. Following a slight attack blood was drawn, and 20 minims were injected intraperitoneally into this animal.

Normal blood count of rabbit (C): Hæmoglobin, 50 per cent.; red blood corpuscle count lost, but was about normal; white blood corpuscles, 9000.

June 17th. The large rabbit four days after first and twenty-four hours after second injection showed: hæmoglobin, 50 per cent.; leukocytes, 14,200; red cells, 6,180,000. Differential leukocyte count: polymorphonuclears, 39.5 per cent.; small lymphocytes, 42.5 per cent.; large lymphocytes, 10 per cent.; eosinophiles, 2 per cent.; myelocytes, 7 per cent. Many normoblasts were present.

June 19th. J. D. bled this afternoon at three o'clock, and 20 minims injected intraperitoneally into the same animal.

June 20th. Twenty-four hours after last injection. Hæmoglobin, 63 per cent.; red blood corpuscles, 5,890,000; white blood corpuscles, 10,500. Differential count: polymorphonuclears, 3 per cent.; large lymphocytes, 24 per cent.; small lymphocytes, 8 per cent.; eosinophiles (irregular), 56 per cent.; myelocytes, 6 per cent.; moderate poikilocytosis.

June 20th. J. D. died at 4 P.M. during a convulsion. Rabbit count to be continued without further injection.

June 25th. Large rabbit, six days after third injection, showed: hæmoglobin, 66 per cent.; red cells, 4,940,000; leukocytes, 18,800. Differential leukocyte count: polymorphonuclears containing numerous eosinophile granules, 15 per cent.; polymorphonuclears (true), 3 per cent.; large lymphocytes, 23 per cent.; small lymphocytes, 8 per cent.; eosinophiles, 46 per cent.;

myelocytes, 5 per cent. There was a moderate grade of poikilocytosis.

July 1st. Last count, twelve days after last injection: hæmoglobin, 64 per cent.; red cells, 2,850,000; leukocytes, 10,800.

CONCLUSIONS (Case IX.). Hæmoglobin in rabbit before any inoculation, about 50 per cent. Gradual rise after each injection to 66 per cent. six days after last injection. Leukocytes 9000 before injection; 14,000 twenty-four hours after the first injection, and fluctuated between 10,000 and 18,000 after each successive injection until the sixth day after last injection. Red blood corpuscles fell from 6,000,000 to 2,850,000 twelve days after the first injection. During the period of injections the red blood cells fell over 1,000,000 per c.mm., showing a progressive destructive change. The eosinophiles rose from 1 to 56 per cent. after the second injection. The polynuclear cells fell from 37 per cent. to 3 per cent. within twenty-four hours after the last injection, and rose to 18 per cent. six days later. The tendency to widespread alteration in the proportional relation of the blood cells and hæmoglobin, as well as in this rabbit; the great increase in the number of leukocytes, all coming on soon after the injection of blood from a second case of idiopathic epilepsy, point again toward toxæmia as an existent factor in this disease.

We did not produce distinct convulsions in the rabbit, it is true, but the blood changes were suggestive of toxæmia resulting from the injection of defibrinated blood taken from an epileptic.

It is interesting that these changes were in striking contrast to those changes noted in the leukocytes in ordinary septic processes, where the polynuclear cells show a decided increase. After each inoculation eosinophilia developed within wenty-four hours, which was equal to that observed in the blood of persons suffering from such parasitic diseases as trichinosis and filariasis. This would appear to suggest the necessity for more careful observations as to a possible relation between epilepsy and parasitic infections.

Incidentally it should be mentioned that Bra found in 70 out of 100 cases the micro-organism *microbe* he describes, and rabbits inoculated with his organism died in clonic convulsions. The number of the "neurococci," as he calls them, increased with an impending seizure and diminished again afterward, until none could be found during the intermission.

APPENDIX.

ABSTRACT OF THE REPORT OF THE COMMITTEE ON MÜTTER MUSEUM, 1903.

The Committee of the Mütter Museum submitted their report for the fiscal year ending November 30th.

The finances of the Museum were in an extremely satisfactory condition.

The Committee reported the continuation of the work of rearranging and recataloguing the collection of specimens—nearly 3000 had been renumbered, replaced, and prepared for the card catalogue. These comprised the specimens on the floor and first gallery. Those on the upper gallery will be restudied and rearranged in the future. During the year large numbers of students from the University of Pennsylvania and the Jefferson and Medico-Chirurgical Colleges have, under direction of the college professors, examined and studied the pathological specimens, especially those illustrating the injuries, diseases, and deformities of the bones and joints. During the present session the number of students availing themselves of these opportunities is increasing greatly. Not a single specimen has been lost or injured, and the best order and discipline have been preserved.

In December, 1902, Major Lagarde, Surgeon, U. S. A., delivered a written address, and this year a lecture on Aneurism and Arteriosclerosis has just been delivered by Dr. C. N. B. Camac, of Cornell University College of Medicine, in New York City. On each occasion the attendance was large.

SUMMARY OF THE REPORT OF THE LIBRARY COMMITTEE FOR 1903.

The number of volumes now in the Library is 69,617—2374 more than were reported last year. This number is exclusive of duplicates, excepting 1595 second copies of the more important and most used journals, which are retained as reserves to replace volumes that are worn out.

The General Library contains	53,075
The Lewis Library contains	13,203
The S. D. Gross Library contains	3,122
The Library of the Obstetrical Society contains .	217

Two hundred and six dollars and sixty cents has been received from the sale of duplicates, besides an exchange account of $300 with the New York Medical Book Company, and there are 1969 still on hand, which will be disposed of as rapidly as possible. There are more than 80,000 unbound reports, transactions, theses, dissertations, and pamphlets.

The Library receives regularly by purchase or exchange 410 medical periodicals—80 American and 330 foreign—and, in addition, 233 American and 83 foreign current numbers of journals have been presented chiefly by editors.

Nineteen hundred and fifty-six inaugural dissertations have been received.

The Library exchanges publications with thirteen foreign medical schools.

There have been received during the year from all sources 2943 volumes, 10,216 pamphlets, and 33,749 numbers of medical periodicals.

Six hundred and sixty new publications, forty-five of which were written or edited by Fellows of the College, have been added to the Library.

The donors to the Library number 270, of whom each of the following presented twenty-five volumes or more:

Dr. John B. Deaver	200	volumes.
Dr. Wm. B. Atkinson	187	"
Dr. James C. Wilson	143	"
Dr. George W. Norris	102	"
Dr. Hobart A. Hare	99	"

Dr. Charles K. Mills	92	volumes.
Dr. Charles D. Hart	81	"
Dr. Judson Daland	74	"
Dr. Reinhard Weber	85	"
Dr. J. P. Tunis	64	"
Dr. H. C. Wood	60	"
Dr. F. R. Packard	43	"
Estate of Mr. Joseph Zentmayer	27	"
Pathological Society	27	"
Dr. H. H. Kynett	25	"
P. Blakiston's Son & Co.	43	"
Saunders & Co.	36	"

The following donations were also received:

Lea Brothers & Co.	16	"
J. B. Lippincott Co.	16	"
F. A. Davis Co.	9	"

And a large number of pamphlets, reprints, and journals have been presented by Fellows of the College.

The Library is especially indebted to Dr. George W. Norris for the gift of the original colored drawings of eye-grounds from which the plates of the famous Jaeger *Atlas* were produced. These pictures were all painted from life by Jaeger's own hand, and are invaluable as a well-known landmark in the progress of ophthalmology. They were sold by his executors after Jaeger's death, and purchased by Dr. Norris' father for $2400. Dr. Norris has also presented a large number of paintings from cases of eye disease occurring in the late Dr. W. F. Norris' own practice. These paintings illustrate diseases both of the fundus and of the anterior parts of the eye, and are faithfully and artistically painted—nearly all of them by Miss Margaretta Washington. Aside from their intrinsic value, they form an interesting memento of our distinguished colleague.

The following books have been purchased by the various funds:

139 by the Library Endowment Fund	$686 00
121 by the Fund for Completing Files of Journals	284 00
50 by the Weir Mitchell Fund	272 00
83 by the John D. Griscom Fund	249 00
68 by the Wm. F. Jenks Fund	226 00
75 by the Wm. T. Carter	207 00
56 by the Henrietta Rush Fales Baker Fund	193 00
60 by the New Book Fund	155 00
19 by the Lewis Rodman Fund	152 00
71 by the Caspar Wistar Fund	152 00
36 by the W. W. Keen Fund	126 00

43 by the J. Ewing Mears Fund	$124 00
25 by the S. D. Gross Fund	102 00
19 by the Luther S. Bent Fund	36 00
12 by the Wm. V. and J. M. Keating Fund . . .	30 00
11 by the Oliver A. Judson Fund	25 00
8 by the J. F. Weightman Fund	25 00
5 by the Philadelphia Medical Society	24 00

The number of visitors to the Library during the year was 5849—882 more than reported last year. The number of books taken out, 3513, an increase of 472; 17,096 books were supplied by the Librarian for consultation in the Library, and a large number were taken directly from the shelves by Fellows of the College.

Cataloguing is proceeding satisfactorily—7197 cards have been written, 3000 more than last year. All new books have been catalogued, but some new volumes of the Hough and Norris Libraries and a number of pamphlets are still uncatalogued.

The work of revising the catalogue has also made more progress than during the preceding year. But $350 remains of the subscriptions collected for this purpose, and additional subscriptions are earnestly desired. All Fellows who use the Library must appreciate the importance of this work.

The work of the employés has been intelligently, faithfully, and efficiently done. The rooms have been, as usual, thoroughly cleaned during the summer, and the Library is in all respects in as good condition as its contracted space admits of.

Respectfully submitted on behalf of the Library Committee by

GEORGE C. HARLAN,
Chairman.

LIST OF PAPERS: SECTION ON OPHTHALMOLOGY.

December, 1902.

A Case of Persistent Hyaloid Artery, by Dr. Edward A. Shumway.

A Case of Retinal Glioma, by Dr. Harold G. Goldberg (by invitation).

Subsequent History of a Case of Sympathectomy for Chronic Inflammatory Glaucoma, by Dr. H. F. Hansell.

A Case of Thrombosis of the Upper Temporal Branch of the Superior Division of the Central Artery of the Retina, by Dr. G. E. de Schweinitz.

January, 1903.

A Case of Conjunctivitis Petrificans, by Dr. Wm. Campbell Posey.

Monocular Blindness following Traumatism, by Dr. E. S. Saylor (by invitation).

Concerning the Tubular Field of Hysteria, by Dr. G. E. de Schweinitz.

Syphilitic Neuro-retinitis, by Dr. John T. Carpenter.

Delayed Union after Iridectomy, by Dr. S. D. Risley.

February, 1903.

A Case of Poisoning by Jamaica Ginger, by Dr. John B. Turner.

A Case of Injury from a Foreign Body, by Dr. William M. Sweet.

A Case of Injury from a Piece of Steel, by Drs. J. Norman Risley and Dr. H. G. Goldberg (by invitation).

Changes in the Static Refraction of the Eye without Notable Pathological Conditions, by Dr. S. D. Risley.

Treatment of Panophthalmitis by the Method of Van Millingen, by Dr. William Zentmayer.

March, 1903.

Special Subject for Discussion: The Treatment of Myopia.

April, 1903.

A Case of Suspected Tuberculosis of the Conjunctiva, by Dr. H. F. Hansell.

A Case of Suspected Sarcoma of the Choroid, by Dr. H. F. Hansell.

A Case Showing the Results of Roentgen Ray Treatment of Extensive Epithelioma of the Eyelids, by Dr. G. Oram Ring.

A Case of Left Lateral Hemianopsia, followed by Loss of the Right Fields, by Dr. John T. Carpenter.

Typical Case of Siderosis Bulbi, by Drs. G. E. de Schweinitz and William M. Sweet.

A Case of Microphthalmos with Orbital Cysts, by Dr. William Zentmayer. Histological Study, by Dr. H. G. Goldberg (by invitation).

October, 1903.

A Case of Paralysis of the Upward Movements of the Eyes, by Dr. Wm. Campbell Posey.

A Case of Enucleation for Glioma of the Retina, in 1892, without Recurrence of the Disease to Date (1903), by Dr. Charles A. Oliver.

Some Cases Illustrating Congenital Anomalies of the Eye, by Dr. G. E. de Schweinitz.

Two Unusual Forms of Keratitis, probably Rheumatic in Origin, by Dr. H. F. Hansell.

A Case of Powder Grain in the Vitreous, by Dr. James Thorington.

The New Element, Radium, by Dr. J. L. Borsch (by invitation).

November, 1903.

A Case of Persistent Hyaloid Artery, by Dr. William Zentmayer.

A Case of Ciliary Processes Visible in the Pupillary Area, by Dr. G. E. de Schweinitz.

A Case of Right Pulsating Exophthalmos, by Dr. Charles A. Oliver.

Protargol-argyrosis of the Conjunctiva, by Dr. G. E. de Schweinitz.

Certain Untoward Results of Tenotomies for Anomalies of Ocular Motility, by Dr. G. E. de Schweinitz.

Some Observations upon the Non-operative Treatment of Squint, by Drs. William Campbell Posey and H. Maxwell Langdon (by invitation).

Is Double Operation for Senile Cataracts Justifiable? by Dr. H. F. Hansell.

WILLIAM M. SWEET,
Clerk of Section.

LIST OF PAPERS: SECTION ON OTOLOGY AND LARYNGOLOGY.

December 17, 1902.

Sections of a Child's Head, by Dr. George B. Wood.

An Improved Syringe for Intratracheal Medication, by Dr. P. S. Donnellan.

A Case of One-sided Dislocation of the Mandible, with Remarks on Reduction by Congenital Manipulation, by Dr. Frank Woodbury.

January 21, 1903.

Remarks on Congenital Clefts of the Palate; a Further Report on Their Operative Treatment and the Results, by Dr. James F. McKernon, of New York (by invitation).

Some Notes on the Surgical Relations of the Facial Nerve, by Dr. B. Alexander Randall.

A Case of Spontaneous Mastoid Exenteration, by Dr. Walter Roberts.

February 18, 1903.

Presentation of Cases, by Dr. Jos. S. Gibb, Dr. G. H. Makuen, and Dr. George M. Coates (by invitation).

A Case of Sinus Thrombosis, by Dr. B. A. Randall.

Drainage of Tympanic Pus through the Eustachian Tube, by Dr. B. A. Randall.

A Case of Brain Abscess Complicating Chronic Suppurating Otitis Media, by Dr. B. H. Potts.

March 18, 1903.

An Address on the Tonsils in Their Relation to the Lymphatic System, by Dr. Henry L. Swain, of New Haven, Conn. (by invitation).

A Case of Paralysis of the Internal Thyroid-arytenoid Muscles, by Dr. W. G. B. Harland.

Cases Showing the Results of Paraffin Injections for Saddle-back Nose, by Drs. D. Braden Kyle and E. B. Gleason.

Several Cases of Interest were presented by Drs. Marshall and Makuen.

April 15, 1903.

A Case of Anomalous Size of the Ascending Pharyngeal Artery, by Dr. Gibb.

A Paper on Middle-ear Suppuration, with Drainage through the Eustachian Tube. Unilateral Salivation from Intratympanic Irritation of the Chorda. A Belated Operation for Sinus and Jugular Thrombosis, by Dr. B. Alexander Randall.

Electric-phono Massage Apparatus, shown by Dr. Bennett, of New York, who with Dr. Stephenson, of Edinburgh, were guests.

May 20, 1903.

A Case of Sinusitis Involving the Lacrymal Duct. A Case of Specific Laryngitis with Obscure History. Result of Operation for the Relief of Ozæna Due to Necrosing Ethmoiditis, by Dr. P. S. Donnellan.

Further Notes on Double Posterior Crycoarytenoid Paralysis in a Case of Typhoid Fever, with exhibition of case. Specimen from a Case of Laryngeal Abscess. Exhibition of a Case of Epithelioma of Larynx under X-ray Treatment, by Dr. Alexander W. MacCoy.

October 21, 1903.

A Clinical Study of the Use of Antitoxin Serum (Dunbar's) in Hay Fever during the Season of 1903. A New and Distinct Advance in its Management, by Dr. A. W. McCoy.

A Case of Stricture of the Œsophagus from Swallowing Muriatic Acid, by Dr. P. S. Donnellan.

Two Cases of Accidents during Operations upon the Tonsils, by Dr. George B. Wood.

A Case of Laryngeal Disease for Diagnosis, by Dr. G. Hudson Makuen.

November 18, 1903.

A Note on Heredity in Ear Diseases, by Dr. B. Alexander Randall.

A Case of Thrombosis of the Lateral Sinus, by Dr. Barton H. Potts.

Some Microscopic Sections on Lacunar Keratosis, by Dr. George B. Wood.

FRANCIS R. PACKARD,
Clerk of Section.

LIST OF PAPERS: SECTION ON GENERAL MEDICINE.

January 12, 1903.

A Patient with Multiple Neuritis, Probably of Gonorrhœal Origin, by Dr. Wm. G. Spiller.

A Patient with Valvular Disease of the Heart, by Dr. J. C. Wilson.

A Case of Probable Gastric Carcinoma Associated with Hyperacidity and Attacks of Stupor, by Dr. Norman B. Gwyn.

A Communication Concerning the Ductus Glands, by Dr. Sajous.

February 9, 1903.

A Case of Cirrhosis of the Liver with Splenomegaly in a Young Man, by Dr. A. A. Eshner.

Congenital Cyanosis, by Dr. Joseph Sailer.

A Contribution to the Study of Human Blood Pressure in Some Pathological Conditions, by Dr. George William Norris.

A Practical Clinical Method for the Determination of Blood Pressure in Man, with Some Remarks on the Methods Hitherto Employed, by Dr. Wm. B. Stanton.

Desquamation in Typhoid Fever, by Dr. David Riesman.

March 9, 1903.

A Patient with Musical Heart Murmur, by Drs. C. J. Judson and J. C. Gittings (by invitation).

A Patient with Grave Anæmia and Splenomegaly, by Dr. J. Alison Scott.

Pulmonary Abscess Producing Dextrocardia: A Case Report, by Dr. T. L Coley.

Concerning the Diagnosis of Liver Disease by Alimentary Levulosuria, by Dr. D. L. Edsall.

A Case of Femoral Thrombosis in Croupous Pneumonia, by Dr. J. Milton Miller.

April 13, 1903.

A Case of Cyanosis of the Extremities, by Dr. A. A. Eshner.

A Case of Cervical Rib, by Dr. David Riesman.

Two Cases of Typhoid Fever, One Complicated by Perforation and the Other with Hemorrhage Simulating Perforation, by Dr. J. M. Anders.

A Case of Sarcoma Cutis, with Photographs of the Patient, by Dr. J. C. Wilson.

Some Remarks on Palpation, by Dr. David Riesman.

Syphilis of the Lung Simulating Phthisis, by Dr. Alfred Stengel.

May 18, 1903.

A Case of Purulent Carditis which had been Successfully Operated Upon, by Drs. J. Alison Scott and Robert G. Le Conte.

Report of a Case of Infection with a Colon Bacillus Simulating Typhoid Fever, by Drs. Joseph Sailer and Joseph S. Evans.

A Case of Splenic Anæmia, by Dr. T. L. Coley.

October 12, 1903.

A Case of Chronic Pneumonia in a Girl aged Thirteen Years, by Dr. Joseph Sailer.

A Case of Typhoid Fever Complicated by Strangulated Meckel's Diverticulum, by Drs. Joseph Sailer and Charles H. Frazier.

A Small Epidemic of Staphylococcus Infection of the Skin Occurring in Cases of Typhoid Fever, by Dr. D. L. Edsall.

A Clinical Report of a Case of Horizontal Dilatation of the Left Auricle (Ewart), by Dr. David Riesman.

A Case of Aneurism of the Abdominal Aorta and Formation of a Large Adventitious Sac, by Dr. William Pepper.

Desquamation after Typhoid Fever, with Particular Reference to the Occurrence of this Condition in Children, by Dr. Alfred Stengel.

November 9, 1903.

A Case of Stricture of the Œsophagus, Complicated by Subdiaphragmatic Abscess, Lobulated Empyema and Purulent Peritonitis, by Dr. T. L. Coley.

Two Cases of Paraplegia Occurring in Smallpox, with Necropsy, by Dr. Wm. G. Spiller.

Some Statistics Regarding Croupous Pneumonia, Especially Concerning its Treatment with Carbonate of Creosote, by Drs. J. Alison Scott and C. M. Montgomery.

S. McC. Hamill,
Clerk of Section.

LIST OF PAPERS: SECTION ON GYNECOLOGY.

December 18, 1902.

Clinical Notes on Cases, by Dr. J. C. Da Costa.

Two Ectopic Gestations within One Year in the Same Woman, by Dr. J. M. Baldy.

Sarcoma of the Uterus, by Dr. H. D. Beyea.

February 19, 1903.

Presentation of Specimens, by Dr. B. C. Hirst.

The Effect of the Toxæmia of Pregnancy upon the Cardiovascular System, by Dr. R. C. Norris.

Presentation of Bossi Uterine Dilator, by Dr. B. C. Hirst.

May 21, 1903.

Conservative Surgery of the Uterine Appendages, by Dr. R. C. Norris.

Albuminuria in Pregnancy, by Dr. Norton Downs.

The Corset in Movable Kidney and Gastroptosis, by Dr. R. G. Le Conte.

Report of Three Cases of Resection of the Five Pairs of Sensory Nerves Supplying the Vulva for Pruritus Vulvæ and Erethism, by Dr. B. C. Hirst.

Demonstration of a Series of Gross Gynecological Specimens Presented in Their Natural Colors, by Dr. B. M. Anspach (by invitation).

A Report of two Cæsarean Sections, by Dr. W. A. N. Dorland.

A Report of a Case of Ruptured Uterus, with Presentation of Specimens, by Dr. J. H. Girvin.

October 15, 1903.

Tarnier's Principle of Forceps Rotation in Occipito-posterior Positions, by Dr. W. Reynolds Wilson.

Report of a Case of Epithelioma of a Fibromyoma of the Uterus, by Dr. Chas. P. Noble.

Report of a Case in which Atmocausis was used, by Dr. B. C. Hirst.

WILLIAM R. NICHOLSON,
Clerk of Section.

INDEX.

ABDOMINAL wall, sarcoma of, 158
suturing the omentum to, 62, 67
Aorta, tortuosity of, 24
Appendix, 179
Abstract of the Report of the Committee on Mütter Museum, 179
Summary of the Report of the Library Committee, 180
Section on Ophthalmology, 183
Section on Otology and Laryngology, 185
Section on General Medicine, 187
Section on Gynecology, 189

BLACK mask of the face, 154
Blood in epilepsy, 164
Boston, L. Napoleon, the blood in epilepsy, 164
Brain, tumor of, 100, 107
Brickell, John, observations on the medical treatment of General Washington in his illness, 90
Brinton, Ward, observations on the medical treatment of General Washington in his illness, 90

CHANCE, BURTON K., the ocular complications of variola, 34
Cirrhosis of liver, 62, 67
Cœliotomy in a case of extrauterine pregnancy, 19

DUPUYTREN'S contraction of the fingers, 75

ENDOTHELIOMA of dura, 100
Epilepsy, blood in, 164
Extrauterine pregnancy, specimen of, 19

FISHER, HENRY M., case of cirrhosis of liver, with ascites, 67
Fracture of base of skull, 40

Frazier, Charles H., case of unilateral pulsating exophthalmos, 162
cirrhosis of liver, 69
tumor of brain, 107
Fussell, M. Howard, case of probable multiple serositis, 55

General medicine, section on, 187
Glossopharyngeus and vagus nerves, a study of, 40
Gynecology, section on, 189

Hartzell, M. B., seborrhœa nigricans, 157
Headaches, neuralgic, relation of, to storms, 71
Henry, F. P., multiple serositis, 59
Hopkins, W. Barton, a new osteoplastic trephine, 21

Intestinal sand, 152
Intradural spinal cyst, case of, 1
Intraneural infiltration of the median and ulnar nerves, 75

Jump, Henry D., case of probable multiple serositis, 55

Keen, W. W., case of cirrhosis of liver, with ascites, 67, 69, 70
successful intraneural infiltration of the median and ulnar nerves during an operation for Dupuytren's contraction of the fingers, 75
Kelly, A. O. J., multiple serositis, 60

Lewis, Morris J., memoir of Francis West Lewis, li
Library committee, summary of report of, 180
Liver, cirrhosis of, 62, 67

McCollin, S. Mason, tumor of brain, 106
Marshall, John, mercurial nephritis, 88
Martin, Edward, a case of intradural spinal cyst, 1
Median and ulnar nerves, intraneural infiltration of, 75
Medical treatment of General Washington, 90
Memoir of Charles Henry Burnett, xliii
of Francis West Lewis, li
Mercurial nephritis, 77
Mills, Charles K., a new osteoplastic trephine, 22
Mitchell, John K., specimen of intestinal sand, 152
Mitchell, S. Weir, relation of neuralgic headaches to storms, 71
Multiple serositis, 55
Musser, J. H., a case of intradural spinal cyst, 1
Mütter Museum, abstract of report of, 179

NEILSON, THOMAS R., case of suturing the omentum to the abdominal wall for the relief of ascites due to cirrhosis of the liver, 62
Nephritis, mercurial, 77
Neuralgic headaches, relation of, to storms, 71
Noble, Charles P., exhibition of specimen of abdominal pregnancy removed at the end of twenty-one months by cœliotomy, 19

OCULAR complications of variola, 34
Omentum, volvulus of, 95
Ophthalmology, section on, 183
Osteoplastic trephine, a new, 21
Otology and laryngology, section on, 185

PACKARD, FRANCIS R., memoir of Charles Henry Burnett, xliii
Pearce, F. Savary, the blood in epilepsy, 164
Pfahler, G. E., tortuosity of the aorta, 24

SAILER, JOSEPH, tortuosity of the aorta, 24
Sand, intestinal, 162
Sarcoma of the abdominal wall and probably of the pelvic viscera, 158
Seborrhœa nigricans, 154
Serositis, multiple, 55
Shoemaker, George Erety, intestinal sand, 153
  sarcoma of the abdominal wall and probably of the pelvic viscera, 158
Skull, fracture of base of, 40
Spiller, W. G., a case of intradural spinal cyst, 1
  a physiological, anatomical, and pathological study of the glossopharyngeus and vagus nerves in a case of fracture of the base of the skull, 40
  tumor of brain, 107
Spinal cyst, intradural, 1
Stewart, Francis T., volvulus of the omentum, 95
Suturing the omentum to the abdominal wall for the relief of ascites due to cirrhosis of the liver, 62, 67
Swan, John M., mercurial nephritis, 77, 89

TALMA operation for relief of ascites due to cirrhosis of liver, 62, 67
Taylor, William J., case of tumor of brain, 100, 106
Tortuosity of the aorta, 24
Trephine, osteoplastic, 21
Tumor of brain, 100, 107

UNILATERAL pulsating exophthalmos, case of, 162

Van Harlingen, Arthur, case of seborrhœa nigricans, 154
Variola, ocular complications of, 34
Volvulus of omentum, 95

Washington, General, medical treatment of, 99
Willson, Robert N., mercurial nephritis, 89

X-rays, influence of, on malignant growths, 158